



National
Comprehensive
Cancer
Network®

NCCN Clinical Practice Guidelines in Oncology (NCCN Guidelines®)

Penile Cancer

Version 1.2014

NCCN.org

Continue



National
Comprehensive
Cancer
Network®

NCCN Guidelines Version 1.2014 Panel Members

Penile Cancer

[NCCN Guidelines Index](#)
[Penile Cancer TOC](#)
[Discussion](#)

* Peter E. Clark, MD [⊖] Chair
Vanderbilt-Ingram Cancer Center

* Philippe E. Spiess, MD, MS [⊖] Vice chair
Moffitt Cancer Center

Neeraj Agarwal, MD ‡
Huntsman Cancer Institute
at the University of Utah

Matthew C. Biagioli, MD, MS §
Moffitt Cancer Center

Mario A. Eisenberger, MD † [⊖]
The Sidney Kimmel Comprehensive
Cancer Center at Johns Hopkins

Richard E. Greenberg, MD [⊖]
Fox Chase Cancer Center

Harry W. Herr, MD [⊖]
Memorial Sloan-Kettering Cancer Center

* Brant A. Inman, MD, MSc [⊖]
Duke Cancer Institute

A. Karim Kader, MD, PhD [⊖]
UC San Diego Moores Cancer Center

Deborah A. Kuban, MD §
The University of Texas
MD Anderson Cancer Center

Timothy M. Kuzel, MD ‡
Robert H. Lurie Comprehensive Cancer Center
of Northwestern University

Subodh M. Lele, MD ≠
Fred & Pamela Buffett Cancer Center at
The Nebraska Medical Center

Jeff Michalski, MD, MBA §
Siteman Cancer Center at Barnes-
Jewish Hospital and Washington
University School of Medicine

Jeffrey S. Montgomery, MD, MHSA [⊖]
University of Michigan
Comprehensive Cancer Center

Lance C. Pagliaro, MD †
The University of Texas
MD Anderson Cancer Center

Sumanta K. Pal, MD †
City of Hope Comprehensive Cancer Center

Anthony Patterson, MD [⊖]
St. Jude Children's Research Hospital/
University of Tennessee Health Science Center

Elizabeth R. Plimack, MD, MS †
Fox Chase Cancer Center

Kamal S. Pohar, MD [⊖]
The Ohio State University Comprehensive
Cancer Center - James Cancer Hospital
and Solove Research Institute

Michael P. Porter, MD, MS [⊖]
Fred Hutchinson Cancer Research Center/
Seattle Cancer Care Alliance

Jerome P. Richie, MD [⊖]
Dana-Farber/Brigham and Women's
Cancer Center

Wade J. Sexton, MD [⊖]
Moffitt Cancer Center

William U. Shipley, MD § [⊖]
Massachusetts General Hospital Cancer Center

Eric J. Small, MD † [⊖]
UCSF Helen Diller Family
Comprehensive Cancer Center

Guru Sonpavde, MD †
University of Alabama at Birmingham
Comprehensive Cancer Center

Donald L. Trump, MD †
Roswell Park Cancer Institute

Jonathan Tward, MD, PhD §
Huntsman Cancer Institute
at the University of Utah

Geoffrey Wile, MD [⊖]
Vanderbilt-Ingram Cancer Center

Timothy G. Wilson, MD [⊖]
City of Hope Comprehensive Cancer Center

NCCN
Mary Dwyer, MS
Maria Ho, PhD

[⊖] Urology
[†] Medical oncology
[‡] Hematology/Hematology oncology
[§] Radiotherapy/Radiation oncology
[⊕] Diagnostic radiology
[≠] Pathology
* Writing committee member

Continue

[NCCN Guidelines Panel Disclosures](#)



[NCCN Penile Cancer Panel Members](#)
[Summary of the Guidelines Updates](#)

[Primary Evaluation, Clinical Diagnosis \(PN-1\)](#)

[Primary Treatment Tis, Ta \(PN-1\)](#)

[Primary Treatment T1, T2 or Greater \(PN-2\)](#)

[Management of Non-Palpable Inguinal Lymph Nodes \(PN-3\)](#)

[Management of Palpable Inguinal Lymph Nodes \(PN-4\)](#)

[Management of Bulky/Unresectable Inguinal Lymph Nodes \(PN-5\)](#)

[Surveillance \(PN-6\)](#)

[Management of Recurrent Disease \(PN-7\)](#)

[Management of Metastatic Disease \(PN-8\)](#)

[Principles of Surgery \(PN-A\)](#)

[Principles of Radiotherapy \(PN-B\)](#)

[Principles of Chemotherapy \(PN-C\)](#)

Clinical Trials: NCCN believes that the best management for any cancer patient is in a clinical trial. Participation in clinical trials is especially encouraged.

To find clinical trials online at NCCN member institutions, [click here: nccn.org/clinical_trials/physician.html](#).

NCCN Categories of Evidence and Consensus: All recommendations are Category 2A unless otherwise specified.

See [NCCN Categories of Evidence and Consensus](#).

[Staging \(ST-1\)](#)

The NCCN Guidelines® are a statement of evidence and consensus of the authors regarding their views of currently accepted approaches to treatment. Any clinician seeking to apply or consult the NCCN Guidelines is expected to use independent medical judgment in the context of individual clinical circumstances to determine any patient's care or treatment. The National Comprehensive Cancer Network® (NCCN®) makes no representations or warranties of any kind regarding their content, use or application and disclaims any responsibility for their application or use in any way. The NCCN Guidelines are copyrighted by National Comprehensive Cancer Network®. All rights reserved. The NCCN Guidelines and the illustrations herein may not be reproduced in any form without the express written permission of NCCN. ©2013.



Summary of the changes in the 1.2014 version of the Guidelines for Penile Cancer from the 1.2013 version include:

PN-1

- **Primary evaluation**
 - ▶ **Imaging by MRI or ultrasound and corresponding footnote “MRI or ultrasound are optional studies based on clinical suspicion and to further define concerning physical exam findings” were removed.**
- **Pathologic diagnosis heading was changed to “Clinical Diagnosis.”**

PN-2

- **T2 or greater**
 - ▶ **The primary treatment for T2 tumors only was revised from “Radiotherapy ± concurrent chemotherapy (category 2B)” to “Radiotherapy (category 2B) or Radiotherapy with concurrent chemotherapy (category 3).”**

PN-3

- **Low risk, “T1G1” was clarified as “T1a”**
- **“Intermediate risk” was combined with “High risk”**
 - ▶ **Intermediate risk, “T1G2” was clarified as “T1b”**
 - ▶ **High risk, “G4” was added.**

PN-4

- **Unilateral lymph node <4 cm was separated into “Low-risk primary lesion” and “High-risk primary lesion.”**
 - ▶ **For a low-risk primary lesion, an FNA is recommended. If negative, “surveillance” was added as an option with excisional biopsy.**
 - ▶ **For high-risk primary lesion, the treatment recommendation is ILND.**
- **Footnotes were removed and applied within the algorithm:**
 - ▶ **For a high-risk primary lesion, it is recommended to proceed directly to ILND and not FNA.**
 - ▶ **Surveillance can be considered in patients with a negative FNA provided they are carefully surveyed. See Surveillance (PN-6).**
- **Footnote “o” was added: “High-risk primary lesion: T1, high-grade, LVI, >50% poorly undifferentiated.”**

PN-5

- **“Management of Bulky/Unresectable Inguinal Lymph Nodes” page was extensively revised.**
- **Footnote “q” was added: “For viable disease post-chemotherapy, consider PLND.”**

Principles of Surgery

PN-A

- **1st bullet was modified by clarifying that laser therapy and glansctomy are category 2B recommendations.**
- **3rd bullet, 2nd sub-bullet was revised by adding “≥” to “pT1G3.”**
- **Footnotes “1” was added: “See Discussion for further details regarding ILND and PLND.”**

Principles of Radiotherapy

PN-B

- **For T1-2, N0, if tumor <4 cm:**
 - ▶ **1st sub-bullet, “preferred approach” was added to “Brachytherapy alone.”**
 - ▶ **2nd sub-bullet was modified by adding: “EBRT with or without chemotherapy: Total dose 65-70 Gy *with conventional fractionation using appropriate bolus* to primary penile lesion with 2 cm margins” and removing the statement “Consider prophylactic inguinal lymph node irradiation.”**
- **For T3-4 or N+, “surgically unresectable” was added for clarification.**
- **Footnotes 1 through 3 were added.**

Principles of Chemotherapy

PN-C 1 of 2

- **Second-line therapy, 2nd bullet:**
 - ▶ **“irinotecan” was removed.**
 - ▶ **“Strongly consider a clinical trial” was added.**

PN-C 2 of 2

- **Radiosensitizing agents and combinations (For radiotherapy with concurrent chemotherapy) was separated into “preferred” and “alternate options.”**
 - ▶ **Preferred**
 - ◊ **Cisplatin alone, or in combination with 5-FU**
 - ▶ **Alternate options**
 - ◊ **Mitomycin C in combination with 5-FU**
 - ◊ **Capecitabine**



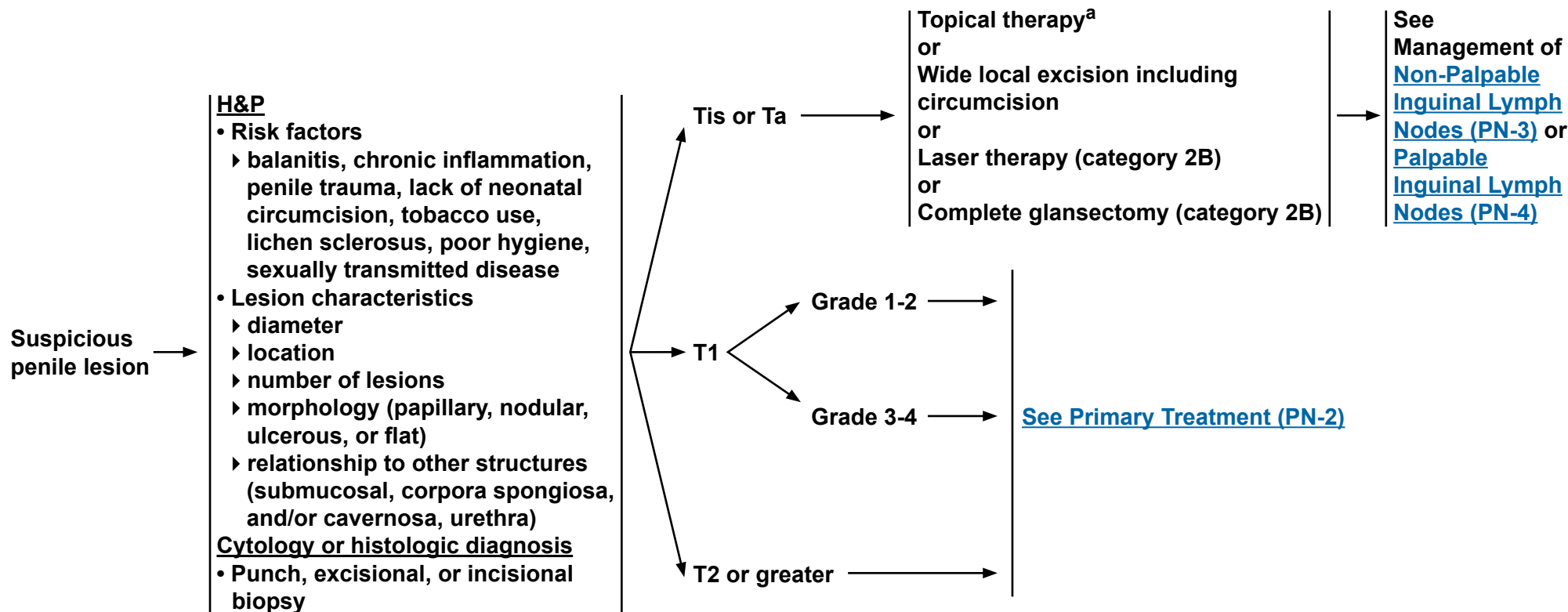
NCCN Guidelines Version 1.2014

Penile Cancer

PRIMARY EVALUATION

CLINICAL DIAGNOSIS

PRIMARY TREATMENT



If recurrent disease, [see PN-7](#) or if metastatic disease, [see PN-8](#)

^aTopical therapy may include topical imiquimod (5%) or 5-fluorouracil (5-FU) cream.

Note: All recommendations are category 2A unless otherwise indicated.
Clinical Trials: NCCN believes that the best management of any cancer patient is in a clinical trial. Participation in clinical trials is especially encouraged.

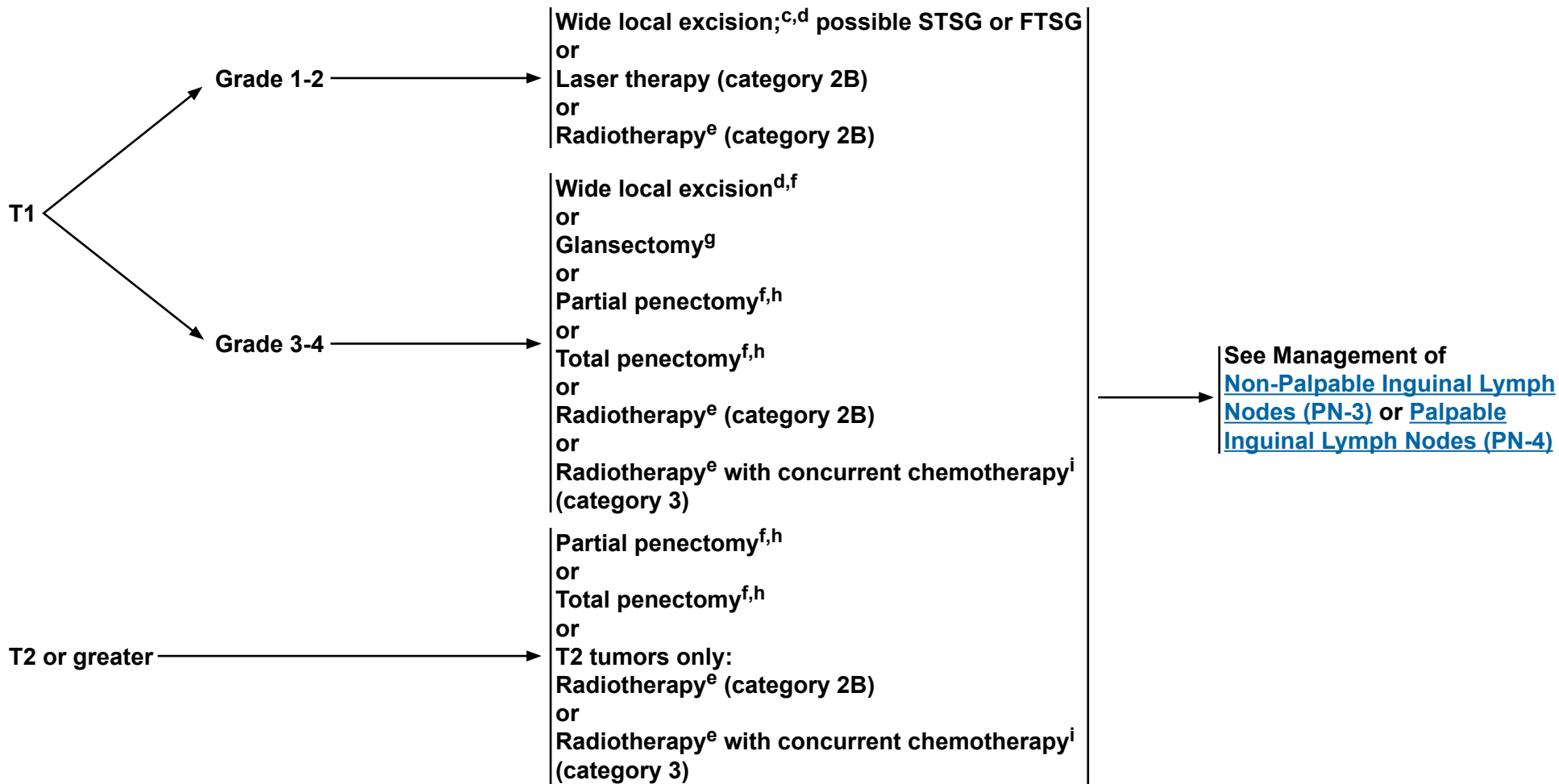


NCCN Guidelines Version 1.2014

Penile Cancer

PATHOLOGIC DIAGNOSIS

PRIMARY TREATMENT^b



^bSee [Principles of Surgery \(PN-A\)](#).

^cMoh's surgery is an option.

^dComplete excision of the skin with a wide negative margin with skin grafting is needed. STSG = split-thickness skin graft; FTSG= full-thickness skin graft.

^eSee [Principles of Radiotherapy \(PN-B\)](#).

^fRecommend intraoperative frozen sections to achieve negative margins.

^gAppropriate with proven negative margins for tumors involving the glans only.

^hWhen it is necessary to dissect into the corpora cavernosum to achieve a negative margin, a partial or total penectomy is performed.


ⁱSee [Principles of Chemotherapy \(PN-C\)](#).

Note: All recommendations are category 2A unless otherwise indicated.

Clinical Trials: NCCN believes that the best management of any cancer patient is in a clinical trial. Participation in clinical trials is especially encouraged.



MANAGEMENT OF NON-PALPABLE INGUINAL LYMPH NODES



^jTa verrucous carcinoma is by definition a well-differentiated tumor and would require surveillance alone of inguinal lymph nodes.

^kDSNB is recommended provided the treating physician has experience with this modality.

^lIf positive lymph nodes are found on DSNB, ILND is recommended.

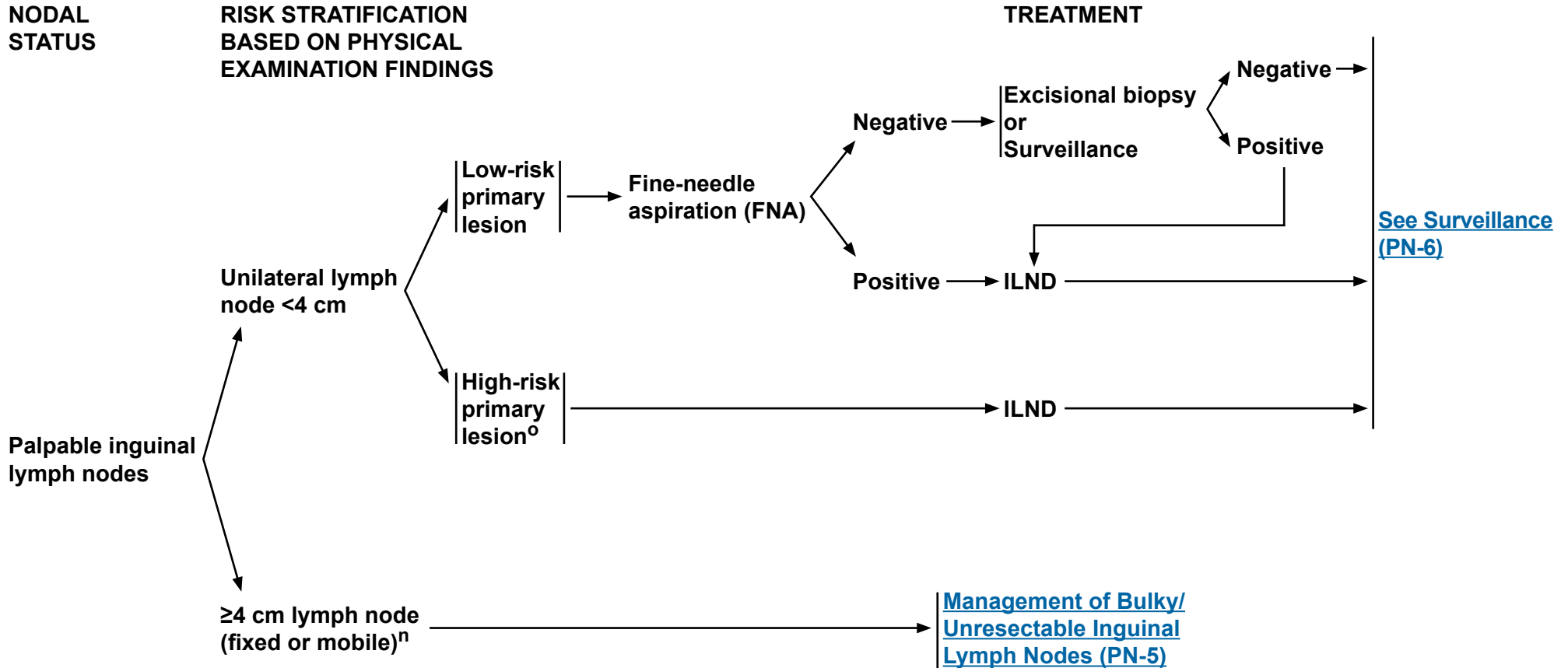
^mA modified/superficial inguinal dissection with intraoperative frozen section is an acceptable alternative to stage the inguinal lymph nodes.

Note: All recommendations are category 2A unless otherwise indicated.

Clinical Trials: NCCN believes that the best management of any cancer patient is in a clinical trial. Participation in clinical trials is especially encouraged.



MANAGEMENT OF PALPABLE INGUINAL LYMPH NODES



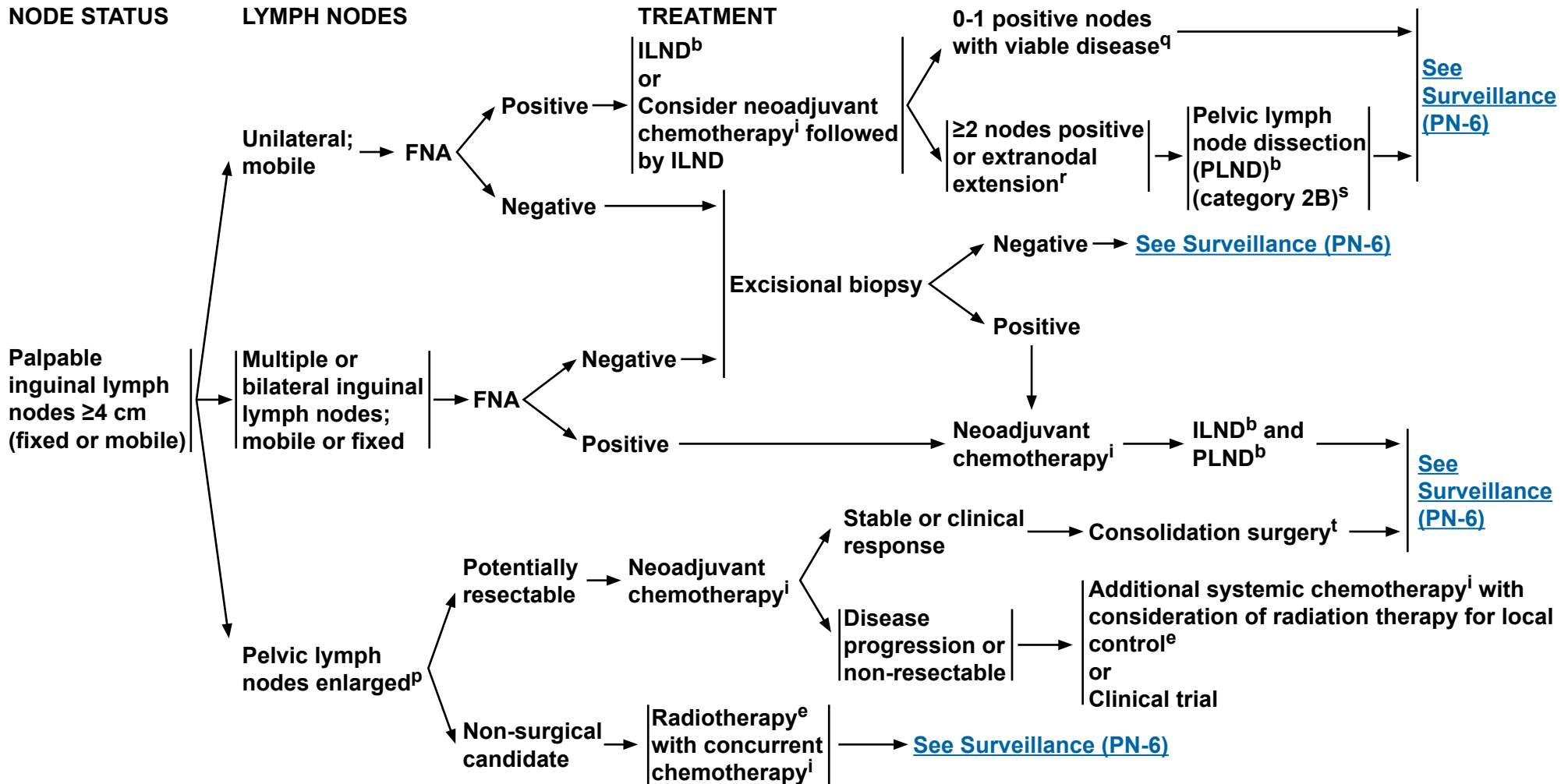
ⁿImaging to assess regional nodes and distant metastases.

^oHigh-risk primary lesion: T1, high-grade, LVI, >50% poorly undifferentiated.

Note: All recommendations are category 2A unless otherwise indicated.
Clinical Trials: NCCN believes that the best management of any cancer patient is in a clinical trial. Participation in clinical trials is especially encouraged.



MANAGEMENT OF BULKY/UNRESECTABLE INGUINAL LYMPH NODES



^bSee Principles of Surgery (PN-A).

^eSee Principles of Radiotherapy (PN-B).

ⁱSee Principles of Chemotherapy (PN-C).

^pOn CT or MRI, not pathologic stage.

^qFor viable disease post-chemotherapy, consider PLND.

^rConsider adjuvant chemotherapy (category 2B).

^sConsider postoperative radiotherapy (category 2B).

^tConsolidation surgery consists of bilateral superficial and deep ILND and possible bilateral PLND.

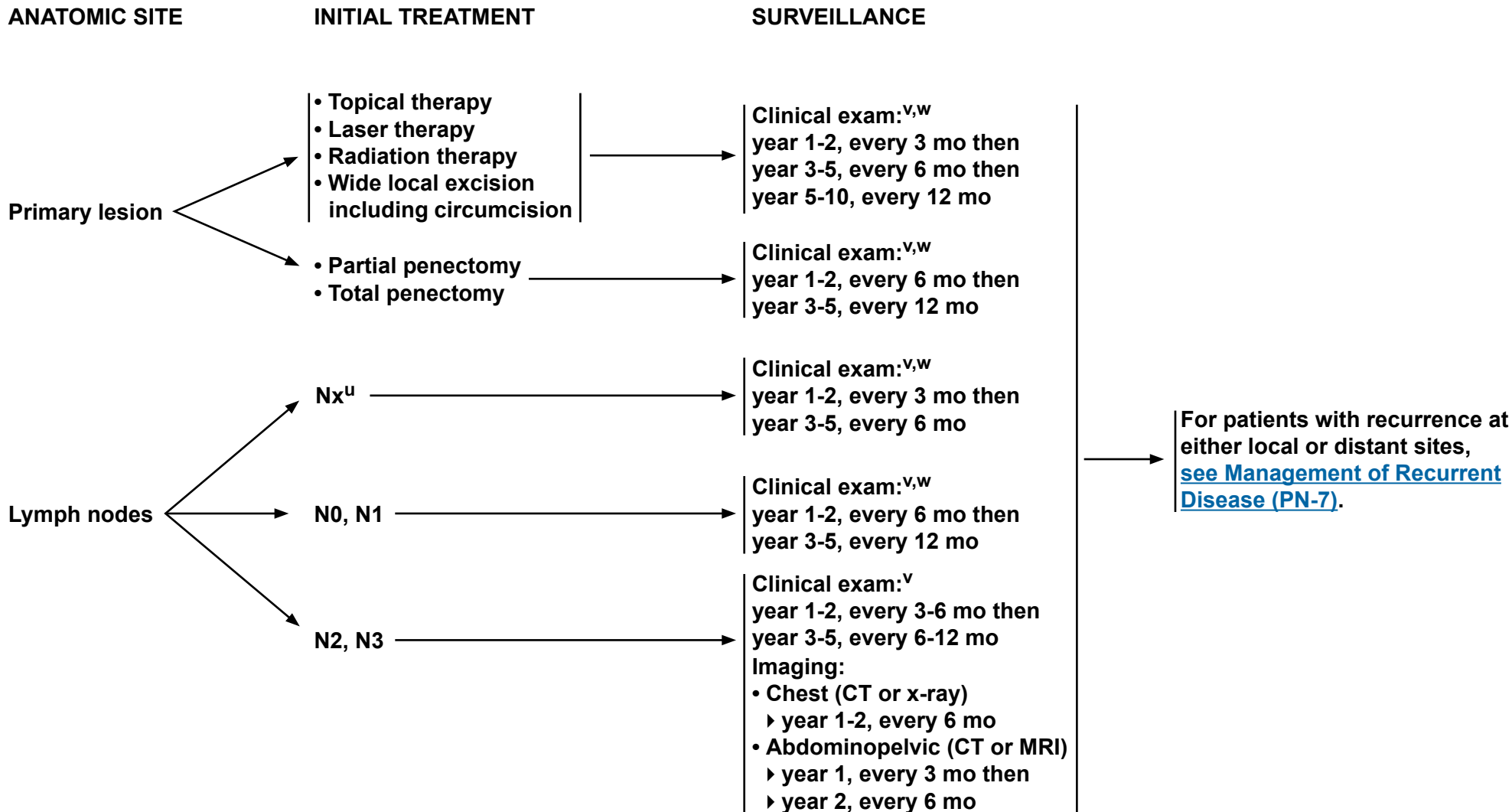
Note: All recommendations are category 2A unless otherwise indicated.

Clinical Trials: NCCN believes that the best management of any cancer patient is in a clinical trial. Participation in clinical trials is especially encouraged.



NCCN Guidelines Version 1.2014

Penile Cancer



^UPatients on active surveillance of clinically negative nodes and at low risk for inguinal metastases.

^VClinical exam includes examination of the penis and inguinal region.

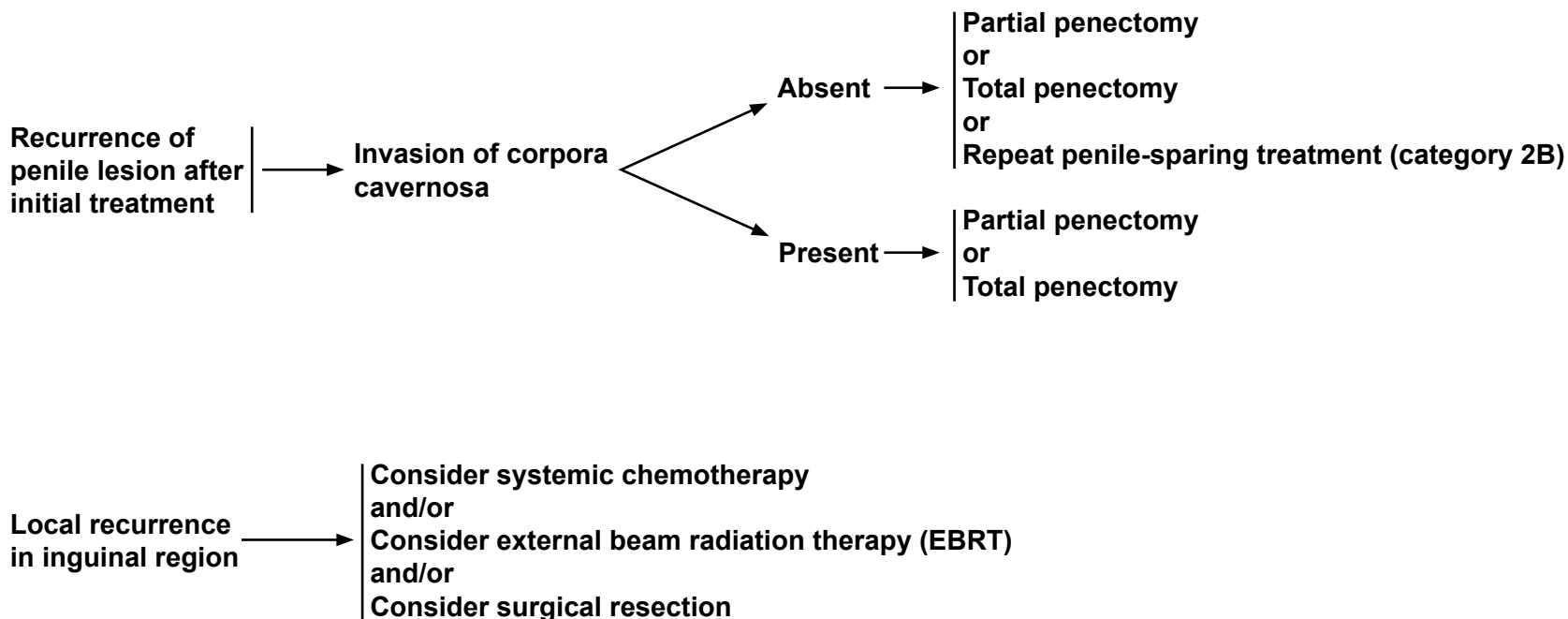
^WIf an abnormal clinical exam, obese patient, or prior inguinal surgery, then ultrasound, CT, or MRI of the inguinal region can be considered.

Note: All recommendations are category 2A unless otherwise indicated.

Clinical Trials: NCCN believes that the best management of any cancer patient is in a clinical trial. Participation in clinical trials is especially encouraged.



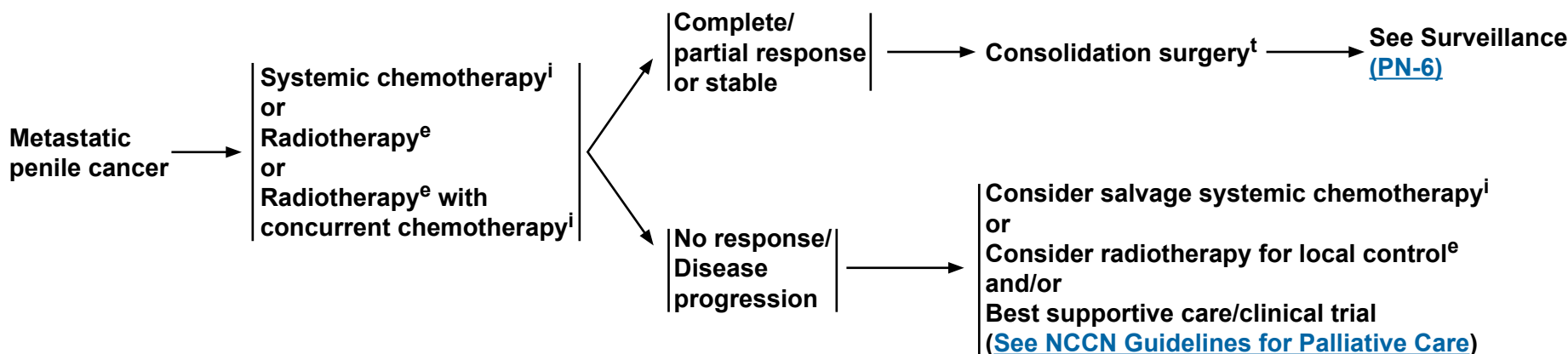
MANAGEMENT OF RECURRENT DISEASE



Note: All recommendations are category 2A unless otherwise indicated.
Clinical Trials: NCCN believes that the best management of any cancer patient is in a clinical trial. Participation in clinical trials is especially encouraged.



MANAGEMENT OF METASTATIC DISEASE



ⁱSee Principles of Chemotherapy (PN-C).

^eSee Principles of Radiotherapy (PN-B).

^tConsolidation surgery consists of bilateral superficial and deep ILND and possible bilateral PLND.

Note: All recommendations are category 2A unless otherwise indicated.

Clinical Trials: NCCN believes that the best management of any cancer patient is in a clinical trial. Participation in clinical trials is especially encouraged.



PRINCIPLES OF SURGERY¹

- **Tis, Ta penile cancer lesions may be amenable to conservative penile organ-sparing approaches, including: topical therapy, local excision, circumcision, laser therapy (category 2B), or glansectomy (category 2B).**
- **Partial penectomy should be considered the standard for high-grade primary penile tumors, provided a functional penile stump can be preserved and negative margins are obtained.**
- **Standard or modified ILND or DSNB (category 2B) is indicated in patients with penile cancer in the absence of palpable inguinal adenopathy if high-risk features for nodal metastasis are seen in the primary penile tumor:**
 - ▶ **Lymphovascular invasion**
 - ▶ **≥pT1G3 or ≥T2, any grade**
 - ▶ **>50% poorly differentiated**
- **PLND should be considered at the time of ILND in patients with ≥2 inguinal nodes (on frozen section) on the ipsilateral ILND site or in a delayed procedure in patients with extranodal extension.**

¹See Discussion for further details regarding ILND and PLND.

Note: All recommendations are category 2A unless otherwise indicated.
Clinical Trials: NCCN believes that the best management of any cancer patient is in a clinical trial. Participation in clinical trials is especially encouraged.



PRINCIPLES OF RADIOTHERAPY

Primary Radiation Therapy (category 2B) (Penile Preservation)

T1-2, N0

If tumor <4 cm

• Circumcision followed by either:

- ▶ Brachytherapy alone (preferred approach)^{1,2} (should be performed with interstitial implant);
or
- ▶ EBRT with or without chemotherapy:³ Total dose 65-70 Gy with conventional fractionation using appropriate bolus to primary penile lesion with 2 cm margins.

If tumor ≥4 cm

• Circumcision followed by either:

- ▶ EBRT with chemotherapy:³ 45-50.4 Gy to a portion of or whole penile shaft depending upon bulk and extent of lesion plus pelvis/inguinal nodes, then boost primary lesion with 2 cm margins EBRT (total dose 60-70 Gy);
or
- ▶ Brachytherapy (in select cases and with careful post-treatment surveillance)

T3-4 or N+ (surgically unresectable)

• Circumcision followed by:

- ▶ EBRT with chemotherapy:³ 45-50.4 Gy to whole penile shaft, pelvic lymph nodes, and bilateral inguinal lymph nodes, then boost primary lesion with 2 cm margins and gross lymph nodes (total dose 60-70 Gy).

Postoperative Adjuvant Radiotherapy

• Inguinal Lymph Node Positive (category 2B)

- ▶ Inguinal and pelvic lymph node EBRT to 45-50.4 Gy (strongly consider concomitant chemotherapy³).
- ▶ Boost gross nodes and areas of extracapsular extension to a total dose of 60-70 Gy.
- ▶ Treat primary site of disease if positive margin.

• Primary Site Margin Positive

- ▶ Primary site of disease and surgical scar EBRT to 60-70 Gy (for close margin consider radiation treatment vs. observation).
- ▶ Treat bilateral inguinal lymph nodes and pelvic lymph nodes if no or inadequate lymph node dissection.
- ▶ Brachytherapy (in select cases)

¹Crook J, Ma C, Grimard L. World J Urol 2009;27:189-196.

²de Crevoisier R, Slimane K, Sanfilippo N, et al. Int J Radiat Oncol Biol Phys 2009;74:1150-1156.

³For potential radiosensitizing agents and combinations, see [Principles of Chemotherapy \(PN-C 2 of 2\)](#).

Note: All recommendations are category 2A unless otherwise indicated.

Clinical Trials: NCCN believes that the best management of any cancer patient is in a clinical trial. Participation in clinical trials is especially encouraged.

**PRINCIPLES OF CHEMOTHERAPY****Neoadjuvant**

- **Neoadjuvant, cisplatin-based chemotherapy should be considered the standard (prior to ILND) in patients with ≥ 4 cm inguinal lymph nodes (fixed or mobile), if FNA is positive for metastatic penile cancer.¹**
 - ▶ Patients with initially unresectable (T4) primary tumors may be downstaged by response to chemotherapy.
- **A Tx, N2-3, M0 penile cancer can receive 4 courses of neoadjuvant paclitaxel, ifosfamide, and cisplatin (TIP).² Stable or responding patients should then undergo consolidative surgery with curative intent.**
 - ▶ The phase II response rate was 50% in the neoadjuvant setting.
 - ▶ The estimated rate of long-term progression-free survival for intent to treat was 36.7%.
 - ▶ Improved progression-free and overall survival times were associated with objective response to chemotherapy.

Adjuvant

- **There are no sufficient data to form conclusions about the use of adjuvant chemotherapy. By extrapolation from the neoadjuvant data, it is reasonable to give 4 courses of TIP in the adjuvant setting if it was not given preoperatively and the pathology shows high-risk features. ([See Management of Bulky/Unresectable Inguinal Lymph Nodes, PN-5](#)) For high-risk patients, for whom adjuvant EBRT or chemoradiotherapy can also be considered, include those with any of the following:**
 - ▶ Pelvic lymph node metastases
 - ▶ Extranodal extension
 - ▶ Bilateral inguinal lymph nodes involved
 - ▶ 4 cm tumor in lymph nodes

Metastatic

- **TIP is a reasonable first-line treatment for patients with metastatic penile cancer, including palliative treatment of patients with distant metastases.²**
- **5-FU + cisplatin has been used historically for metastatic penile cancer and can be considered as an alternative to TIP.³ It appears to be effective for some patients, although the toxicities may be limiting and require dose reductions.⁴**
- **Bleomycin-containing regimens are associated with unacceptable toxicity⁵ and are no longer recommended.**
- **There are no randomized clinical trials due to the rarity of penile cancer in industrialized countries.**

Second-line

- **No standard second-line systemic therapy exists.**
- **Depending on first-line therapies, palliative options include single-agent therapy such as capecitabine, carboplatin, docetaxel, 5-FU, methotrexate, paclitaxel, and panitumumab.^{4,6-10} Strongly consider a clinical trial.**

[Continued on PN-C 2 of 2](#)[References on PN-C 2 of 2](#)**Note: All recommendations are category 2A unless otherwise indicated.****Clinical Trials: NCCN believes that the best management of any cancer patient is in a clinical trial. Participation in clinical trials is especially encouraged.**



PRINCIPLES OF CHEMOTHERAPY

Preferred combination chemotherapy regimens

TIP²

Paclitaxel 175 mg/m² IV over 3 hours on Day 1
Ifosfamide 1200 mg/m² IV over 2 hours on Days 1-3
Cisplatin 25 mg/m² IV over 2 hours on Days 1-3
Repeat every 21 days

5-FU + cisplatin⁴ (category 2B)

Continuous infusion 5-FU 1000 mg/m²/d IV on Days 1-5
Cisplatin 100 mg/m² IV on Day 1
Repeat every 3 to 4 weeks

Radiosensitizing agents and combinations¹¹ (For radiotherapy with concurrent chemotherapy)

• Preferred

▶ **Cisplatin alone, or in combination with 5-FU**

• Alternate options

▶ **Mitomycin C in combination with 5-FU**
▶ **Capecitabine**

References

1. Pettaway CA, Pagliaro L, Theodore C, Haas G. Treatment of visceral, unresectable, or bulky/unresectable regional metastases of penile cancer. *Urology* 2010;76:S58-65.
2. Pagliaro LC, Williams DL, Daliani D, et al. Neoadjuvant paclitaxel, ifosfamide, and cisplatin chemotherapy for metastatic penile cancer: a phase II study. *J Clin Oncol* 2010;28:3851-3857.
3. Pizzocaro G, Algaba F, Horenblas S, et al. EAU penile cancer guidelines 2009. *Eur Urol* 2010;57:1002-1012.
4. Shamma FV, Ous S, Fossa SD. Cisplatin and 5-fluorouracil in advanced cancer of the penis. *J Urol* 1992;147:630-632.
5. Haas GP, Blumenstein BA, Gagliano RG, et al. Cisplatin, methotrexate and bleomycin for the treatment of carcinoma of the penis: a Southwest Oncology Group study. *J Urol* 1999;161:1823-1825.
6. Pizzocaro G, Nicolai N, Milani A. Taxanes in combination with cisplatin and fluorouracil for advanced penile cancer: preliminary results. *Eur Urol* 2009;55:546-551.
7. Theodore C, Skoneczna I, Bodrogi I, et al. A phase II multicentre study of irinotecan (CPT 11) in combination with cisplatin (CDDP) in metastatic or locally advanced penile carcinoma (EORTC PROTOCOL 30992). *Ann Oncol* 2008;19:1304-1307.
8. Ahmed T, Sklaroff R, Yagoda A. Sequential trials of methotrexate, cisplatin and bleomycin for penile cancer. *J Urol* 1984;132:465-468.
9. Di Lorenzo G, Federico P, Buonerba C, et al. Paclitaxel in pretreated metastatic penile cancer: final results of a phase 2 study. *Eur Urol* 2011;60:1280-1284.
10. Necchi A, Nicolai N, Colecchia M, et al. Proof of activity of anti-epidermal growth factor receptor-targeted therapy for relapsed squamous cell carcinoma of the penis. *J Clin Oncol* 2011;29:e650-652.
11. Pagliaro LC, Crook J. Multimodality therapy in penile cancer: when and which treatments? *World J Urol* 2009;27:221-225.

Note: All recommendations are category 2A unless otherwise indicated.

Clinical Trials: NCCN believes that the best management of any cancer patient is in a clinical trial. Participation in clinical trials is especially encouraged.

**Table 1**
**American Joint Committee on Cancer (AJCC)
TNM Staging System for Penile Cancer (7th ed., 2010)**
Primary Tumor (T)

TX	Primary tumor cannot be assessed
T0	No evidence of primary tumor
Ta	Noninvasive verrucous carcinoma*
Tis	Carcinoma in situ
T1a	Tumor invades subepithelial connective tissue without lymph vascular invasion and is not poorly differentiated (i.e., grade 3-4)
T1b	Tumor invades subepithelial connective tissue with lymph vascular invasion or is poorly differentiated
T2	Tumor invades corpus spongiosum or cavernosum
T3	Tumor invades urethra
T4	Tumor invades other adjacent structures

*Note: Broad pushing penetration (invasion) is permitted; destructive invasion is against the diagnosis

Regional Lymph Nodes (N)

Clinical Stage Definition*

cNX	Regional lymph nodes cannot be assessed
cN0	No lymph node metastasis
cN1	Palpable mobile unilateral inguinal lymph node
cN2	Palpable mobile multiple or bilateral inguinal lymph nodes
cN3	Palpable fixed inguinal nodal mass or pelvic lymphadenopathy unilateral or bilateral

Pathologic Stage Definition*

pNX	Regional lymph nodes cannot be assessed
pN0	No regional lymph node metastasis
pN1	Metastasis in a single inguinal node
pN2	Metastasis in multiple or bilateral inguinal lymph nodes
pN3	Extranodal extension of lymph node metastasis or pelvic lymph node(s) unilateral or bilateral

*Note: Pathologic stage definition based on biopsy or surgical excision.

Distant Metastasis (M)

M0	No distant metastasis
M1	Distant metastasis

Used with the permission of the American Joint Committee on Cancer (AJCC), Chicago, Illinois. The original and primary source for this information is the AJCC Cancer Staging Manual, Seventh Edition (2010) published by Springer Science+Business Media, LLC (SBM). (For complete information and data supporting the staging tables, visit www.springer.com.) Any citation or quotation of this material must be credited to the AJCC as its primary source. The inclusion of this information herein does not authorize any reuse or further distribution without the expressed, written permission of Springer SBM, on behalf of the AJCC.

ANATOMIC STAGE/PROGNOSTIC GROUPS

Stage 0	Tis	N0	M0
	Ta	N0	M0
Stage I	T1a	N0	M0
Stage II	T1b	N0	M0
	T2	N0	M0
	T3	N0	M0
Stage IIIA	T1-3	N1	M0
Stage IIIB	T1-3	N2	M0
Stage IV	T4	Any N	M0
	Any T	N3	M0
	Any T	Any N	M1



Discussion

NCCN Categories of Evidence and Consensus

Category 1: Based upon high-level evidence, there is uniform NCCN consensus that the intervention is appropriate.

Category 2A: Based upon lower-level evidence, there is uniform NCCN consensus that the intervention is appropriate.

Category 2B: Based upon lower-level evidence, there is NCCN consensus that the intervention is appropriate.

Category 3: Based upon any level of evidence, there is major NCCN disagreement that the intervention is appropriate.

All recommendations are category 2A unless otherwise noted.

Table of Contents

Overview	MS-2
Risk Factors	MS-2
Clinical Presentation	MS-2
Characterization and Clinical Staging	MS-2
Management of Primary Lesions	MS-3
Diagnosis	MS-3
NCCN Recommendations	MS-3
Tis or Ta	MS-3
T1G1-2	MS-4

T1G3-4 or T≥2	MS-4
---------------------	------

Management of Regional Lymph NodesMS-4

Evaluation and Risk Stratification	MS-4
Dynamic Sentinel Node Biopsy	MS-5
Inguinal Lymph Node Dissection	MS-6
Modified Template Lymphadenectomy	MS-6
Delayed Inguinal Lymphadenectomy.....	MS-7
Unilateral Versus Bilateral Lymphadenectomy	MS-7
Pelvic Lymphadenectomy.....	MS-7
Chemotherapy.....	MS-8
NCCN Recommendations	MS-8
Non-Palpable Nodes.....	MS-8
Unilateral Palpable Nodes <4 cm.....	MS-8
Palpable Nodes ≥4 cm (fixed or mobile)	MS-8

SurveillanceMS-9

Recurrence.....MS-9

Metastatic Disease.....MS-9

SummaryMS-10

ReferencesMS-11



Overview

Squamous cell carcinoma (SCC) of the penis is a rare disease, representing 0.4% to 0.6% of all malignant neoplasms among men in the United States and Europe.¹ In 2012, the estimated number of new cases of penile cancer in the United States was 1,570, with 310 predicted cancer-specific deaths.² Incidence is higher (up to 10%) among men in the developing countries of Asia, Africa, and South America. The most common age of presentation is between ages 50 and 70.³ Early diagnosis is of utmost importance, as this is a disease that can result in devastating disfigurement and has a 5-year survival rate of approximately 50% (over 85% for patients with negative lymph nodes and 29%–40% for patients with positive nodes, with the lowest survival rates at 0% for patients with pelvic lymph node [PLN] involvement).⁴ As the rarity of this disease makes it difficult to perform prospective, randomized trials, the NCCN Panel relied on the experience of penile cancer experts to minimize the controversies associated with treating penile SCC and collectively lay down a foundation to help standardize the management of the malignancy.

Risk Factors

In the United States the median age of diagnosis is 68 years, with an increase in risk for males older than 50 years.⁵ Early detection is assisted by the ability to do a good physical exam. Phimosis may hinder the capability to properly inspect the areas of highest incidence—the glans, inner preputial layer, coronal sulcus, and shaft. Men with phimosis carry an increased risk of 25% to 60%.^{3,6,7} A more recent review of penile SCC in the United States showed that 34.5% of patients had the primary lesion on the glans, 13.2% on the prepuce, and 5.3% in the shaft, with 4.5% overlapping and 42.5% unspecified.⁵ Other risk factors include balanitis, chronic inflammation, penile trauma, tobacco use, lichen sclerosus, poor hygiene, and a history of sexually

transmitted disease(s), especially HIV and HPV.³ Overall, about 45% to 80% of penile cancers are related to HPV, with a strong correlation with types 16 and 18.^{3,6,8,9} There is an 8-fold increased risk for patients with HIV, which may correspond to a higher incidence in HPV among males with HIV.¹⁰ Cigarette smokers are noted to be 3 to 4.5 times more likely to develop penile cancer.^{8,11} Patients with lichen sclerosus are noted to have a 2% to 9% risk of developing penile carcinoma.¹²⁻¹⁴ Psoriasis patients undergoing psoralen plus ultraviolet A (PUVA) treatment have an increased incidence of 286 times compared to the general population. Therefore, they should be shielded during treatment and any penile lesion should be closely monitored.¹⁵

Clinical Presentation

Most often penile SCC presents as a palpable, visible lesion on the penis, which may be associated with penile pain, discharge, bleeding, or a foul odor if the patient delays seeking medical treatment. The lesion may be characterized as nodular, ulcerative, or fungating, and may be obscured by phimosis. The patient may exhibit signs of more advanced disease, including palpable nodes and/or constitutional symptoms (eg, fatigue, weight loss).

Characterization and Clinical Staging

SCC is the most common variant of penile cancer. Penile intraepithelial neoplasia (PIN) is a premalignant condition at high risk of developing into SCC of the penis.¹⁶ The AJCC recognizes four subtypes of SCC: verrucous, papillary squamous, warty, and basaloid.¹⁷ The verrucous subtype is felt to be of low malignant potential, while other variants reported—adenosquamous and sarcomatoid variants—carry a worse prognosis.^{18,19} The primary lesion is further characterized by its growth pattern with superficial spread, nodular or vertical-phase growth, and verrucous pattern. In addition to the penile lesion, evaluation of lymph



nodes is also critical, as involvement of the inguinal lymph nodes (ILNs), the number and site of positive nodes, and extracapsular nodal involvement provide the strongest prognostic factors of survival.^{4,20}

The AJCC Tumor, Nodes, and Metastasis (TNM) system for penile carcinoma has been used for staging, with the most recent update published in 2010. It was initially introduced in 1968 and was subsequently revised in 1978, 1987, and 2002.^{17,21-24} In the 2010 update, the AJCC has made the distinction between clinical and pathologic staging while eliminating the difference between superficial and deep inguinal metastatic nodes.¹⁷ Other changes to the 2010 TNM system include: T1 subdivided into T1a and T1b determined by the presence or absence of lymphovascular invasion or poorly differentiated cancers; the T3 category is now limited to urethral invasion and T4 is limited to prostatic invasion; and stage II grouping includes T1b N0M0 as well as T2-3 N0M0 (see staging tables in the algorithm). A grading system for SCC of the penis based on degree of cell anaplasia is defined as: grade 1, well differentiated (no evidence of anaplasia); grade 2, moderately differentiated (<50% anaplasia); and grade 3, poorly differentiated (>50% anaplastic cells).²⁵ According to the AJCC, if no grading system is specified, a general system should be followed: GX, grade cannot be assessed; G1-3 as previously mentioned above; and G4, undifferentiated.¹⁷ The overall degree of cellular differentiation with high-risk, poorly differentiated tumors is an important predictive factor for metastatic nodal involvement.²⁶ The AJCC also recommends collection of site-specific factors, including: the distinction between corpus spongiosum and corpus cavernosum involvement, the percentage of tumor that is poorly differentiated, the depth of invasion in verrucous carcinoma, the size of the largest lymph node metastasis, and HPV status.¹⁷

Management of Primary Lesions

Diagnosis

Evaluation of the primary lesion, regional lymph nodes, and distant metastasis will dictate the appropriate and adequate management of SCC of the penis, beginning with the first evaluation at presentation and then throughout follow-up. Vital to the initial management is a good physical exam of the penile lesion(s) that remarks on the diameter of the lesion(s) or suspicious areas; location(s) on the penis; number of lesions; morphology of the lesion(s); whether the lesion(s) are papillary, nodular, ulcerous, or flat; and relationship with other structures including submucosal, urethra, corpora spongiosa, and/or corpora cavernosa. To complete the initial evaluation, histologic diagnosis with a punch, excisional, or incisional biopsy is paramount in determining the treatment algorithm based on a pathologic diagnosis.^{17,27} This will provide information on the grade of the tumor, and will assist in the risk stratification of the patient for regional lymph node involvement.²⁷ MRI or ultrasound can be used to evaluate the depth of tumor invasion.²⁸ For the evaluation of lymph nodes, see *Management of Regional Lymph Nodes*.

NCCN Recommendations

Tis or Ta

For patients with penile carcinoma *in situ* or noninvasive verrucous carcinoma, penis-preserving techniques may be utilized, including topical imiquimod (5%) or 5-FU cream, circumcision and wide local excision such as Mohs surgery, laser therapy (category 2B) using carbon dioxide or neodymium:yttrium-aluminum-garnet, and complete glansectomy (category 2B). Among these, topical therapy²⁹⁻³¹ and excisional organ-sparing surgery³² are the most widely used. Retrospective studies of laser therapy reported local recurrence rates of



around 18% comparable to that of surgery, with good cosmetic and functional results.^{33,34} Glansectomy, removal of the glans penis, has also been studied with no recurrence observed in some cases.³⁵⁻³⁸

T1G1-2

Careful consideration should be given to penile-preserving techniques if the patient is reliable with regards to compliance with close follow-up. These techniques include wide local excision as well as Mohs surgery as an option plus reconstructive surgery,³⁹ laser therapy (category 2B),⁴⁰ and radiotherapy delivered as external beam radiation therapy (EBRT) or brachytherapy with interstitial implant (category 2B).⁴¹⁻⁴⁵ Emphasis is placed again on patient selection and close follow-up, as the 2-year recurrence rate may reach up to 50%.⁴⁶ Recent studies have shown that surgical margins of 5 to 10 mm are as safe as 2-cm surgical margins, and 10- to 20-mm margins provide adequate tumor control.⁴⁷ Circumcision should always precede radiation therapy (RT) to prevent radiation-related complications.

T1G3-4 or T2

These lesions typically require more extensive surgical intervention with partial or total penectomy depending on the characteristics of the tumor and depth of invasion.²⁷ Intraoperative frozen sectioning is recommended to achieve negative surgical margins. If the tumor encompasses less than half of the glans and the patient agrees to very close observation, then a more conservative approach such as wide local excision or glansectomy may be considered. The patient should understand that there is an increased risk for recurrence and potential for a repeat wide local excision should a local recurrence be noted, provided there is no invasion of the corpora cavernosa.^{34,38} A clear and frank discussion should be had with the patient that a partial or total penectomy will likely be required should a larger or more invasive lesion be present.

The tumor size is an important factor when choosing RT as treatment. As the average length of the glans is about 4 cm, this serves as a cutpoint to reduce the risk of under-treating cavernosal lesions. In a study of 144 patients with penile cancer restricted to the glans treated by brachytherapy, larger tumors, especially those over 4 cm, are associated with higher risk of recurrence.⁴⁸ A high, 10-year, cancer-specific survival rate of 92% was achieved in this series.

There was nonuniform consensus among NCCN Panelists on the use of RT as primary therapy due to scant data. RT alone is a category 2B recommendation, while RT with concurrent chemotherapy is a category 3 recommendation. RT should be given after circumcision has been performed.

For tumors smaller than 4 cm, brachytherapy with interstitial implant is preferred, but EBRT with or without chemotherapy is a viable option. Consider prophylactic ILN irradiation if selecting EBRT. For tumors 4 cm or larger, EBRT combined with chemotherapy may be used. Brachytherapy may still be appropriate in select cases, but careful monitoring is necessary as the risks of complications and failures increase.⁴⁹ Crook and colleagues reported a 10-year cause-specific survival of 84% in 67 patients with T1-2 (select cases of T3) penile lesions treated with primary brachytherapy.⁴⁵

Post-surgical RT to the primary tumor site may be considered for positive margins.

Management of Regional Lymph Nodes**Evaluation and Risk Stratification**

The presence and extent of regional ILN metastases has been determined to be the single most important prognostic indicator in determining long-term survival in men with invasive penile SCC.²⁰

Evaluation of the groin and pelvis is an essential component of the metastatic workup of a patient. The involvement of the ILN can be clinically evident (ie, palpable versus non-palpable), adding to the difficulty in management. Clinical exam for ILN involvement should attempt to evaluate and assess for palpability, number of inguinal masses, unilateral or bilateral, dimensions, mobility or fixation of nodes or masses, relationship to other structures (eg, skin, Cooper's ligaments), and edema of the penis, scrotum, and/or legs.^{50,51}

Crossover drainage from left to right and vice versa does occur and is reproducible with lymphoscintigraphy.^{4,52} The physical exam should describe the diameter of node(s) or mass(es), unilateral or bilateral localization, number of nodes identified in each inguinal, and the relationship to other structures (eg, skin, Cooper's ligament), with respect to infiltration, perforation, etc. Imaging for palpable disease by CT or MRI may be used to assess the size, extent, location, and structures that are in close proximity to the ILN, as well as the presence of pelvic and retroperitoneal lymph nodes and distant metastasis. CT and MRI are limited in patients with non-palpable disease.^{50,53} While studies have looked at the use of nanoparticle-enhanced MRI, PET/CT, and 18F-fluorodeoxyglucose (FDG) PET/CT, their small sample size requires validation in larger prospective studies.⁵⁴⁻⁵⁷ When considering one imaging modality to evaluate the stage of the primary lesion and lymph node status, MRI appears to be the best choice to enhance the physical exam in patients where the inguinal region is difficult to assess (eg, morbidity, previous chemo/radiotherapy).^{54,58}

Consideration needs to be given to whether or not the primary lesion demonstrated any adverse prognostic factors. If one or more of these high-risk features is present, then pathologic ILN staging must be performed. Up to 25% of patients with non-palpable lymph nodes harbor micrometastases.²⁵ Therefore, several predictive factors have been

evaluated to help predict the presence of occult lymph node metastasis.^{46,59} Slaton et al²⁵ concluded that patients with pathologic stage T2 or greater were at significant risk (42%–80%) of nodal metastases if they exhibited greater than 50% poorly differentiated cancer and/or vascular invasion, and therefore should be recommended to undergo an inguinal lymph node dissection (ILND).^{4,25} These factors can then further define patients into low-, intermediate-, and high-risk groups for lymph node metastasis.^{18,60,61} The European Association of Urology determined risk stratification groups for patients with non-palpable ILNs, and validated this in both uni- and multivariate analyses of prognostic factors. Patients can be stratified based on stage and/or grade into risk groups based on the likelihood of harboring occult node-positive disease, with the low-risk group defined as those patients with Tis, Ta, or T1a, the intermediate group as those with T1b (lymphovascular invasion), and the high-risk group as those with T2 or G3/G4.^{51,60}

Dynamic Sentinel Node Biopsy

The work by Cabanas used lymphangiograms and anatomic dissections to evaluate the sentinel lymph node drainage for penile cancer with non-palpable ILNs.⁶² This technique has been shown to have false-negative rates as high as 25%; therefore, it is no longer recommended.^{51,63} Advancements have been made with the dynamic sentinel node biopsy (DSNB) technique developed for penile cancer by the Netherlands Cancer Institute using lymphoscintigraphy and performed with technetium-99m-labeled nanocolloid and patent blue dye isosulfan blue.^{64,65} Initially, this technique was associated with a low sensitivity and high false-negative rate (16%–43%).⁶⁶⁻⁶⁹ Refinement of the technique to improve the false-negative rate includes serial sectioning and immunohistochemical staining of pathologic specimens, preoperative ultrasonography with and without fine needle aspiration



(FNA) cytology, and exploration of groins in which no sentinel node is visualized on intraoperative assessment, achieving a decrease in false-negative rate from 19% to only 5%.^{64,70} Using FNA with ultrasound can increase the diagnostic yield in metastasis >2 mm in diameter.^{53,71} Crashaw et al⁷² used ultrasound with DSNB and noted improved accuracy in identifying patients with occult lymph node metastases. With modification of the NCI protocol, Hadway et al⁷³ were able to achieve a similar false-negative rate (5%) with an 11-month follow-up. Secondary to the technical challenges associated with DSNB, to be accurately and reliably performed, it is recommended that DSNB be performed at tertiary care referral centers where at least 20 procedures are done per year.^{64,74} It should be noted that DSNB is not recommended in patients with palpable ILNs.⁵⁰

Inguinal Lymph Node Dissection

The most frequent sites of metastasis from penile cancer are the ILNs, typically presenting as palpable inguinal lymphadenopathy. The management of ILNs by ILND has been fraught with great fears of surgical morbidity.^{51,75} Early treatment of lymph node involvement has been shown to have a positive impact on survival, except if the patient has bulky nodal spread or other sites of metastases.^{76,77} Palpable lymphadenopathy at the time of diagnosis does not warrant an immediate ILND. Of the patients with palpable disease, 30% to 50% will be secondary to inflammatory lymph node swelling instead of metastatic disease.⁵⁹ Although the distinction between reactive lymph nodes and metastatic disease has traditionally been done with a 6-week course of antibiotics, FNA is becoming the most favored approach among many penile cancer experts for patients with palpable nodes.^{4,50} In this setting, antibiotics are useful if the patient has a suspected underlying cellulitis at the site of palpable inguinal lymphadenopathy and future site of ILND.^{4,50,78}

The boundaries of the standard, full-template ILND (ie, Daseler's quadrilateral area) are: superiorly, the inguinal ligament; inferiorly, the fossa ovalis; laterally, the medical border of sartorius muscle; and medially by the lateral edge of adductor longus muscle.⁷⁸ Historically, it has been recommended to keep the patient on bed rest for 48 to 72 hours, especially after myocutaneous flaps or the repair of large skin defects, although the necessity for this is debatable and not corroborated with rigorous scientific data. Closed suction drains are placed at surgery and are typically removed when drainage is less than 50 to 100 mL per day.^{78,79} Consideration should be given to keeping the patient on a suppressive dose of an oral cephalosporin (or other gram positive covering broad spectrum) for several days to weeks postoperatively in an attempt to decrease the risk of wound-related issues and minimize the risk for overall complications. However, the data supporting this treatment approach are very limited.⁷⁸

Modified Template Lymphadenectomy

In attempts to decrease the morbidity associated with standard ILND, a modified template lymphadenectomy has been proposed that uses a shorter skin incision, limiting the field of inguinal dissection by excluding the area lateral to the femoral artery and caudal to the fossa ovalis, with preservation of the saphenous vein and elimination of the need to transpose the sartorius muscle while providing an adequate therapeutic effect. This technique is commonly reserved for patients with a primary tumor that places them at increased risk for inguinal metastasis but with clinically negative groins on examination.^{78,80} The modified technique has shown a decrease in complications. Contemporary modified ILND should include the central and superior zones of the inguinal region, as these sections were not included in the dissection leading to a false-negative rate of 15%.^{81,82} It is important to note that if nodal involvement is detected on frozen section, the surgical procedure should be

converted to a standard, full-template lymphadenectomy. A standard full-template lymphadenectomy should be considered in all patients who have resectable inguinal lymphadenopathy. However, recent studies would favor neoadjuvant chemotherapy prior to proceeding with surgery, particularly in patients with bulky ILN metastases (ie, fixed nodes or nodal diameter ≥ 3 cm).^{83,84} Generally, ILND is performed within 4 to 6 weeks following the completion of systemic chemotherapy to allow patient recovery while minimizing the risk of cancer progression post-chemotherapy.

Delayed Inguinal Lymphadenectomy

Since data exist that suggests that men with clinically negative groins undergoing immediate ILND have better survival outcomes than men undergoing delayed ILND once their groins are clinically positive, in most circumstances men with high-risk penile tumors should undergo immediate ILND. However, patients with lower-risk tumors who are undergoing active surveillance or high-risk men who refuse immediate ILND may experience an inguinal nodal recurrence at some time point during follow-up. The median time to inguinal recurrence after treatment of the primary penile tumor is approximately 6 months, 90% occurring by year 3 and 100% by year 5.⁸⁵⁻⁸⁷

Unilateral Versus Bilateral Lymphadenectomy

In patients with high-risk features that do not have palpable lymph nodes, bilateral lymphadenectomy is generally performed. This is because it is not possible to predict the laterality of inguinal nodal metastasis based on the location of the tumor on the penis. Similarly, in patients who have a unilateral palpable node, about 30% will have contralateral positive nodes that were just not palpable.⁸⁸ Therefore, bilateral lymphadenectomy should be considered the standard of care in patients undergoing immediate ILND for high-risk penile tumors or

because of palpable nodes. When there is a delayed (>1 year after treatment of the primary penile tumor) inguinal recurrence of cancer, it is usually unilateral, and some authors have suggested that ipsilateral ILND is adequate while others have advocated for bilateral ILND in this circumstance.⁴

Pelvic Lymphadenectomy

Approximately 20% to 30% of patients with positive ILNs will also have cancer within PLNs. Interestingly, penile tumors do not appear to metastasize to the PLNs without first affecting the inguinal node echelon (ie, no skip lesions).^{62,87} Patients who have just one positive inguinal node have a risk of pelvic nodal involvement of less than 5% as reported by the Netherlands Cancer Institute.⁸⁹ The presence of cancer within the PLN is associated with a very poor 5-year survival rate typically of less than 10%. Based on these prior reports, pelvic lymphadenectomy (resection of external iliac, internal iliac, and obturator lymph nodes) is recommended in patients with 2 or more positive ILNs and in the clinical context of high-grade cancer within the ILN pathologic specimen. Pelvic lymph node dissection (PLND) can be conducted during the same operative session as the ILND if the intraoperative frozen section is positive in 2 or more of the inguinal nodes (raising the importance of obtaining a lymph node count intraoperatively) or in a delayed staged fashion based on the pathologic features of the ILND specimen.

One area of controversy is whether the PLND should be performed ipsilaterally or bilaterally in patients with unilateral positive ILNs. Crossover (right to left or left to right) of inguinal to pelvic nodes has not been well studied and hence both approaches are feasible and left at the discretion of the surgeon based on case-specific characteristics.

Chemotherapy

A patient who presents with resectable bulky disease will rarely be cured with a single treatment modality. Consideration should be given to neoadjuvant chemotherapy if ILNs are ≥ 4 cm. One of the most commonly utilized neoadjuvant systemic chemotherapy regimens is a combination of bleomycin, methotrexate, and cisplatin (BMP).⁹⁰ Patients who may benefit from surgical consolidation would be those who had stable, partial, or complete response following systemic chemotherapy, thus increasing their potential for disease-free survival.^{83,84} Recently, Pagliaro et al⁹¹ performed a phase II clinical trial in 30 patients, with stage N2 or N3 (stage III or stage IV) penile cancer without distant metastases, receiving neoadjuvant chemotherapy with paclitaxel, ifosfamide, and cisplatin. In their series, 50% of patients were noted to have a clinically meaningful response and 22 (73.3%) subsequently underwent surgery. There was an improved time to progression and overall survival associated with chemotherapy responsiveness ($P < .001$ and $P = .001$, respectively), absence of bilateral residual tumor ($P = .002$ and $P = .017$, respectively), and absence of extranodal extension ($P = .001$ and $P = .004$, respectively) or skin involvement ($P = .009$ and $P = .012$, respectively).

NCCN Recommendations

Non-Palpable Nodes

Most low-risk patients are followed with a surveillance protocol, as the probability of occult micrometastases in ILNs is less than 17%.^{60,86} For patients at high or intermediate risk, a modified or radical inguinal lymphadenectomy is strongly recommended as occult metastatic disease ranges between 68% and 73%.^{46,60,86} If positive nodes are present on the frozen section, then a superficial and deep inguinal lymphadenectomy should be performed (with consideration of a PLND).

As DSNB is currently not widely practiced in the United States, it is a category 2B option for examining non-palpable nodes to determine the need for a modified lymphadenectomy in place of predictive factors.^{92,93} This technique should be performed in tertiary care referral centers with substantial experience. DSNB is not recommended for Ta tumors as observation alone of the ILNs is sufficient for these well-differentiated lesions in the absence of palpable adenopathy.

Unilateral Palpable Nodes <4 cm

FNA of the lymph nodes is considered standard for these patients if no risk feature is present in the primary lesion. Risk features include T1, high grade, lymphovascular invasion, and poor differentiation in over half of the tumor cells. The NCCN Panel recommends omitting the procedure for patients with high-risk primary lesions to avoid delay of lymphadenectomy. A negative FNA biopsy should be confirmed with an excisional biopsy. Alternatively, careful surveillance may be considered following a negative FNA. Positive findings from either procedure warrant an immediate ILND.

Palpable Nodes ≥ 4 cm (fixed or mobile)

Large, unilateral, mobile nodes should first be confirmed by FNA. A negative FNA should be confirmed by an excisional biopsy. Patients with confirmed nodes are amenable to standard or modified ILND. Neoadjuvant chemotherapy should be considered before surgery. No further treatment is necessary if no viable tumor elements are detected in the surgical specimen. Patients with viable disease in a single node after undergoing systemic chemotherapy can be considered for a PLND. Category 2B is assigned to adjuvant chemotherapy. PLND with or without postoperative radiation is also a category 2B recommendation.

In the case of multiple or bilateral ILNs, patients should undergo an FNA of the lymph nodes regardless of whether these are mobile or fixed. A negative result should be confirmed with excisional biopsy. If results are again negative, the patient should be closely followed. Patients with a positive aspiration or biopsy should receive neoadjuvant chemotherapy followed by ILND and PLND.

Patients with abnormal PLNs on imaging (CT or MRI) are stratified by resectability. Nonsurgical candidates should be treated by chemoradiation. Patients with resectable disease should receive neoadjuvant systemic chemotherapy with consideration of a confirmatory percutaneous biopsy or PET/CT. Those who respond to therapy or become stable should undergo bilateral superficial and deep ILND and bilateral PLND if possible. Those who progress may receive additional systemic chemotherapy with consideration of local-field radiation or participation in a clinical trial.

Surveillance

Initial treatment of the primary tumor and lymph nodes dictates the follow-up schedule (see algorithm). A large retrospective review of 700 patients found that penile-sparing therapies carry a significantly higher risk of local recurrence (28%) than partial or total penectomy (5%) and thus require closer surveillance.⁸⁷ Patients without nodal involvement had a regional recurrence rate of 2% compared to 19% for patients with N+ disease. Of all recurrences, 92% were detected within 5 years of primary treatment.

Follow-up for all patients includes a clinical exam of the penis and inguinal region. Imaging is not routinely indicated for early disease (except for obese patients or patients who have undergone inguinal surgery since physical exam may be challenging), but may be used

upon abnormal findings. For patients with N2 or N3 disease, imaging of the chest, abdomen, and pelvic area is recommended.

Recurrence

Invasion of the corpora cavernosa is an adverse finding after initial organ-sparing treatment that warrants partial or total penectomy.^{94,95} For primary tumor recurrences without corpora cavernosa infiltration, salvage penile-sparing options can be considered (category 2B).

A recurrence in the inguinal region carries a poor prognosis (median survival <6 months) and optimal management remains elusive. Possible salvage options include systemic chemotherapy, EBRT, surgery, or a combination thereof.^{50,96}

Metastatic Disease

Imaging of the abdomen and pelvis should be obtained when metastasis is suspected to evaluate for pelvic and/or retroperitoneal lymph nodes. PLN metastases is an ominous finding, with a 5-year survival rate of 0% to 66% for all cases and 17% to 54% for microscopic invasion only, with the mean 5-year survival being approximately 10%.^{4,97-101} In patients with ILN metastases, 20% to 30% will have PLN metastases.⁴ This can be further characterized such that if 2 to 3 ILNs are involved, there is a 23% probability of PLN involvement. With 3 or more ILNs this probability increases to 56%.¹⁰²

Pettaway et al¹⁰³ evaluated the treatment options for stage IV penile cancer—clinical stage N3 (deep inguinal nodes or pelvic nodes) or M1 disease (distant metastases)—including chemotherapy, radiotherapy, and inguinal lymphadenectomy. Cisplatin-based regimens (paclitaxel, ifosfamide, and cisplatin or alternatively 5-FU plus cisplatin) are the most active first-line systemic chemotherapy regimens. The panel did not recommend regimens containing bleomycin because of high toxicity.



Those patients with a proven objective response to systemic chemotherapy are amenable to consolidative ILND with curative potential or palliation. However, surgical consolidation should not be performed on patients who progress during systemic chemotherapy except for local symptomatic control. Preoperative radiotherapy may also be given to patients who have lymph nodes ≥ 4 cm without skin fixation to improve surgical resectability and decrease local recurrence. For patients with unresectable inguinal or bone metastases, radiotherapy may provide a palliative benefit after chemotherapy. Salvage systemic chemotherapy may also be considered upon disease progression. Possible choices of monotherapy include capecitabine, carboplatin, docetaxel, 5-FU, methotrexate, paclitaxel, and panitumumab.¹⁰⁴⁻¹⁰⁹ However, as consensus is lacking in the second-line setting, the NCCN Panel strongly recommends consideration of clinical trial participation. Best supportive care remains an option for such advanced cases.

Summary

SCC of the penis is a disease that mandates prompt medical/surgical intervention and patient compliance to obtain the most favorable outcomes. A thorough history and physical is the initial step in this process, followed by a biopsy of the primary lesion to establish a pathologic diagnosis. Accurate clinical staging allows for a comprehensive treatment approach to be devised, thus optimizing therapeutic efficacy and minimizing treatment-related morbidity. Prognostic factors help predict if lymph node metastases are suspect in the absence of any palpable inguinal lymphadenopathy. When clinically indicated, an ILND has curative potential, particularly when performed early, with contemporary surgical series demonstrating its reduced morbidity.



References

1. Pettaway CA, Lynch D, Jr, Davis D. Tumors of the Penis. In: Wein AJ, Kavoussi L, Novick AC, et al., eds. Campbell-Walsh Urology (ed 9). Philadelphia: Saunders; 2007:959-992.
2. Siegel R, Ward E, Brawley O, Jemal A. Cancer statistics, 2011: The impact of eliminating socioeconomic and racial disparities on premature cancer deaths. *CA Cancer J Clin* 2011;caac.20121. Available at: <http://onlinelibrary.wiley.com/doi/10.3322/caac.20121/pdf>.
3. Pow-Sang MR, Ferreira U, Pow-Sang JM, et al. Epidemiology and natural history of penile cancer. *Urology* 2010;76:S2-6. Available at: <http://www.ncbi.nlm.nih.gov/pubmed/20691882>.
4. Horenblas S. Lymphadenectomy for squamous cell carcinoma of the penis. Part 2: the role and technique of lymph node dissection. *BJU Int* 2001;88:473-483. Available at: <http://www.ncbi.nlm.nih.gov/pubmed/11589660>.
5. Hernandez BY, Barnholtz-Sloan J, German RR, et al. Burden of invasive squamous cell carcinoma of the penis in the United States, 1998-2003. *Cancer* 2008;113:2883-2891. Available at: <http://www.ncbi.nlm.nih.gov/pubmed/18980292>.
6. Dillner J, von Krogh G, Horenblas S, Meijer CJ. Etiology of squamous cell carcinoma of the penis. *Scand J Urol Nephrol Suppl* 2000:189-193. Available at: <http://www.ncbi.nlm.nih.gov/pubmed/11144896>.
7. Sufrin G, Huben R. Benign and malignant lesions of the penis. In: JY G, ed. *Adult and Pediatric Urology* (ed 2). Chicago: Year Book Medical Publisher; 1991:1643.
8. Daling JR, Madeleine MM, Johnson LG, et al. Penile cancer: importance of circumcision, human papillomavirus and smoking in situ and invasive disease. *Int J Cancer* 2005;116:606-616. Available at: <http://www.ncbi.nlm.nih.gov/pubmed/15825185>.
9. Sarkar FH, Miles BJ, Plieth DH, Crissman JD. Detection of human papillomavirus in squamous neoplasm of the penis. *J Urol* 1992;147:389-392. Available at: <http://www.ncbi.nlm.nih.gov/pubmed/1310122>.
10. Engels EA, Pfeiffer RM, Goedert JJ, et al. Trends in cancer risk among people with AIDS in the United States 1980-2002. *AIDS* 2006;20:1645-1654. Available at: <http://www.ncbi.nlm.nih.gov/pubmed/16868446>.
11. Maden C, Sherman KJ, Beckmann AM, et al. History of circumcision, medical conditions, and sexual activity and risk of penile cancer. *J Natl Cancer Inst* 1993;85:19-24. Available at: <http://www.ncbi.nlm.nih.gov/pubmed/8380060>.
12. Depasquale I, Park AJ, Bracka A. The treatment of balanitis xerotica obliterans. *BJU Int* 2000;86:459-465. Available at: <http://www.ncbi.nlm.nih.gov/pubmed/10971272>.
13. Micali G, Nasca MR, Innocenzi D, Schwartz RA. Penile cancer. *J Am Acad Dermatol* 2006;54:369-391. Available at: <http://www.ncbi.nlm.nih.gov/pubmed/16488287>.
14. Barbagli G, Palminteri E, Mirri F, et al. Penile carcinoma in patients with genital lichen sclerosus: a multicenter survey. *J Urol* 2006;175:1359-1363. Available at: <http://www.ncbi.nlm.nih.gov/pubmed/16515998>.
15. Stern RS. Genital tumors among men with psoriasis exposed to psoralens and ultraviolet A radiation (PUVA) and ultraviolet B radiation. The Photochemotherapy Follow-up Study. *N Engl J Med* 1990;322:1093-1097. Available at: <http://www.ncbi.nlm.nih.gov/pubmed/2320078>.
16. Bleeker MCG, Heideman DAM, Snijders PJF, et al. Penile cancer: epidemiology, pathogenesis and prevention. *World J Urol* 2009;27:141-150. Available at: <http://www.ncbi.nlm.nih.gov/pubmed/18607597>.



17. Penis. In: Edge SB, Byrd DR, Compton CC, et al., eds. AJCC Cancer Staging Manual (ed 7). New York: Springer; 2010:447.
18. Cubilla AL, Reuter V, Velazquez E, et al. Histologic classification of penile carcinoma and its relation to outcome in 61 patients with primary resection. *Int J Surg Pathol* 2001;9:111-120. Available at: <http://www.ncbi.nlm.nih.gov/pubmed/11484498>.
19. Guimaraes GC, Cunha IW, Soares FA, et al. Penile squamous cell carcinoma clinicopathological features, nodal metastasis and outcome in 333 cases. *J Urol* 2009;182:528-534. Available at: <http://www.ncbi.nlm.nih.gov/pubmed/19524964>.
20. Ficarra V, Akduman B, Bouchot O, et al. Prognostic factors in penile cancer. *Urology* 2010;76:S66-73. Available at: <http://www.ncbi.nlm.nih.gov/pubmed/20691887>.
21. Barocas DA, Chang SS. Penile cancer: clinical presentation, diagnosis, and staging. *Urol Clin North Am* 2010;37:343-352. Available at: <http://www.ncbi.nlm.nih.gov/pubmed/20674691>.
22. Leijte JAP, Gallee M, Antonini N, Horenblas S. Evaluation of current TNM classification of penile carcinoma. *J Urol* 2008;180:933-938. Available at: <http://www.ncbi.nlm.nih.gov/pubmed/18635216>.
23. Leijte JAP, Horenblas S. Shortcomings of the current TNM classification for penile carcinoma: time for a change? *World J Urol* 2009;27:151-154. Available at: <http://www.ncbi.nlm.nih.gov/pubmed/18690458>.
24. Sobin LH, Wittekind C, International Union against Cancer. *TNM Classification of Malignant Tumours* (ed 6). New York: Wiley-Liss; 2002.
25. Slaton JW, Morgenstern N, Levy DA, et al. Tumor stage, vascular invasion and the percentage of poorly differentiated cancer: independent prognosticators for inguinal lymph node metastasis in penile squamous cancer. *J Urol* 2001;165:1138-1142. Available at: <http://www.ncbi.nlm.nih.gov/pubmed/11257655>.
26. Velazquez EF, Ayala G, Liu H, et al. Histologic grade and perineural invasion are more important than tumor thickness as predictor of nodal metastasis in penile squamous cell carcinoma invading 5 to 10 mm. *Am J Surg Pathol* 2008;32:974-979. Available at: <http://www.ncbi.nlm.nih.gov/pubmed/18460979>.
27. Pizzocaro G, Algaba F, Horenblas S, et al. EAU penile cancer guidelines 2009. *Eur Urol* 2010;57:1002-1012. Available at: <http://www.ncbi.nlm.nih.gov/pubmed/20163910>.
28. Lont AP, Besnard APE, Gallee MPW, et al. A comparison of physical examination and imaging in determining the extent of primary penile carcinoma. *BJU Int* 2003;91:493-495. Available at: <http://www.ncbi.nlm.nih.gov/pubmed/12656901>.
29. Choi JW, Choi M, Cho KH. A case of erythroplasia of queyrat treated with imiquimod 5% cream and excision. *Ann Dermatol* 2009;21:419-422. Available at: <http://www.ncbi.nlm.nih.gov/pubmed/20523838>.
30. Schroeder TL, Sengelmann RD. Squamous cell carcinoma in situ of the penis successfully treated with imiquimod 5% cream. *J Am Acad Dermatol* 2002;46:545-548. Available at: <http://www.ncbi.nlm.nih.gov/pubmed/11907505>.
31. Taliaferro SJ, Cohen GF. Bowen's disease of the penis treated with topical imiquimod 5% cream. *J Drugs Dermatol* 2008;7:483-485. Available at: <http://www.ncbi.nlm.nih.gov/pubmed/18505144>.
32. Feldman AS, McDougal WS. Long-term outcome of excisional organ sparing surgery for carcinoma of the penis. *J Urol* 2011;186:1303-1307. Available at: <http://www.ncbi.nlm.nih.gov/pubmed/21862071>.
33. Bandieramonte G, Colecchia M, Mariani L, et al. Peniscopically controlled CO2 laser excision for conservative treatment of in situ and T1 penile carcinoma: report on 224 patients. *Eur Urol* 2008;54:875-882. Available at: <http://www.ncbi.nlm.nih.gov/pubmed/18243513>.



34. Horenblas S, van Tinteren H, Delemarre JF, et al. Squamous cell carcinoma of the penis. II. Treatment of the primary tumor. J Urol 1992;147:1533-1538. Available at: <http://www.ncbi.nlm.nih.gov/pubmed/1593683>.

35. Morelli G, Pagni R, Mariani C, et al. Glansectomy with split-thickness skin graft for the treatment of penile carcinoma. Int J Impot Res 2009;21:311-314. Available at: <http://www.ncbi.nlm.nih.gov/pubmed/19458620>.

36. O'Kane HF, Pahuja A, Ho KJ, et al. Outcome of glansectomy and skin grafting in the management of penile cancer. Adv Urol 2011;2011:240824. Available at: <http://www.ncbi.nlm.nih.gov/pubmed/21603193>.

37. Pietrzak P, Corbishley C, Watkin N. Organ-sparing surgery for invasive penile cancer: early follow-up data. BJU Int 2004;94:1253-1257. Available at: <http://www.ncbi.nlm.nih.gov/pubmed/15610100>.

38. Hatzichristou DG, Apostolidis A, Tzortzis V, et al. Glansectomy: an alternative surgical treatment for Buschke-Lowenstein tumors of the penis. Urology 2001;57:966-969. Available at: <http://www.ncbi.nlm.nih.gov/pubmed/11337304>.

39. Bissada NK, Yakout HH, Fahmy WE, et al. Multi-institutional long-term experience with conservative surgery for invasive penile carcinoma. J Urol 2003;169:500-502. Available at: <http://www.ncbi.nlm.nih.gov/pubmed/12544296>.

40. Frimberger D, Hungerhuber E, Zaak D, et al. Penile carcinoma. Is Nd:YAG laser therapy radical enough? J Urol 2002;168:2418-2421. Available at: <http://www.ncbi.nlm.nih.gov/pubmed/12441930>.

41. Azrif M, Logue JP, Swindell R, et al. External-beam radiotherapy in T1-2 N0 penile carcinoma. Clin Oncol (R Coll Radiol) 2006;18:320-325. Available at: <http://www.ncbi.nlm.nih.gov/pubmed/16703750>.

42. Crook J, Grimard L, Tsihlias J, et al. Interstitial brachytherapy for penile cancer: an alternative to amputation. J Urol 2002;167:506-511. Available at: <http://www.ncbi.nlm.nih.gov/pubmed/11792907>.

43. Rozan R, Albuissou E, Giraud B, et al. Interstitial brachytherapy for penile carcinoma: a multicentric survey (259 patients). Radiother Oncol 1995;36:83-93. Available at: <http://www.ncbi.nlm.nih.gov/pubmed/7501816>.

44. Zouhair A, Coucke PA, Jeanneret W, et al. Radiation therapy alone or combined surgery and radiation therapy in squamous-cell carcinoma of the penis? Eur J Cancer 2001;37:198-203. Available at: <http://www.ncbi.nlm.nih.gov/pubmed/11166146>.

45. Crook J, Ma C, Grimard L. Radiation therapy in the management of the primary penile tumor: an update. World J Urol 2009;27:189-196. Available at: <http://www.ncbi.nlm.nih.gov/pubmed/18636264>.

46. Horenblas S, van Tinteren H. Squamous cell carcinoma of the penis. IV. Prognostic factors of survival: analysis of tumor, nodes and metastasis classification system. J Urol 1994;151:1239-1243. Available at: <http://www.ncbi.nlm.nih.gov/pubmed/8158767>.

47. Minhas S, Kayes O, Hegarty P, et al. What surgical resection margins are required to achieve oncological control in men with primary penile cancer? BJU Int 2005;96:1040-1043. Available at: <http://www.ncbi.nlm.nih.gov/pubmed/16225525>.

48. de Crevoisier R, Slimane K, Sanfilippo N, et al. Long-term results of brachytherapy for carcinoma of the penis confined to the glans (N- or NX). Int J Radiat Oncol Biol Phys 2009;74:1150-1156. Available at: <http://www.ncbi.nlm.nih.gov/pubmed/19395183>.

49. Crook J, Jezioranski J, Cygler JE. Penile brachytherapy: technical aspects and postimplant issues. Brachytherapy 2010;9:151-158. Available at: <http://www.ncbi.nlm.nih.gov/pubmed/19854685>.



50. Heyns CF, Fleshner N, Sangar V, et al. Management of the lymph nodes in penile cancer. *Urology* 2010;76:43-57. Available at: <http://www.ncbi.nlm.nih.gov/pubmed/20691885>.
51. Solsona E, Algaba F, Horenblas S, et al. EAU Guidelines on Penile Cancer. *Eur Urol* 2004;46:1-8. Available at: <http://www.ncbi.nlm.nih.gov/pubmed/15183542>.
52. Kroon BK, Valdes Olmos RA, van Tinteren H, et al. Reproducibility of lymphoscintigraphy for lymphatic mapping in patients with penile carcinoma. *J Urol* 2005;174:2214-2217. Available at: <http://www.ncbi.nlm.nih.gov/pubmed/16280766>.
53. Hughes B, Leijte J, Shabbir M, et al. Non-invasive and minimally invasive staging of regional lymph nodes in penile cancer. *World J Urol* 2009;27:197-203. Available at: <http://www.ncbi.nlm.nih.gov/pubmed/18594830>.
54. Mueller-Lisse UG, Scher B, Scherr MK, Seitz M. Functional imaging in penile cancer: PET/computed tomography, MRI, and sentinel lymph node biopsy. *Curr Opin Urol* 2008;18:105-110. Available at: <http://www.ncbi.nlm.nih.gov/pubmed/18090498>.
55. Scher B, Seitz M, Albinger W, et al. Value of PET and PET/CT in the diagnostics of prostate and penile cancer. *Recent Results Cancer Res* 2008;170:159-179. Available at: <http://www.ncbi.nlm.nih.gov/pubmed/18019625>.
56. Scher B, Seitz M, Reiser M, et al. 18F-FDG PET/CT for staging of penile cancer. *J Nucl Med* 2005;46:1460-1465. Available at: <http://www.ncbi.nlm.nih.gov/pubmed/16157528>.
57. Tabatabaei S, Harisinghani M, McDougal WS. Regional lymph node staging using lymphotropic nanoparticle enhanced magnetic resonance imaging with ferumoxtran-10 in patients with penile cancer. *J Urol* 2005;174:923-927. Available at: <http://www.ncbi.nlm.nih.gov/pubmed/16093989>.
58. Caso JR, Rodriguez AR, Correa J, Spiess PE. Update in the management of penile cancer. *Int Braz J Urol* 2009;35:406-415. Available at: <http://www.ncbi.nlm.nih.gov/pubmed/19719855>.
59. Pizzocaro G, Piva L, Bandieramonte G, Tana S. Up-to-date management of carcinoma of the penis. *Eur Urol* 1997;32:5-15. Available at: <http://www.ncbi.nlm.nih.gov/pubmed/9266225>.
60. Solsona E, Iborra I, Rubio J, et al. Prospective validation of the association of local tumor stage and grade as a predictive factor for occult lymph node micrometastasis in patients with penile carcinoma and clinically negative inguinal lymph nodes. *J Urol* 2001;165:1506-1509. Available at: <http://www.ncbi.nlm.nih.gov/pubmed/11342906>.
61. Villavicencio H, Rubio-Briones J, Regalado R, et al. Grade, local stage and growth pattern as prognostic factors in carcinoma of the penis. *Eur Urol* 1997;32:442-447. Available at: <http://www.ncbi.nlm.nih.gov/pubmed/9412803>.
62. Cabanas RM. An approach for the treatment of penile carcinoma. *Cancer* 1977;39:456-466. Available at: <http://www.ncbi.nlm.nih.gov/pubmed/837331>.
63. Pettaway CA, Pisters LL, Dinney CP, et al. Sentinel lymph node dissection for penile carcinoma: the M. D. Anderson Cancer Center experience. *J Urol* 1995;154:1999-2003. Available at: <http://www.ncbi.nlm.nih.gov/pubmed/7500444>.
64. Leijte JAP, Kroon BK, Valdes Olmos RA, et al. Reliability and safety of current dynamic sentinel node biopsy for penile carcinoma. *Eur Urol* 2007;52:170-177. Available at: <http://www.ncbi.nlm.nih.gov/pubmed/17316967>.
65. Valdes Olmos RA, Tanis PJ, Hoefnagel CA, et al. Penile lymphoscintigraphy for sentinel node identification. *Eur J Nucl Med* 2001;28:581-585. Available at: <http://www.ncbi.nlm.nih.gov/pubmed/11383862>.



66. Gonzaga-Silva LF, Tavares JM, Freitas FC, et al. The isolated gamma probe technique for sentinel node penile carcinoma detection is unreliable. *Int Braz J Urol* 2007;33:58-63. Available at: <http://www.ncbi.nlm.nih.gov/pubmed/17335599>.

67. Kroon BK, Horenblas S, Meinhardt W, et al. Dynamic sentinel node biopsy in penile carcinoma: evaluation of 10 years experience. *Eur Urol* 2005;47:601-606. Available at: <http://www.ncbi.nlm.nih.gov/pubmed/15826750>.

68. Spiess PE, Izawa JI, Bassett R, et al. Preoperative lymphoscintigraphy and dynamic sentinel node biopsy for staging penile cancer: results with pathological correlation. *J Urol* 2007;177:2157-2161. Available at: <http://www.ncbi.nlm.nih.gov/pubmed/17509308>.

69. Tanis PJ, Lont AP, Meinhardt W, et al. Dynamic sentinel node biopsy for penile cancer: reliability of a staging technique. *J Urol* 2002;168:76-80. Available at: <http://www.ncbi.nlm.nih.gov/pubmed/12050496>.

70. Kroon BK, Horenblas S, Estourgie SH, et al. How to avoid false-negative dynamic sentinel node procedures in penile carcinoma. *J Urol* 2004;171:2191-2194. Available at: <http://www.ncbi.nlm.nih.gov/pubmed/15126783>.

71. Kroon BK, Horenblas S, Deurloo EE, et al. Ultrasonography-guided fine-needle aspiration cytology before sentinel node biopsy in patients with penile carcinoma. *BJU Int* 2005;95:517-521. Available at: <http://www.ncbi.nlm.nih.gov/pubmed/15705071>.

72. Crawshaw JW, Hadway P, Hoffland D, et al. Sentinel lymph node biopsy using dynamic lymphoscintigraphy combined with ultrasound-guided fine needle aspiration in penile carcinoma. *Br J Radiol* 2009;82:41-48. Available at: <http://www.ncbi.nlm.nih.gov/pubmed/19095815>.

73. Hadway P, Smith Y, Corbishley C, et al. Evaluation of dynamic lymphoscintigraphy and sentinel lymph-node biopsy for detecting occult

metastases in patients with penile squamous cell carcinoma. *BJU Int* 2007;100:561-565. Available at: <http://www.ncbi.nlm.nih.gov/pubmed/17578518>.

74. Ficarra V, Galfano A. Should the dynamic sentinel node biopsy (DSNB) be considered the gold standard in the evaluation of lymph node status in patients with penile carcinoma? *Eur Urol* 2007;52:17-19. Available at: <http://www.ncbi.nlm.nih.gov/pubmed/17376585>.

75. Stancik I, Holtl W. Penile cancer: review of the recent literature. *Curr Opin Urol* 2003;13:467-472. Available at: <http://www.ncbi.nlm.nih.gov/pubmed/14560140>.

76. Kroon BK, Horenblas S, Lont AP, et al. Patients with penile carcinoma benefit from immediate resection of clinically occult lymph node metastases. *J Urol* 2005;173:816-819. Available at: <http://www.ncbi.nlm.nih.gov/pubmed/15711276>.

77. McDougal WS. Preemptive lymphadenectomy markedly improves survival in patients with cancer of the penis who harbor occult metastases. *J Urol* 2005;173:681. Available at: <http://www.ncbi.nlm.nih.gov/pubmed/15711242>.

78. Sharp DS, Angermeier KW. Surgery of penile and urethral carcinoma. In: Wein AJ, Kavoussi L, Novick AC, et al., eds. *Campbell-Walsh Urology* (ed 9). Philadelphia: Saunders; 2007:993-1022.

79. Spiess PE, Hernandez MS, Pettaway CA. Contemporary inguinal lymph node dissection: minimizing complications. *World J Urol* 2009;27:205-212. Available at: <http://www.ncbi.nlm.nih.gov/pubmed/18762945>.

80. Catalona WJ. Re: Modified inguinal lymphadenectomy for carcinoma of the penis with preservation of saphenous veins: technique and preliminary results. *J Urol* 1988;140:836-836. Available at: <http://www.ncbi.nlm.nih.gov/pubmed/3418818>.



81. Lopes A, Rossi BM, Fonseca FP, Morini S. Unreliability of modified inguinal lymphadenectomy for clinical staging of penile carcinoma. *Cancer* 1996;77:2099-2102. Available at: <http://www.ncbi.nlm.nih.gov/pubmed/8640676>.

82. Protzel C, Alcaraz A, Horenblas S, et al. Lymphadenectomy in the surgical management of penile cancer. *Eur Urol* 2009;55:1075-1088. Available at: <http://www.ncbi.nlm.nih.gov/pubmed/19264390>.

83. Bermejo C, Busby JE, Spiess PE, et al. Neoadjuvant chemotherapy followed by aggressive surgical consolidation for metastatic penile squamous cell carcinoma. *J Urol* 2007;177:1335-1338. Available at: <http://www.ncbi.nlm.nih.gov/pubmed/17382727>.

84. Pagliaro LC, Crook J. Multimodality therapy in penile cancer: when and which treatments? *World J Urol* 2009;27:221-225. Available at: <http://www.ncbi.nlm.nih.gov/pubmed/18682961>.

85. Soria JC, Fizazi K, Piron D, et al. Squamous cell carcinoma of the penis: multivariate analysis of prognostic factors and natural history in monocentric study with a conservative policy. *Ann Oncol* 1997;8:1089-1098. Available at: <http://www.ncbi.nlm.nih.gov/pubmed/9426328>.

86. Theodorescu D, Russo P, Zhang ZF, et al. Outcomes of initial surveillance of invasive squamous cell carcinoma of the penis and negative nodes. *J Urol* 1996;155:1626-1631. Available at: <http://www.ncbi.nlm.nih.gov/pubmed/8627839>.

87. Leijte JAP, Kirrander P, Antonini N, et al. Recurrence patterns of squamous cell carcinoma of the penis: recommendations for follow-up based on a two-centre analysis of 700 patients. *Eur Urol* 2008;54:161-168. Available at: <http://www.ncbi.nlm.nih.gov/pubmed/18440124>.

88. Grabstald H. Controversies concerning lymph node dissection for cancer of the penis. *Urol Clin North Am* 1980;7:793-799. Available at: <http://www.ncbi.nlm.nih.gov/pubmed/7456188>.

89. Horenblas S, van Tinteren H, Delemarre JF, et al. Squamous cell carcinoma of the penis. III. Treatment of regional lymph nodes. *J Urol* 1993;149:492-497. Available at: <http://www.ncbi.nlm.nih.gov/pubmed/8437253>.

90. Haas GP, Blumenstein BA, Gagliano RG, et al. Cisplatin, methotrexate and bleomycin for the treatment of carcinoma of the penis: a Southwest Oncology Group study. *J Urol* 1999;161:1823-1825. Available at: <http://www.ncbi.nlm.nih.gov/pubmed/10332445>.

91. Pagliaro LC, Williams DL, Daliani D, et al. Neoadjuvant paclitaxel, ifosfamide, and cisplatin chemotherapy for metastatic penile cancer: a phase II study. *J Clin Oncol* 2010;28:3851-3857. Available at: <http://www.ncbi.nlm.nih.gov/pubmed/20625118>.

92. Leijte JAP, Hughes B, Graafland NM, et al. Two-center evaluation of dynamic sentinel node biopsy for squamous cell carcinoma of the penis. *J Clin Oncol* 2009;27:3325-3329. Available at: <http://www.ncbi.nlm.nih.gov/pubmed/19414668>.

93. Lont AP, Horenblas S, Tanis PJ, et al. Management of clinically node negative penile carcinoma: improved survival after the introduction of dynamic sentinel node biopsy. *J Urol* 2003;170:783-786. Available at: <http://www.ncbi.nlm.nih.gov/pubmed/12913697>.

94. Chaux A, Reuter V, Lezcano C, et al. Comparison of morphologic features and outcome of resected recurrent and nonrecurrent squamous cell carcinoma of the penis: a study of 81 cases. *Am J Surg Pathol* 2009;33:1299-1306. Available at: <http://www.ncbi.nlm.nih.gov/pubmed/19471153>.

95. Ornellas AA, Nobrega BL, Wei Kin Chin E, et al. Prognostic factors in invasive squamous cell carcinoma of the penis: analysis of 196 patients treated at the Brazilian National Cancer Institute. *J Urol* 2008;180:1354-1359. Available at: <http://www.ncbi.nlm.nih.gov/pubmed/18707720>.



96. Graafland NM, Moonen LM, van Boven HH, et al. Inguinal recurrence following therapeutic lymphadenectomy for node positive penile carcinoma: outcome and implications for management. *J Urol* 2011;185:888-893. Available at: <http://www.ncbi.nlm.nih.gov/pubmed/21239009>.

97. Lopes A, Bezerra AL, Serrano SV, Hidalgo GS. Iliac nodal metastases from carcinoma of the penis treated surgically. *BJU Int* 2000;86:690-693. Available at: <http://www.ncbi.nlm.nih.gov/pubmed/11069378>.

98. Pow-Sang JE, Benavente V, Pow-Sang JM, Pow-Sang M. Bilateral ilioinguinal lymph node dissection in the management of cancer of the penis. *Semin Surg Oncol* 1990;6:241-242. Available at: <http://www.ncbi.nlm.nih.gov/pubmed/2389105>.

99. Ravi R. Morbidity following groin dissection for penile carcinoma. *Br J Urol* 1993;72:941-945. Available at: <http://www.ncbi.nlm.nih.gov/pubmed/8306161>.

100. Sanchez-Ortiz RF, Pettaway CA. The role of lymphadenectomy in penile cancer. *Urol Oncol* 2004;22:236-244. Available at: <http://www.ncbi.nlm.nih.gov/pubmed/15271324>.

101. Srinivas V, Morse MJ, Herr HW, et al. Penile cancer: relation of extent of nodal metastasis to survival. *J Urol* 1987;137:880-882. Available at: <http://www.ncbi.nlm.nih.gov/pubmed/3573181>.

102. Culkin DJ, Beer TM. Advanced penile carcinoma. *J Urol* 2003;170:359-365. Available at: <http://www.ncbi.nlm.nih.gov/pubmed/12853775>.

103. Pettaway CA, Pagliaro L, Theodore C, Haas G. Treatment of visceral, unresectable, or bulky/unresectable regional metastases of penile cancer. *Urology* 2010;76:58-65. Available at: <http://www.ncbi.nlm.nih.gov/pubmed/20691886>.

104. Ahmed T, Sklaroff R, Yagoda A. Sequential trials of methotrexate, cisplatin and bleomycin for penile cancer. *J Urol* 1984;132:465-468. Available at: <http://www.ncbi.nlm.nih.gov/pubmed/6206239>.

105. Di Lorenzo G, Federico P, Buonerba C, et al. Paclitaxel in pretreated metastatic penile cancer: final results of a phase 2 study. *Eur Urol* 2011;60:1280-1284. Available at: <http://www.ncbi.nlm.nih.gov/pubmed/21871710>.

106. Necchi A, Nicolai N, Coecchia M, et al. Proof of activity of anti-epidermal growth factor receptor-targeted therapy for relapsed squamous cell carcinoma of the penis. *J Clin Oncol* 2011;29:e650-652. Available at: <http://www.ncbi.nlm.nih.gov/pubmed/21632506>.

107. Pizzocaro G, Nicolai N, Milani A. Taxanes in combination with cisplatin and fluorouracil for advanced penile cancer: preliminary results. *Eur Urol* 2009;55:546-551. Available at: <http://www.ncbi.nlm.nih.gov/pubmed/18649992>.

108. Shammas FV, Ous S, Fossa SD. Cisplatin and 5-fluorouracil in advanced cancer of the penis. *J Urol* 1992;147:630-632. Available at: <http://www.ncbi.nlm.nih.gov/pubmed/1538445>.

109. Theodore C, Skoneczna I, Bodrogi I, et al. A phase II multicentre study of irinotecan (CPT 11) in combination with cisplatin (CDDP) in metastatic or locally advanced penile carcinoma (EORTC PROTOCOL 30992). *Ann Oncol* 2008;19:1304-1307. Available at: <http://www.ncbi.nlm.nih.gov/pubmed/18417462>.