



National  
Comprehensive  
Cancer  
Network®

**NCCN Clinical Practice Guidelines in Oncology (NCCN Guidelines®)**

# **Central Nervous System Cancers**

Version 2.2014

**NCCN.org**

**Continue**



National  
Comprehensive  
Cancer  
Network®

# NCCN Guidelines® Version 2.2014 Panel Members

## Central Nervous System Cancers

[NCCN Guidelines Index](#)  
[CNS Table of Contents](#)  
[Discussion](#)

**\*Louis Burt Nabors, MD** Ψ/Chair  
University of Alabama at Birmingham  
Comprehensive Cancer Center

**Jana Portnow, MD** † Ψ/Vice-chair  
City of Hope  
Comprehensive Cancer Center

**Mario Ammirati, MD, MBA** ¶  
The Ohio State University  
Comprehensive Cancer Center - James Cancer  
Hospital and Solove Research Institute

**Henry Brem, MD** ¶  
The Sidney Kimmel Comprehensive  
Cancer Center at Johns Hopkins

**Paul Brown, MD** §  
The University of Texas  
MD Anderson Cancer Center

**Nicholas Butowski, MD** Ψ  
UCSF Helen Diller Family  
Comprehensive Cancer Center

**Marc C. Chamberlain, MD** Ψ  
Fred Hutchinson Cancer Research  
Center/University of Washington

**Lisa M. DeAngelis, MD** Ψ  
Memorial Sloan-Kettering Cancer Center

**Robert A. Fenstermaker, MD** ¶  
Roswell Park Cancer Institute

**Allan Friedman, MD** ¶  
Duke Cancer Institute

**NCCN**  
**Lauren Gallagher, RPh, PhD**  
**Maria Ho, PhD**  
**Nicole McMillian, MS**

**Mark R. Gilbert, MD** Ψ  
The University of Texas  
MD Anderson Cancer Center

**Jona Hattangadi-Gluth, MD** §  
UC San Diego Moores Cancer Center

**Deneen Hesser, MSHSA, RN, OCN** ¥  
American Brain Tumor Association

**Matthias Holdhoff, MD PhD** †  
The Sidney Kimmel Comprehensive  
Cancer Center at Johns Hopkins

**Larry Junck, MD** Ψ  
University of Michigan  
Comprehensive Cancer Center

**Ronald Lawson, MD**  
St. Jude Children's Research Hospital/  
University of Tennessee Cancer Institute

**Jay S. Loeffler, MD** §  
Dana-Farber/Brigham and Women's Cancer  
Center | Massachusetts General Hospital  
Cancer Center

**Paul L. Moots, MD** Ψ  
Vanderbilt-Ingram Cancer Center

**Maciej M. Mrugala, MD, PhD, MPH** Ψ  
Fred Hutchinson Cancer Research  
Center/University of Washington

**Herbert B. Newton, MD** Ψ  
The Ohio State University  
Comprehensive Cancer Center - James  
Cancer Hospital and Solove Research  
Institute

**Jeffrey J. Raizer, MD** Ψ  
Robert H. Lurie Comprehensive Cancer  
Center of Northwestern University

**Lawrence Recht, MD** Ψ  
Stanford Comprehensive Cancer Center

**Nicole Shonka, MD** †Ψ  
Fred & Pamela Buffet Cancer Center  
at The Nebraska Medical Center

**Dennis C. Shrieve, MD, PhD** §  
Huntsman Cancer Institute  
at the University of Utah

**Allen K. Sills, Jr., MD** ¶  
Vanderbilt-Ingram Cancer Center

**Lode J. Swinnen, MB, ChB** ‡  
The Sidney Kimmel Comprehensive Cancer  
Center at Johns Hopkins

**David Tran, MD, PhD** †  
Siteman Cancer Center at  
Barnes-Jewish Hospital and Washington  
University School of Medicine

**Nam Tran, MD, PhD** ¶  
Moffitt Cancer Center

**Frank D. Vrionis, MD, MPH, PhD** ¶  
Moffitt Cancer Center

**Patrick Yung Wen, MD** Ψ  
Dana-Farber/Brigham and Women's Cancer Center

**Continue**

† Medical oncology  
‡ Hematology/Hematology oncology  
§ Radiotherapy/Radiation oncology  
Ψ Neurology/neuro-oncology  
¶ Surgery/Surgical oncology  
¥ Patient Advocacy  
\* Writing committee member

[NCCN Guidelines Panel Disclosures](#)



National  
Comprehensive  
Cancer  
Network®

# NCCN Guidelines® Version 2.2014 Sub-Committees Central Nervous System Cancers

[NCCN Guidelines Index](#)  
[CNS Table of Contents](#)  
[Discussion](#)

## Meningiomas

Marc C. Chamberlain, MD Ψ/Lead  
Fred Hutchinson Cancer Research  
Center/University of Washington

Henry Brem, MD ¶  
The Sidney Kimmel Comprehensive  
Cancer Center at Johns Hopkins

Lisa M. DeAngelis, MD Ψ  
Memorial Sloan-Kettering Cancer  
Center

Robert A. Fenstermaker, MD ¶¶  
Roswell Park Cancer Institute

Deneen Hesser, MSHSA, RN, OCN ¥  
American Brain Tumor Association

Larry Junck, MD Ψ  
University of Michigan  
Comprehensive Cancer Center

Jay S. Loeffler, MD §  
Dana-Farber/Brigham and Women's  
Cancer Center | Massachusetts  
General Hospital Cancer Center

Paul L. Moots, MD Ψ  
Vanderbilt-Ingram Cancer Center

Jeffrey J. Raizer, MD Ψ  
Robert H. Lurie Comprehensive Cancer  
Center of Northwestern University

Allen K. Sills, Jr., MD ¶¶  
Vanderbilt-Ingram Cancer Center

## Metastatic Spine Tumors

Frank D. Vrionis, MD, MPH, PhD/Lead ¶¶  
Moffitt Cancer Center

Paul Brown, MD §  
The University of Texas  
MD Anderson Cancer Center

Marc C. Chamberlain, MD Ψ  
Fred Hutchinson Cancer Research  
Center/University of Washington

Robert A. Fenstermaker, MD ¶¶  
Roswell Park Cancer Institute

Allen K. Sills, Jr., MD ¶¶  
Vanderbilt-Ingram Cancer Center

## PCNSL Review

Maciej Mrugala, MD, PhD, MPH/Lead Ψ  
Fred Hutchinson Cancer Research  
Center/University of Washington

Lisa M. DeAngelis, MD Ψ  
Memorial Sloan-Kettering Cancer Center

Lode J. Swinnen, MB, ChB ‡  
The Sidney Kimmel Comprehensive  
Cancer Center at Johns Hopkins

## Adult Medulloblastoma

Maciej Mrugala, MD, PhD, MPH Ψ  
Fred Hutchinson Cancer Research  
Center/University of Washington

Jana Portnow, MD † Ψ  
City of Hope  
Comprehensive Cancer Center

## Primary Spinal Cord Tumors

Marc C. Chamberlain, MD Ψ  
Fred Hutchinson Cancer Research  
Center/University of Washington

Frank D. Vrionis, MD, MPH, PhD ¶¶  
H. Lee Moffitt Cancer Center  
and Research Institute

**Continue**

† Medical oncology  
‡ Hematology/Hematology oncology  
§ Radiotherapy/Radiation oncology  
Ψ Neurology/neuro-oncology  
¶¶ Surgery/Surgical oncology  
¥ Patient Advocacy

[NCCN Guidelines Panel Disclosures](#)

# NCCN Guidelines Version 2.2014 Sub-Committees

## Central Nervous System Cancers

### Principles of Imaging

Jeffrey J. Raizer, MD/Lead Ψ  
Robert H. Lurie Comprehensive  
Cancer Center of Northwestern University

Larry Junck, MD Ψ  
University of Michigan  
Comprehensive Cancer Center

Louis Burt Nabors, MD Ψ  
University of Alabama at Birmingham  
Comprehensive Cancer Center

### Principles of Brain Tumor Management

Deneen Hesser, MSHSA, RN, OCN ¥  
American Brain Tumor Association

Allen K. Sills, Jr., MD ¶  
Vanderbilt-Ingram Cancer Center

### Principles of Systemic Therapy

Louis Burt Nabors, MD/Lead Ψ  
University of Alabama at Birmingham  
Comprehensive Cancer Center

Marc C. Chamberlain, MD Ψ  
Fred Hutchinson Cancer Research  
Center/University of Washington

Matthias Holdhoff, MD PhD †  
The Sidney Kimmel Comprehensive  
Cancer Center at Johns Hopkins

Larry Junck, MD Ψ  
University of Michigan  
Comprehensive Cancer Center

Maciej Mrugala, MD, PhD, MPH Ψ  
Fred Hutchinson Cancer Research  
Center/University of Washington

Jana Portnow, MD † Ψ  
City of Hope  
Comprehensive Cancer Center

Lode J. Swinnen, MB, ChB ‡  
The Sidney Kimmel Comprehensive  
Cancer Center at Johns Hopkins

Patrick Yung Wen, MD Ψ  
Dana-Farber/Brigham and Women's  
Cancer Center

### Principles of Radiation Therapy

Dennis C. Shrieve, MD, PhD/Lead §  
Huntsman Cancer Institute  
at the University of Utah

Paul Brown, MD §  
The University of Texas  
MD Anderson Cancer Center

Larry Junck, MD Ψ  
University of Michigan  
Comprehensive Cancer Center

Jay J. Loeffler, MD §  
Dana-Farber/Brigham and Women's  
Cancer Center | Massachusetts General  
Hospital Cancer Center

Allen K. Sills, Jr., MD ¶  
Vanderbilt-Ingram Cancer Center

**Continue**

† Medical oncology  
‡ Hematology/Hematology oncology  
§ Radiotherapy/Radiation oncology  
Ψ Neurology/neuro-oncology  
¶ Surgery/Surgical oncology  
¥ Patient Advocacy



# NCCN Guidelines Version 2.2014 Table of Contents

## Central Nervous System Cancers

- [NCCN Central Nervous System Cancers Panel Members](#)
- [NCCN Central Nervous System Cancer Sub-Committee Members](#)
- [Summary of the Guidelines Updates](#)
- [Adult Low-Grade Infiltrative Supratentorial Astrocytoma/  
Oligodendroglioma \(excluding pilocytic astrocytoma\) \(ASTR-1\)](#)
- [Anaplastic Gliomas/Glioblastoma \(GLIO-1\)](#)
- [Adult Intracranial and Spinal Ependymoma \(EPEN-1\)](#)
- [Adult Medulloblastoma and Supratentorial PNET \(AMED-1\)](#)
- [Primary CNS Lymphoma \(PCNS-1\)](#)
- [Primary Spinal Cord Tumors \(PSCT-1\)](#)
- [Meningiomas \(MENI-1\)](#)
- [Limited \(1-3\) Metastatic Lesions \(LTD-1\)](#)
- [Multiple \(>3\) Metastatic Lesions \(MU-1\)](#)
- [Leptomeningeal Metastases \(LEPT-1\)](#)
- [Metastatic Spine Tumors \(SPINE-1\)](#)

### Principles of Brain Tumor Therapy:

- [Imaging \(BRAIN-A\)](#)
- [Surgery \(BRAIN-B\)](#)
- [Radiation \(BRAIN-C\)](#)
- [Systemic Therapy \(BRAIN-D\)](#)
- [Brain and Spinal Cord Tumor Management \(BRAIN-E\)](#)

**Clinical Trials:** The NCCN believes that the best management for any cancer patient is in a clinical trial. Participation in clinical trials is especially encouraged.

To find clinical trials online at NCCN member institutions, [click here:](#)  
[nccn.org/clinical\\_trials/physician.html](http://nccn.org/clinical_trials/physician.html)

**NCCN Categories of Evidence and Consensus:** All recommendations are Category 2A unless otherwise specified.

See [NCCN Categories of Evidence and Consensus](#)

The NCCN Guidelines® are a statement of evidence and consensus of the authors regarding their views of currently accepted approaches to treatment. Any clinician seeking to apply or consult the NCCN Guidelines is expected to use independent medical judgment in the context of individual clinical circumstances to determine any patient's care or treatment. The National Comprehensive Cancer Network® (NCCN®) makes no representations or warranties of any kind regarding their content, use or application and disclaims any responsibility for their application or use in any way. The NCCN Guidelines are copyrighted by National Comprehensive Cancer Network®. All rights reserved. The NCCN Guidelines and the illustrations herein may not be reproduced in any form without the express written permission of NCCN. ©2014.



# NCCN Guidelines Version 2.2014 Updates

## Central Nervous System Cancers

Updates in Version 2.2014 of the NCCN Guidelines for Central Nervous System Cancers from version 1.2014 include:

- The Discussion section has been updated to reflect the changes in the algorithm ([MS-1](#))

Updates in Version 1.2014 of the NCCN Guidelines for Central Nervous System Cancers from version 2.2013 include:

### Adult Low-Grade Infiltrative Supratentorial

Astrocytoma/Oligodendroglioma (excluding pilocytic astrocytoma):

#### ASTR-1

- Footnote “g”: “... ≤ 40 y...” changed to “... < 40 y...”
- Footnote “h”: “...Age > 40 y, KPS < 70, tumor dimension > 6 cm...” changed to “...Age ≥ 40 y, KPS < 70, tumor dimension ≥ 6 cm...”

### Anaplastic Gliomas/Glioblastoma

#### GLIO-2

- The “Pathology” listings were revised as follows:
  - ▶ *1p19q codeleted*: Anaplastic oligodendroglioma, Anaplastic oligoastrocytoma, ~~1p19q codeleted~~
  - ▶ *1p19q uni- or non-deleted*: Anaplastic oligodendroglioma, Anaplastic oligoastrocytoma, ~~1p19q uni- or non-deleted~~, Anaplastic astrocytoma
  - ▶ Anaplastic gliomas, Poor Performance status (KPS < 70 60). The KPS revision for Poor performance status was also made on [GLIO-3](#).
- Adjuvant Treatment for “1p19q codeleted: Anaplastic oligodendroglioma, Anaplastic oligoastrocytoma”: The recommendation was revised as follows, “Fractionated external beam RT and *neoadjuvant or adjuvant* PCV chemotherapy (category 1).”
- Footnote “k” is new to the algorithm: “The panel recommends that PCV be administered after RT (as per EORTC 26951) since the intensive PCV regimen given prior to RT (RTOG 9402) was not tolerated as well.”

#### GLIO-3

- Good performance status (KPS ≥ 70)” changed to “KPS ≥ 60”.
- Footnote “o” was revised: “*Benefit of treatment with temozolomide for glioblastomas beyond 6 months is unknown. The optimal duration of therapy treatment with temozolomide for anaplastic astrocytoma is unknown.*”

### Anaplastic Gliomas/Glioblastoma (continued)

#### GLIO-4

- Recurrent disease: The option “Consider alternating electric field therapy for glioblastoma” changed from a category 2B to a category 3 recommendation.

### Adult Intracranial and Spinal Ependymoma

(Excluding Subependymoma)

#### EPEN-1

- The algorithm title changed to “Adult Intracranial *and Spinal Ependymoma (Excluding Subependymoma and Myxopapillary).*”

#### EPEN-2

- This page now only addresses “Intracranial Ependymoma.”
- “Ependymoma or Anaplastic ependymoma status post stereotactic or open biopsy or subtotal resection” pathway: “Consider re-operation to complete resection” was added as an option before postoperative staging.

#### EPEN-3

- This is a separate page that was developed to provide recommendations for the treatment of spinal ependymomas.

### Adult Medulloblastoma and Supratentorial PNET

#### AMED-2

- Adjuvant Treatment for “Standard risk for recurrence”: “Concurrent chemoRT followed by post-radiation chemotherapy” changed to “Craniospinal RT with chemotherapy<sup>o</sup> followed by post-radiation chemotherapy.”
- Adjuvant Treatment for “High risk for recurrence”: Recommendation revised, “Craniospinal RT and post-radiation chemotherapy (~~consider collecting stem cells before craniospinal radiation~~)”. The information deleted is now listed as footnote “q”.

**Primary Spinal Cord Tumors****PSCT-2**

- Pathology; Other sub-types; Under “Hemangioblastoma”: “Consider screening for Von Hippel-Lindau syndrome” was added as an option. “Consider neuraxis imaging” was removed as an option.
- Pathology: Under “Ependymoma” link now refers to “Adult *and Spinal Ependymoma*”.

**PSCT-4**

- First column: “Consider RT for incompletely resected myxopapillary ependymoma” was removed as an option.
- After “Sequential MRI,” “Progression or recurrence” changed to “New or worsening symptoms or radiographic progression”. This wording was previously listed as a footnote.

**Meningiomas**

- Asymptomatic; Small (<30 mm): The following treatment recommendations were revised:
  - ▶ “Surgery if potential neurologic consequences and if accessible, followed by RT if WHO Grade 3 and consider RT for ~~sub-totally~~ resected WHO Grade 2.”
  - ▶ “RT if potential neurologic consequences *from surgery*.”
- Asymptomatic; Large (≥30 mm): Recommendation revised for clarity: “Surgery if accessible, followed by RT if WHO Grade 3; consider RT if ~~incomplete resection and WHO Grade 1/2 for resected or incompletely resected WHO Grade 2 or incompletely resected WHO Grade 1.~~”

**Limited (1-3) Metastatic Lesions****LTD-2**

- Disseminated systemic disease with poor systemic treatment options; Primary Treatment: “Consider best supportive/palliative care” was added as an option. “Consider chemotherapy (category 2B)” was removed as an option.
- “Clinical Presentation” revised: “...or Reasonable systemic treatment options *exist*.”
- “Newly diagnosed..” pathway; Resectable; Primary Treatment: Recommendation revised, “Surgical resection, followed by WBRT (category 1) or *followed by* stereotactic radiosurgery (SRS) (category 2B).”

**LTD-3**

- Follow-up revised: “MRI every 2-3 mo for 1 y...”
- After “Recurrent disease; local site”: Wording revised, “Previous surgery *only*”.
- Footnote “i” is new to the page: “MRI every 2 months (instead of 3 mo) for those patients treated with SRS alone.”
- Footnote removed, “Local or systemic chemotherapy.”

**LTD-4**

- After “No prior WBRT”: “Palliative/Best supportive care” moved above “WBRT”.

**Leptomeningeal Metastases****LEPT-1**

- Workup: Neuroaxis imaging added.
- Under “Risk Status:
  - ▶ Poor risk, Low Karnofsky performance status (KPS) clarified as <60. (Also for LEPT-2)
  - ▶ Good risk; High KPS clarified as ≥60. (Also for LEPT-2)
- Footnote “e” revised: “...a second lumbar puncture is sometimes helpful. *This is a volume dependent test and ideally ≥ 10 mL should be sent for cytologic analysis.*”

**LEPT-3**

- Normal Flow:
  - ▶ Primary Treatment: “Consider placing ventricular catheter and subcutaneous reservoir” moved from the bottom to the top of the list of options.
  - ▶ After primary treatment, recommendation revised, “~~Reassess CSF from site where CSF cytology was originally positive; if CSF cytology was originally negative reassess from a different site~~ Assess CSF from lumbar spine even if intraventricular catheter/reservoir is in place.”
- Footnote “i” revised: “Highly recommended to ensure patency of CSF flow ~~and adequacy of catheter placement if intraventricular catheter was placed.~~”



# NCCN Guidelines Version 2.2014 Updates

## Central Nervous System Cancers

### Leptomeningeal Metastases

#### LEPT-4

- “CSF cytology positive; “Patient clinically stable...” pathway; Last column at right: Phrasing revised:
  - ▶ “Negative cytology *or persistent positive cytology, but patient is clinically stable.*”
  - ▶ “Cytology continually positive and/or evidence of clinical or radiologic progression...”
- CSF cytology positive; “Evidence of clinical or radiologic progression...”; Last column at far right: Clarified as “Systemic chemotherapy”.
- Footnote “n” regarding postinduction therapy is new to page: “After completion of induction, consider neuroaxis imaging to assess sites that were previously radiographically positive.”

### Metastatic Spine Tumors

#### SPINE-2

- Spinal cord compression; Steroids; Treatment: Revised, “Surgery followed by RT (~~preferred~~ category 1)”.
- Footnote “i” revised: First bullet “Category 1 evidence supports the role of surgery in patients with *a solitary* epidural spinal cord compression *by a tumor not known to be radiosensitive and who are willing to undergo surgery.*”

### BRAIN-A---Principles of Brain Tumor Imaging

- First bullet; MRI of the brain and spine ( $\pm$  contrast); Last arrow: Renal insufficiency added to the list of limitations.
- Second bullet: CT of the brain and spine ( $\pm$  contrast); Last arrow: Renal insufficiency added to the list of limitations.
- Fifth bullet revised: “Brain *amino acid* FDG-PET scanning...”

### BRAIN-C---Principles of Brain Tumor Radiation Therapy

#### Page 1 of 3

- High Grade Gliomas (Grades III/IV)
  - ▶ Second bullet revised: “The recommended dose is 60 Gy in 1.8 to 2.0 Gy fractions. A slightly lower dose, ~~55–57 Gy such as 55.8 to 59.4 Gy in 1.8 Gy or 57 Gy in 1.9 Gy fractions~~, can be applied when the tumor volume is very large (gliomatosis) or for Grade III astrocytoma.

#### Page 1 of 3 (continued)

- High Grade Gliomas (Grades III/IV)
  - ▶ Third bullet revised: “In poorly performing patients or the elderly a hypofractionated accelerated course was found to be effective with the goal of completing the treatment in ~~3–4~~ 2-4 weeks. ~~Total doses vary between 40–50 Gy. Typical fractionation schedules are 34 Gy/10, 40.05 Gy/15 or 50 Gy/20.~~”
- Ependymoma
  - ▶ First bullet revised: “Limited Fields: *Intracranial* tumor volumes are best defined using pre- and postoperative imaging...”
  - ▶ New bullet added: “For spine ependymomas, see section on primary spinal cord tumors (**BRAIN-C 2 of 3**).”
- Adult Medulloblastoma and Supratentorial PNET
  - ▶ Standard risk for recurrence section revised
    - ◊ Conventional dose: 30-36 Gy CSI and boosting the primary brain site to 54-55.8 Gy without adjuvant chemotherapy
    - ◊ Reduced dose: 23.4 Gy CSI and boosting the primary brain site to 54-55.8 Gy with adjuvant chemotherapy
    - ◊ High risk for recurrence section revised: “36 Gy CSI with boosting primary brain site to 54-55.8 Gy.”
- New footnote added: “Considering protons over photons (if available) for craniospinal irradiation in adults is reasonable.”

#### Page 2 of 3

- Primary Spinal Cord Tumors
  - ▶ Bullet revised: “In tumors below the conus medularis (~~ie, myxopapillary ependymoma~~)-higher doses up to 60 Gy can be delivered.”
- Metastatic Spine
  - ▶ Bullet revised: “...Generally doses of 15-40 Gy are delivered in 1-15 fractions over 1 day - 3 weeks. ~~In general, the surface of the spinal cord should be kept to  $\leq$  12 Gy. It is critical to consider tolerance at the spine and/or nerve route.~~ In selected cases, or recurrences after previous radiation, stereotactic radiotherapy is appropriate. At the retreatment site, it is critical to consider tolerance of the spine and/or spinal nerve roots. Generally recommended that 6 months or more of time between treatments is required. ~~and that at retreatment the surface of the cord should not receive more than 10 Gy.~~”

#### Page 3 of 3

- New references added to page.

**BRAIN-D---Principles of Brain and Spinal Cord Tumor Systemic Therapy** [Page 2 of 7:](#) (continued)**Global Change**

- “Nitrosourea” changed to “Lomustine or carmustine”.

[Page 1 of 7](#)

- **Anaplastic Gliomas**
  - Recurrence/Salvage therapy; Fifth bullet; “Bevacizumab + chemotherapy”: Carboplatin was added to the list of chemotherapy options as a category 2B recommendation.
- **Glioblastoma**
  - Recurrence/Salvage therapy; Second bullet; “Bevacizumab + chemotherapy”: Carboplatin was added to the list of chemotherapy options as a category 2B recommendation.
- **Adult Intracranial and Spinal Ependymoma (excluding subependymoma)**
  - Recurrence: Temozolomide was added to the list of systemic therapy options.
- Footnote “†” was revised: ~~“Discontinuation of bevacizumab after progression may be associated with rapid neurological deterioration and bevacizumab may be continued in these circumstances. Patients who have good performance status but evidence of radiographic progression may benefit from continuation of bevacizumab to prevent rapid neurologic deterioration.”~~
- The following footnote is new: “Bevacizumab + chemotherapy can be considered for patients who have failed monotherapy with bevacizumab.”

[Page 2 of 7:](#)

- **Adult Medulloblastoma and Supratentorial PNET**
  - Recurrence/Salvage therapy: For patients who received “No prior chemotherapy” and those who received “Prior chemotherapy”: Recommendation revised: “*Consider high-dose chemotherapy with autologous stem cell reinfusion...*”
- **Primary CNS Lymphoma**
  - Recurrence or Progressive Disease
    - ◊ Recommendation revised: “*Consider high-dose chemotherapy with autologous stem cell reinfusion in patients who achieve a complete response with conventional doses of salvage chemotherapy or have no residual disease after re-resection.*”
    - ◊ Pemetrexed added to the list of systemic therapy options.

- **Meningiomas**

- “Hydroxyurea (category 2B)” was removed from the list of systemic therapy options.

[Page 3 of 7:](#)

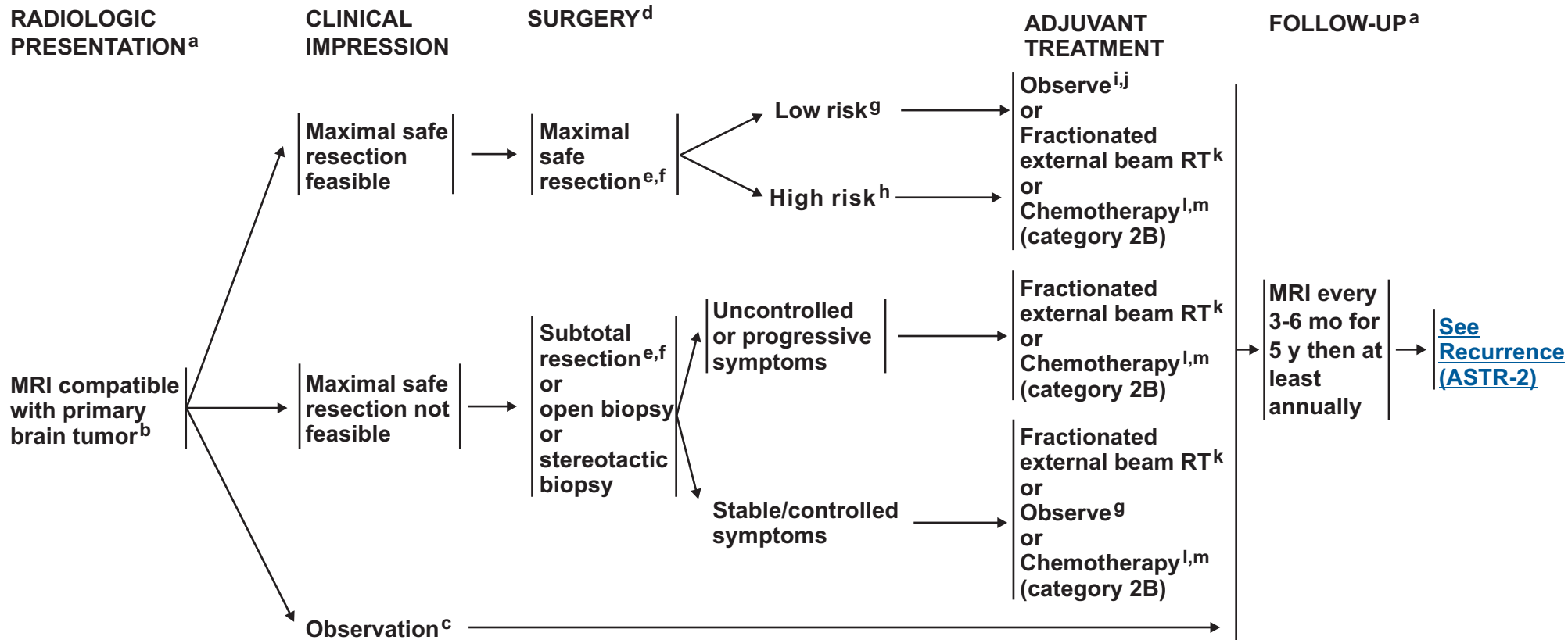
- **Limited (1-3) Metastatic or Multiple (>3) Metastatic Lesions**
  - “Organ specific therapy” was removed as a treatment heading.
  - **Recurrent Disease**
    - ◊ Ipilimumab (melanoma) was added to the list of systemic therapy options
    - ◊ The following *BRAF* inhibitors for melanoma were added:
      - ⊗ Dabrafenib
      - ⊗ Vemurafenib
- **Leptomeningeal Metastases**
  - **Treatment**
    - ◊ Second arrow; Intra-CSF chemotherapy
      - ⊗ Second bullet revised: Methotrexate (lymphoma/leukemias, breast)
      - ⊗ Fifth bullet revised: Rituximab (*lymphoma*)
      - ⊗ Trastuzumab (breast) added to the list of options
    - ◊ Third arrow revised: “High-dose methotrexate for ~~lymphomatous meningitis~~ *lymphoma and breast*”
    - ◊ “Weekly pulse erlotinib for EGFR exon 19 deletion or exon 21 L858R mutation (non-small cell lung cancer)” added to the list of systemic therapy options as a category 2B recommendation.

**BRAIN-E---Principles of Brain Tumor Management**

- **Multidisciplinary Care**; First bullet revised: “... allows for input from each of the major neuro-oncology disciplines, as well as allied services (physical/occupational therapy, social work, psychology, nursing) when available...”

# NCCN Guidelines Version 2.2014

## Adult Low-Grade Infiltrative Supratentorial Astrocytoma/Oligodendroglioma (Excluding Pilocytic Astrocytoma)



<sup>a</sup> See Principles of Brain Tumor Imaging (BRAIN-A).

<sup>b</sup> Consider a multidisciplinary review in treatment planning, especially once pathology is available (See Principles of Brain Tumor Management (BRAIN-E)).

<sup>c</sup> Surgery is generally recommended, but serial observations are appropriate for selected patients.

<sup>d</sup> See Principles of Brain Tumor Surgery (BRAIN-B).

<sup>e</sup> Consider testing for deletions in 1p19q if tumor has components of oligodendroglioma for prognostic purposes.

<sup>f</sup> Post-operative MRI should be done within 72 hours after surgery.

<sup>g</sup> Low-risk features: Oligodendroglioma or mixed oligoastrocytoma, <40 y, KPS ≥ 70, tumor dimension < 6 cm, minor or no neurological deficit, 1p and 19q codeleted, IDH1 or 2 mutated.

<sup>h</sup> High-risk features: 3 or more of: Astrocytoma, Age ≥40 y, KPS < 70, tumor dimension ≥6 cm, tumor crossing midline, preoperative neurological deficit of more than minor degree. One or no deletions on 1p and 19q, IDH1 or 2 not mutated, increased perfusion on imaging are also adverse factors that may be considered.

<sup>i</sup> Regular follow-up is essential for patients receiving observation alone after resection.

<sup>j</sup> If gross total resection (GTR) is achieved, consider further observation.

<sup>k</sup> See Principles of Brain Tumor Radiation Therapy (BRAIN-C).

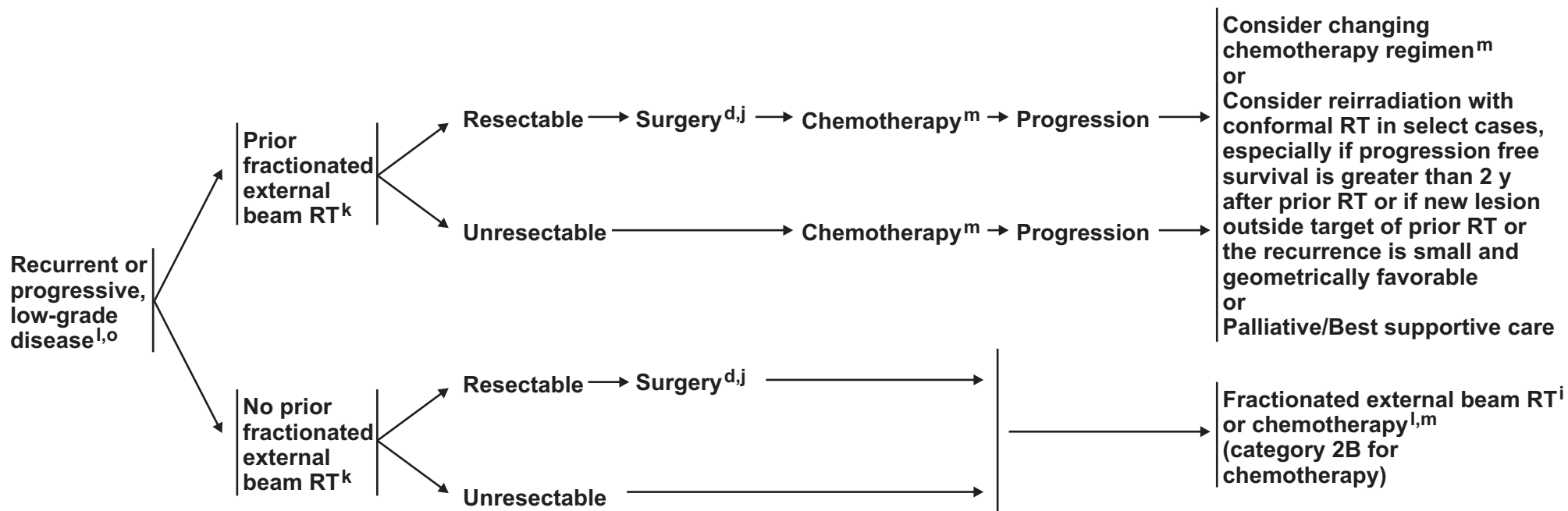
<sup>l</sup> Oligodendrogliomas, particularly those that have chromosomal loss of combined 1p19q, have been reported to be sensitive to alkylator chemotherapy. Consider chemotherapy for these patients.

<sup>m</sup> See Principles of Brain and Spinal Cord Systemic Therapy (BRAIN-D).

**Note:** All recommendations are category 2A unless otherwise indicated.

**Clinical Trials:** NCCN believes that the best management of any cancer patient is in a clinical trial. Participation in clinical trials is especially encouraged.

### RECURRENCE<sup>n</sup>



<sup>d</sup>See Principles of Brain Tumor Surgery (BRAIN-B).

<sup>j</sup>If gross total resection (GTR) is achieved, consider further observation.

<sup>k</sup>See Principles of Brain Tumor Radiation Therapy (BRAIN-C).

<sup>l</sup>Oligodendrogliomas, particularly those that have chromosomal loss of combined 1p19q, have been reported to be sensitive to alkylator chemotherapy. Consider chemotherapy for these patients.

<sup>m</sup>See Principles of Brain and Spinal Cord Systemic Therapy (BRAIN-D).

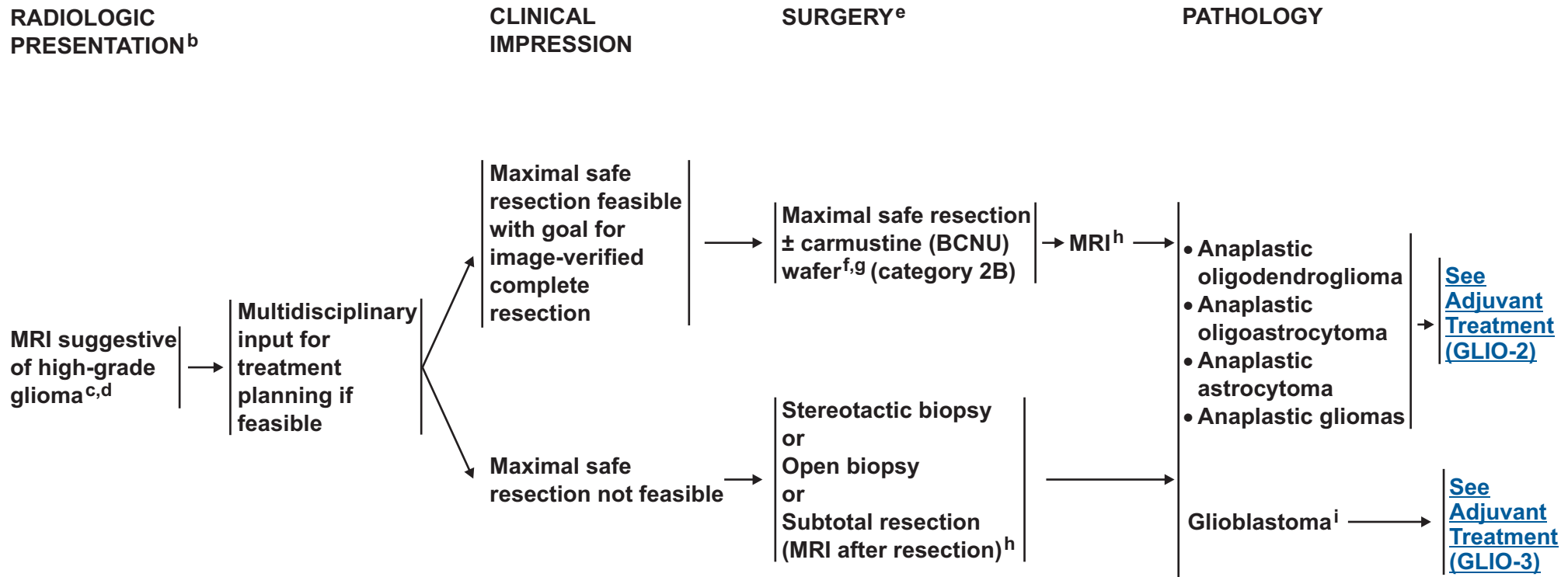
<sup>n</sup>Recurrence on neuroimaging can be confounded by treatment effects. Strongly consider tumor tissue sampling if there is a high index of suspicion of recurrence.

<sup>o</sup>At recurrence, there is a high propensity for these tumors to undergo malignant transformation. Sixty percent or more of astrocytomas and 40%-50% of oligodendrogliomas will eventually undergo transformation to a higher grade.

**Note:** All recommendations are category 2A unless otherwise indicated.  
**Clinical Trials:** NCCN believes that the best management of any cancer patient is in a clinical trial. Participation in clinical trials is especially encouraged.



# NCCN Guidelines Version 2.2014 Anaplastic Gliomas/Glioblastoma<sup>a</sup>



<sup>a</sup>This pathway includes the classification of mixed anaplastic oligoastrocytoma (AOA), anaplastic astrocytoma (AA), anaplastic oligodendroglioma (AO), and other rare anaplastic gliomas.

<sup>b</sup>See [Principles of Brain Tumor Imaging \(BRAIN-A\)](#).

<sup>c</sup>Biopsy first if MRI compatible with CNS lymphoma.

<sup>d</sup>Consider a multidisciplinary review in treatment planning, especially once pathology is available ([See Principles of Brain Tumor Management \[BRAIN-E\]](#)).

<sup>e</sup>See [Principles of Brain Tumor Surgery \(BRAIN-B\)](#).

<sup>f</sup>If frozen section diagnosis supports high-grade glioma.

<sup>9</sup>Treatment with carmustine wafer may impact enrollment in some adjuvant clinical trials.

<sup>h</sup>Post-operative MRI should be done within 72 hours after surgery.

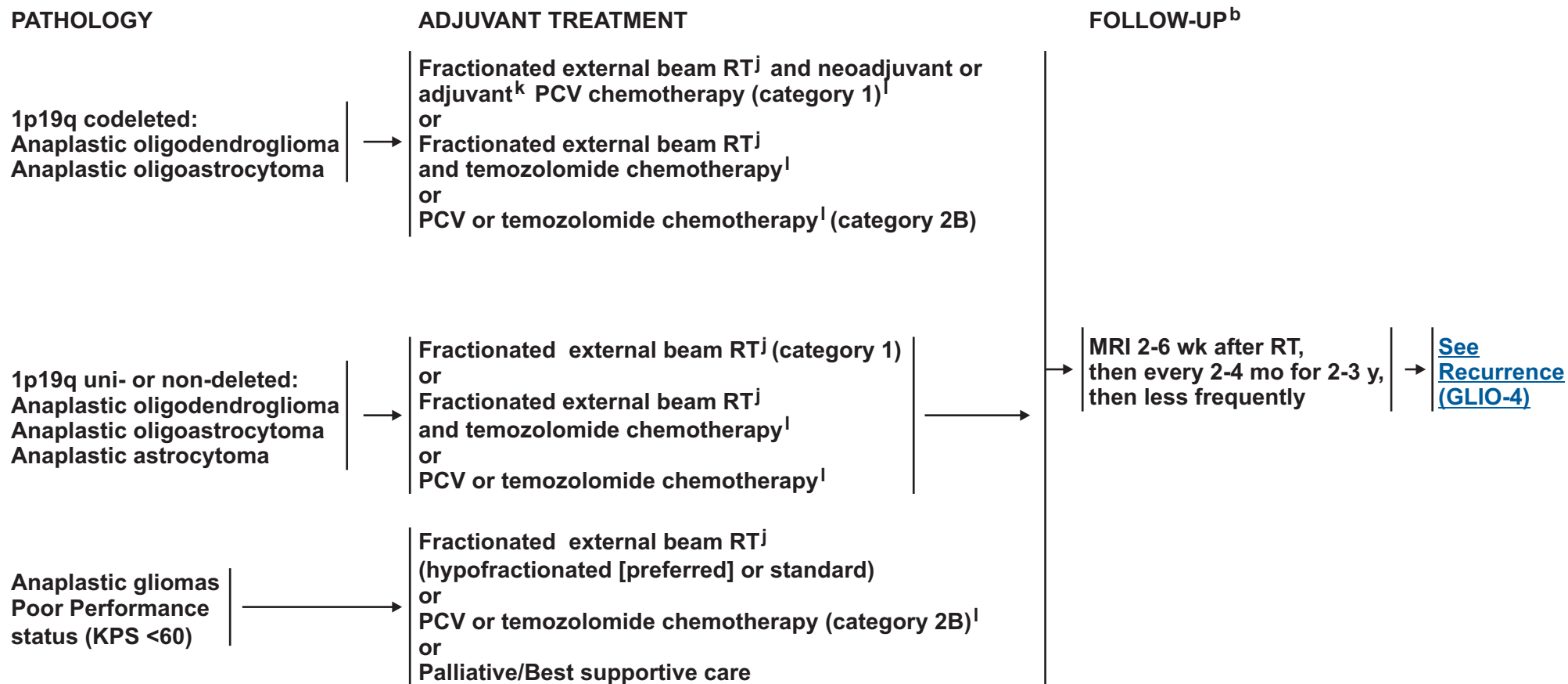
<sup>i</sup>This pathway also includes gliosarcoma.

**Note:** All recommendations are category 2A unless otherwise indicated.

**Clinical Trials:** NCCN believes that the best management of any cancer patient is in a clinical trial. Participation in clinical trials is especially encouraged.



# NCCN Guidelines Version 2.2014 Anaplastic Gliomas/Glioblastoma<sup>a</sup>



<sup>a</sup>This pathway includes the classification of mixed anaplastic oligoastrocytoma (AOA), anaplastic astrocytoma (AA), anaplastic oligodendroglioma (AO), and other rare anaplastic gliomas.

<sup>b</sup>[See Principles of Brain Tumor Imaging \(BRAIN-A\).](#)

<sup>j</sup>[See Principles of Brain Tumor Radiation Therapy \(BRAIN-C\).](#)

<sup>k</sup>The panel recommends that PCV be administered after RT (as per EORTC 26951) since the intensive PCV regimen given prior to RT (RTOG 9402) was not tolerated as well.

<sup>l</sup>[See Principles of Brain and Spinal Cord Systemic Therapy \(BRAIN-D\).](#)

**Note:** All recommendations are category 2A unless otherwise indicated.

**Clinical Trials:** NCCN believes that the best management of any cancer patient is in a clinical trial. Participation in clinical trials is especially encouraged.



# NCCN Guidelines Version 2.2014 Anaplastic Gliomas/Glioblastoma<sup>a</sup>

## PATHOLOGY

Glioblastoma<sup>i</sup>  
± carmustine  
(BCNU) wafer<sup>m</sup>

Good performance  
status (KPS ≥60)

Poor Performance  
status (KPS <60)

## ADJUVANT TREATMENT

Fractionated external beam RT<sup>j</sup>  
+ concurrent and adjuvant temozolomide,  
for age ≤ 70 y (category 1)<sup>l,n,o</sup>  
or  
Fractionated external beam RT<sup>j</sup>  
+ concurrent and adjuvant temozolomide  
for age > 70 y<sup>l,n</sup>  
or  
Fractionated external beam RT<sup>j</sup>  
(hypofractionated) (category 1)  
for age > 70 y  
or  
Chemotherapy<sup>l</sup>  
(temozolomide if methylguanine  
methyl-transferase [MGMT] promotor  
methylation positive)  
for age > 70 y

Fractionated external beam RT<sup>j</sup>  
(hypofractionated or standard)  
or  
Chemotherapy<sup>l</sup>  
or  
Palliative/Best supportive care

## FOLLOW-UP<sup>b</sup>

→ MRI 2-6 wk after RT,  
then every 2-4 mo for 2-3 y, → [See  
Recurrence  
\(GLIO-4\)](#)

<sup>a</sup>This pathway includes the classification of mixed anaplastic oligoastrocytoma (AOA), anaplastic astrocytoma (AA), anaplastic oligodendroglioma (AO), and other rare anaplastic gliomas.

<sup>b</sup>[See Principles of Brain Tumor Imaging \(BRAIN-A\).](#)

<sup>i</sup>This pathway also includes gliosarcoma.

<sup>j</sup>[See Principles of Brain Tumor Radiation Therapy \(BRAIN-C\).](#)

<sup>l</sup>[See Principles of Brain and Spinal Cord Systemic Therapy \(BRAIN-D\).](#)

<sup>m</sup>Treatment with carmustine wafer, reirradiation, or multiple prior systemic therapies, may impact enrollment in some adjuvant clinical trials.

<sup>n</sup>Combination of agents may lead to increased toxicity or radiographic changes.

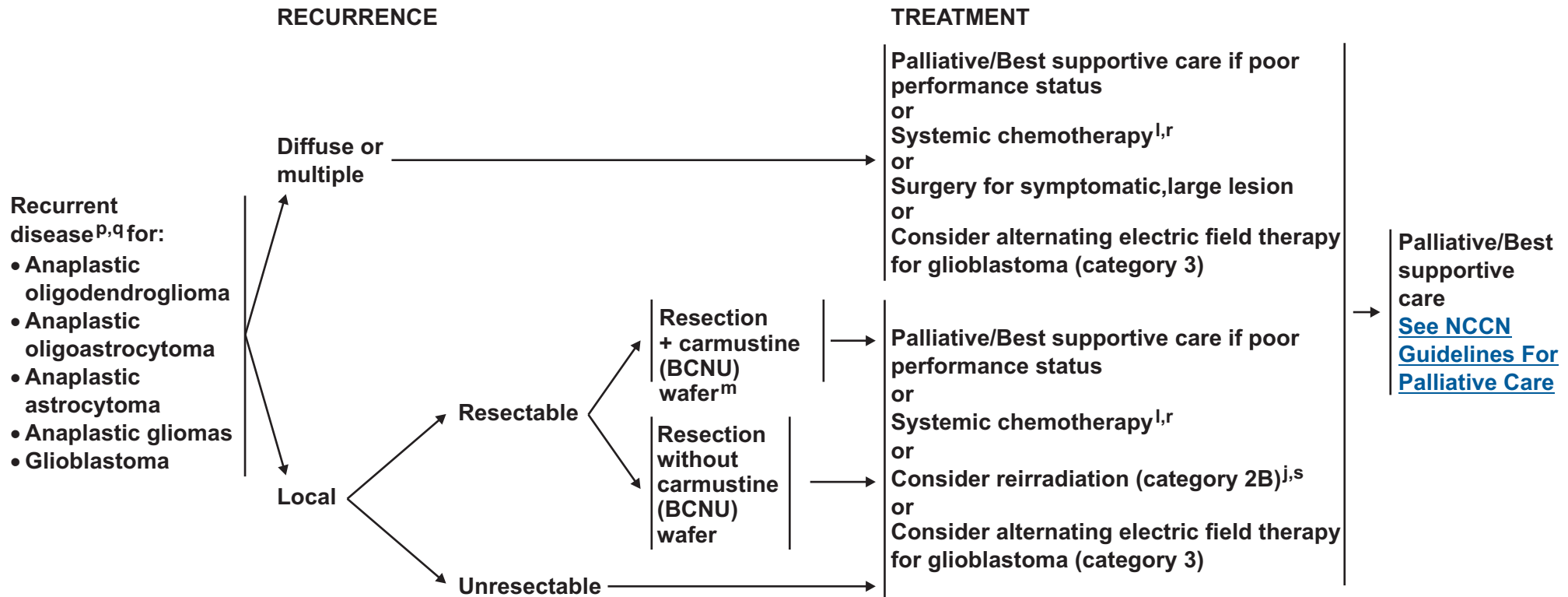
<sup>o</sup>Benefit of treatment with temozolomide for glioblastomas beyond 6 months is unknown. The optimal duration of treatment with temozolomide for anaplastic astrocytoma is unknown.

**Note:** All recommendations are category 2A unless otherwise indicated.

**Clinical Trials:** NCCN believes that the best management of any cancer patient is in a clinical trial. Participation in clinical trials is especially encouraged.



# NCCN Guidelines Version 2.2014 Anaplastic Gliomas/Glioblastoma<sup>a</sup>



<sup>a</sup>This pathway includes the classification of mixed anaplastic oligoastrocytoma (AOA), anaplastic astrocytoma (AA), anaplastic oligodendroglioma (AO), and other rare anaplastic gliomas.

<sup>j</sup>See [Principles of Brain Tumor Radiation Therapy \(BRAIN-C\)](#).

<sup>l</sup>See [Principles of Brain and Spinal Cord Systemic Therapy \(BRAIN-D\)](#).

<sup>m</sup>Treatment with carmustine wafer, reirradiation, or multiple prior systemic therapies, may impact enrollment in some adjuvant clinical trials.

<sup>p</sup>Consider MR spectroscopy, MR perfusion, or brain PET to rule out radiation necrosis.

<sup>q</sup>Within the first 3 months after completion of RT and concomitant temozolomide, diagnosis of recurrence can be indistinguishable from pseudoprogression on neuroimaging. With pseudoprogression, stabilization or improvement should be expected within 3 mo of the end of radiotherapy.

<sup>r</sup>Anaplastic oligodendrogliomas have been reported to be especially sensitive to chemotherapy. Chemotherapy using temozolomide or nitrosourea-based regimens may be appropriate.

<sup>s</sup>Especially if long interval since prior RT and/or if there was a good response to prior RT.

**Note:** All recommendations are category 2A unless otherwise indicated.

**Clinical Trials:** NCCN believes that the best management of any cancer patient is in a clinical trial. Participation in clinical trials is especially encouraged.

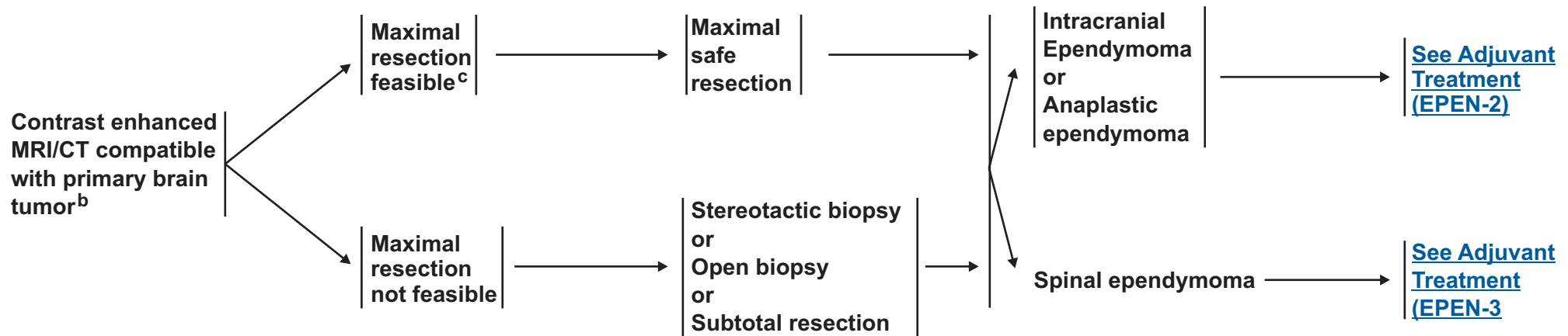


**RADIOLOGIC  
PRESENTATION<sup>a</sup>**

**CLINICAL  
IMPRESSION**

**SURGERY<sup>d</sup>**

**PATHOLOGY**



<sup>a</sup>[See Principles of Brain Tumor Imaging \(BRAIN-A\).](#)

<sup>b</sup>Consider a multidisciplinary review in treatment planning, especially once pathology is available ([See Principles of Brain Tumor Management \[BRAIN-E\]](#)).

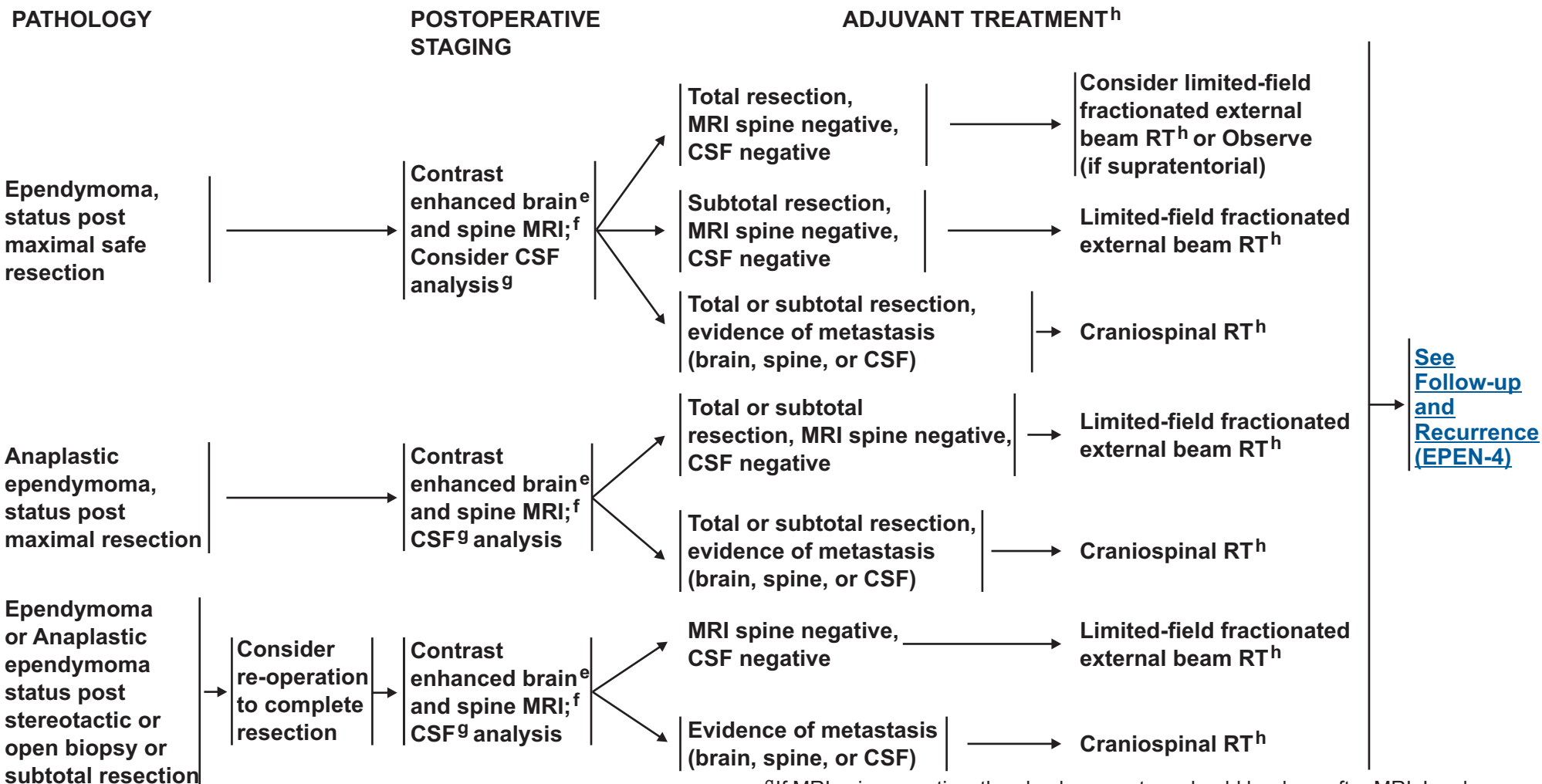
<sup>c</sup>If image-confirmed GTR not achieved, consider multidisciplinary review and resection.

<sup>d</sup>[See Principles of Brain Tumor Surgery \(BRAIN-B\).](#)

**Note:** All recommendations are category 2A unless otherwise indicated.  
**Clinical Trials:** NCCN believes that the best management of any cancer patient is in a clinical trial. Participation in clinical trials is especially encouraged.



### INTRACRANIAL EPENDYMOMA



<sup>e</sup>Within 24-72 hours.

<sup>f</sup>Spine MRI should be delayed by at least 2-3 weeks post surgery to avoid post surgical artifacts.

<sup>g</sup>If MRI spine negative, then lumbar puncture should be done after MRI. Lumbar puncture for CSF should be delayed at least 2 weeks after surgery to avoid possible false positive cytology. Lumbar puncture may be contraindicated (eg, posterior fossa mass).

<sup>h</sup>See [Principles of Brain Tumor Radiation Therapy \(BRAIN-C\)](#).

**Note:** All recommendations are category 2A unless otherwise indicated.

**Clinical Trials:** NCCN believes that the best management of any cancer patient is in a clinical trial. Participation in clinical trials is especially encouraged.



### SPINAL EPENDYMOMA

#### PATHOLOGY

#### POSTOPERATIVE STAGING

#### ADJUVANT TREATMENT<sup>h</sup>

Ependymoma, status post maximal safe resection (Grades I and II)

Contrast enhanced brain<sup>i</sup> and spine MRI; Consider CSF analysis<sup>j</sup>

Total resection, MRI brain and spine negative, CSF negative

Observe<sup>k</sup>

Subtotal resection, MRI brain negative, CSF negative

Limited-field fractionated external beam RT<sup>h</sup>

Total or subtotal resection, evidence of metastasis (brain, spine, or CSF)

Craniospinal RT<sup>h</sup>

Anaplastic ependymoma, status post maximal safe resection

Contrast enhanced brain<sup>i</sup> and spine MRI; CSF<sup>g</sup> analysis

Total or subtotal resection, MRI negative, CSF negative

Limited-field fractionated external beam RT<sup>h</sup>

Total or subtotal resection, evidence of metastasis (brain, spine, or CSF)

Craniospinal RT<sup>h</sup>

[See Follow-up and Recurrence \(EPEN-4\)](#)

<sup>h</sup>See Principles of Brain Tumor Radiation Therapy (BRAIN-C).

<sup>i</sup>Brain MRI to determine if spine tumor is drop metastases from brain.

<sup>j</sup>Lumbar puncture for CSF should be delayed at least 2 weeks after surgery to avoid possible false positive cytology. Lumbar puncture may be contraindicated (eg, posterior fossa mass).

<sup>k</sup>Consider limited field fractionated external beam if myxopapillary ependymoma.

**Note:** All recommendations are category 2A unless otherwise indicated.

**Clinical Trials:** NCCN believes that the best management of any cancer patient is in a clinical trial. Participation in clinical trials is especially encouraged.

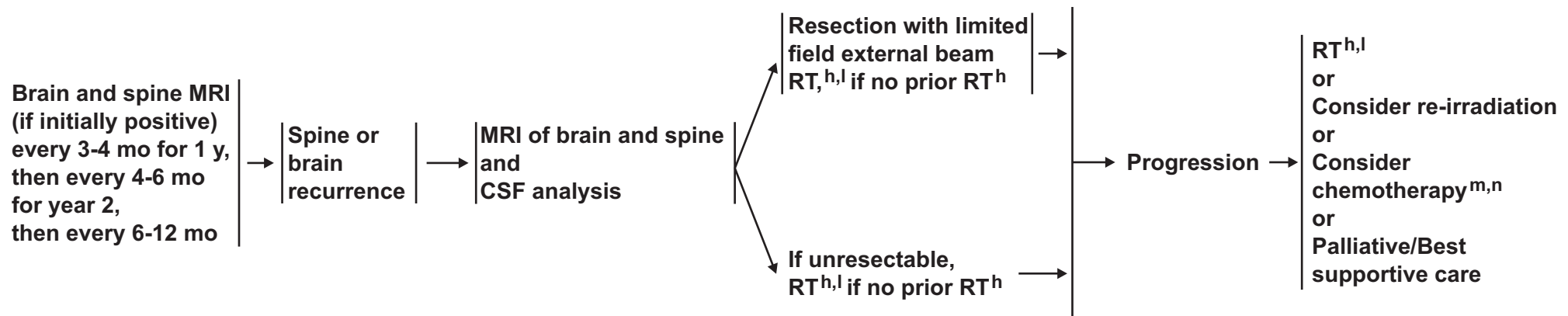


**FOLLOW-UP<sup>a</sup>**

**RECURRENCE**

**CLINICAL STAGING**

**TREATMENT FOR PROGRESSION**



<sup>a</sup>See [Principles of Brain Tumor Imaging \(BRAIN-A\)](#).

<sup>h</sup>See [Principles of Brain Tumor Radiation Therapy \(BRAIN-C\)](#).

<sup>l</sup>Consider stereotactic radiosurgery (SRS) if geometrically favorable.

<sup>m</sup>Chemotherapy should be reserved for patients who are refractory to surgery or radiation.

<sup>n</sup>See [Principles of Brain and Spinal Cord Systemic Therapy \(BRAIN-D\)](#).

**Note:** All recommendations are category 2A unless otherwise indicated.  
**Clinical Trials:** NCCN believes that the best management of any cancer patient is in a clinical trial. Participation in clinical trials is especially encouraged.



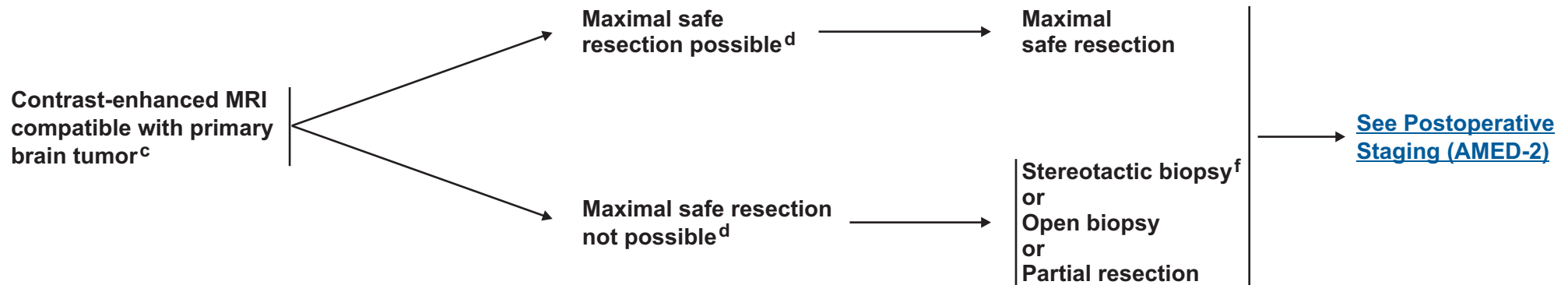
# NCCN Guidelines Version 2.2014

## Adult Medulloblastoma and Supratentorial PNET<sup>a</sup>

### RADIOLOGIC PRESENTATION<sup>b</sup>

### CLINICAL IMPRESSION

### SURGERY<sup>e</sup>



<sup>a</sup>Excluding esthesioneuroblastoma.

<sup>b</sup>[See Principles of Brain Tumor Imaging \(BRAIN-A\).](#)

<sup>c</sup>Consider a multidisciplinary review in treatment planning, before surgery and once pathology is available ([See Principles of Brain Tumor Management \(BRAIN-E\).](#))

<sup>d</sup>Placement of ventriculoperitoneal (VP) shunt for management of hydrocephalus is acceptable if needed.

<sup>e</sup>[See Principles of Brain Tumor Surgery \(BRAIN-B\).](#)

<sup>f</sup>Strongly recommend referring patient to a brain tumor center to be evaluated for possible further, more complete surgical resection.

**Note:** All recommendations are category 2A unless otherwise indicated.

**Clinical Trials:** NCCN believes that the best management of any cancer patient is in a clinical trial. Participation in clinical trials is especially encouraged.



# NCCN Guidelines Version 2.2014

## Adult Medulloblastoma and Supratentorial PNET<sup>a</sup>

### POSTOPERATIVE STAGING

Contrast-enhanced  
brain<sup>g</sup>  
and spine MRI<sup>h</sup>  
CSF analysis<sup>i,j</sup>

**Standard risk for recurrence:<sup>k</sup>**

- No evidence of metastasis (brain, spine, CSF, extraneural)
- Small volume residual disease (contrast volume < 1.5 cm<sup>2</sup>)
- Classic or desmoplastic histology

**High risk for recurrence:<sup>k</sup>**

- Unresectable tumor<sup>l</sup> or residual tumor > 1.5 cm<sup>2</sup>
- Disseminated disease within or outside of the neuroaxis
- Large cell/anaplastic medulloblastoma
- or
- Supratentorial PNET<sup>a</sup>

### ADJUVANT TREATMENT

Craniospinal radiation<sup>m</sup>  
or  
Craniospinal RT<sup>m</sup> with chemotherapy<sup>n</sup>  
followed by  
post-radiation chemotherapy<sup>n,o</sup>

Craniospinal radiation<sup>m</sup> and  
post-radiation chemotherapy<sup>p,q</sup>

[See Follow-up \(AMED-3\)](#)

<sup>a</sup>Excluding esthesioneuroblastoma.

<sup>g</sup>Within 24-72 hours.

<sup>h</sup>Spine MRI should be delayed by at least 2-3 weeks post surgery to avoid post surgical artifacts.

<sup>i</sup>Lumbar puncture should be done after spine MRI. Lumbar puncture for CSF should be delayed at least 2 weeks after surgery to avoid possible false positive cytology.

<sup>j</sup>Bone scan, CT scans of chest, abdomen and pelvis and bone marrow biopsy only if clinically indicated.

<sup>k</sup>See the modified Chang system for staging medulloblastoma. (Chang CH, Housepain EM, Herbert, C. Radiology 1969;93:1351 and Cohen, ME, Duffner, PK (Eds). Brain Tumors in children, 2<sup>nd</sup> ed, McGraw-Hill, New York, 1994, p. 187.)

<sup>l</sup>If only biopsy is possible, consider pre-irradiation chemotherapy followed by an attempt at resection.

<sup>m</sup>[See Principles of Brain Tumor Radiation Therapy \(BRAIN-C\).](#)

<sup>n</sup>Omission of vincristine during radiotherapy phase of therapy or dose modification may be required for adults because they do not tolerate this regimen as well. Data supporting vincristine's use have been found in pediatric trials only. Patients should be closely monitored for neurologic toxicity with periodic exams. (Packer RJ, Gajjar A, Vezina G, et al. Phase III study of craniospinal radiation therapy followed by adjuvant chemotherapy for newly diagnosed average-risk medulloblastoma. J Clin Oncol 2006;24:4202-4208.)

<sup>o</sup>[See Principles of Brain and Spinal Cord Systemic Therapy \(BRAIN-D\).](#)

<sup>p</sup>Recommend a platinum-based chemotherapy regimen such as either of the treatment arms used in the Children's Oncology Group study referenced in footnote o.

<sup>q</sup>Consider collecting stem cells before craniospinal radiation.

**Note:** All recommendations are category 2A unless otherwise indicated.

**Clinical Trials:** NCCN believes that the best management of any cancer patient is in a clinical trial. Participation in clinical trials is especially encouraged.



# NCCN Guidelines Version 2.2014

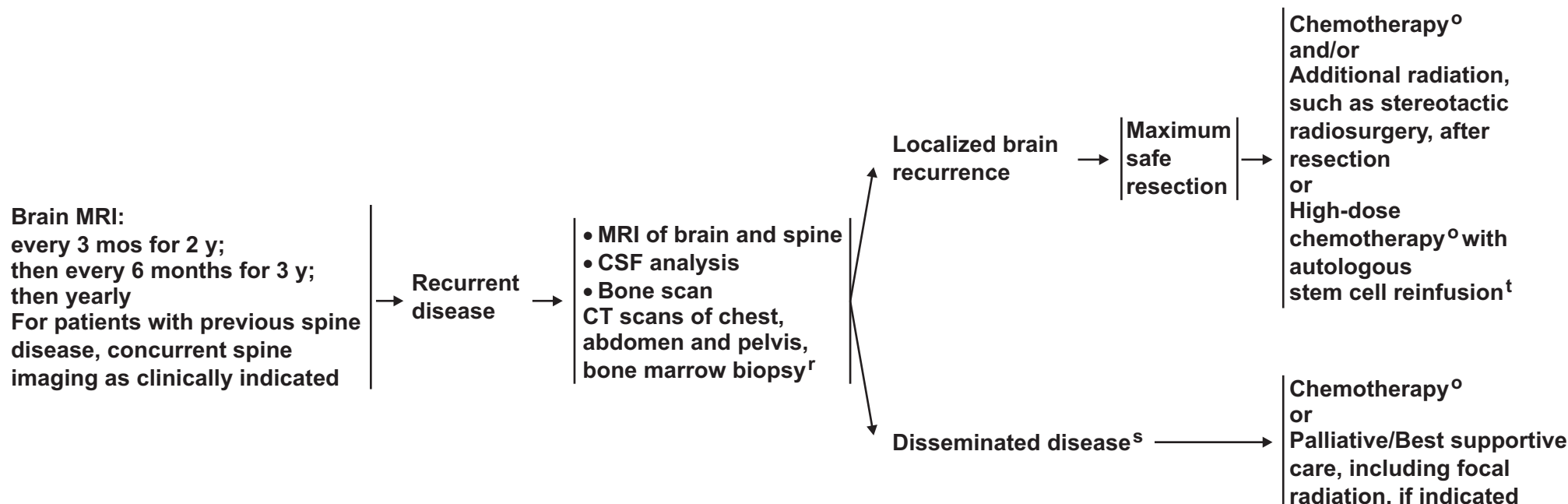
## Adult Medulloblastoma and Supratentorial PNET<sup>a</sup>

### FOLLOW-UP<sup>b</sup>

### RECURRENCE CLINICAL STAGING

### SURGERY

### TREATMENT FOR PROGRESSION



<sup>a</sup>Excluding esthesioneuroblastoma.

<sup>b</sup>[See Principles of Brain Tumor Imaging \(BRAIN-A\).](#)

<sup>o</sup>[See Principles of Brain and Spinal Cord Systemic Therapy \(BRAIN-D\).](#)

<sup>r</sup>If clinically indicated. If patient was treated with radiation only at diagnosis, then a bone scan should be part of restaging imaging at time of recurrence, even if patient is asymptomatic.

<sup>s</sup>Consider resection for palliation of symptoms where indicated.

<sup>t</sup>Only if the patient is without evidence of disease after surgery or conventional dose re-induction chemotherapy.

**Note:** All recommendations are category 2A unless otherwise indicated.

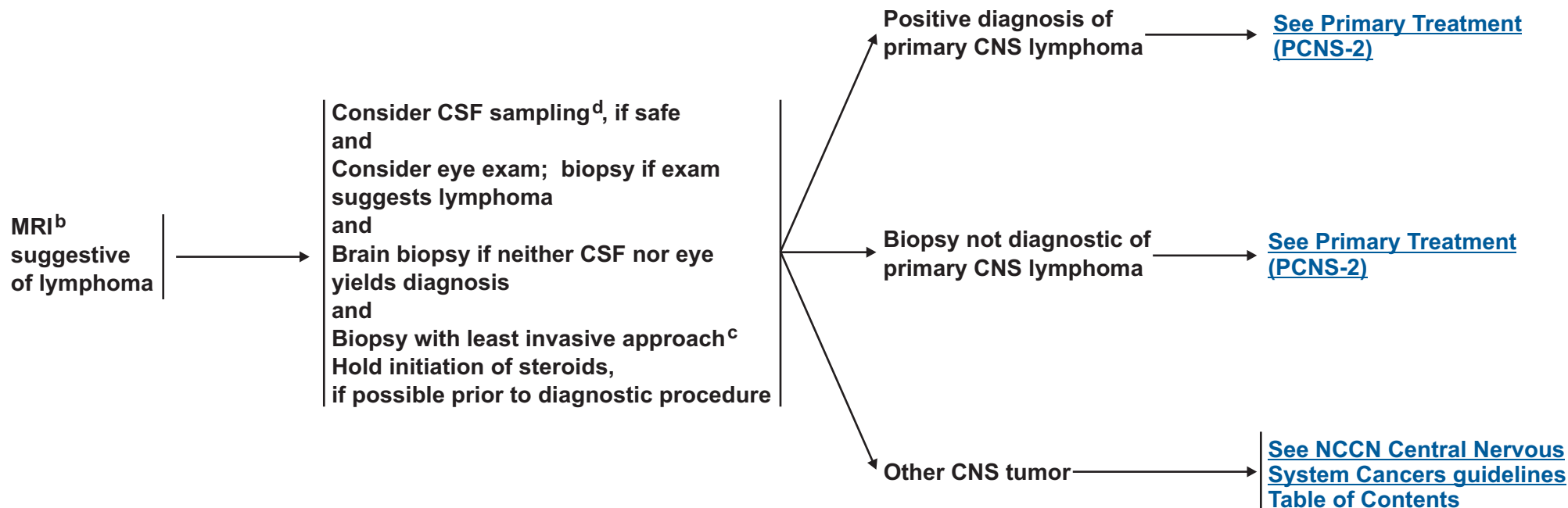
**Clinical Trials:** NCCN believes that the best management of any cancer patient is in a clinical trial. Participation in clinical trials is especially encouraged.



# NCCN Guidelines Version 2.2014

## Primary CNS Lymphoma<sup>a</sup>

### DIAGNOSIS BY TISSUE EVALUATION



<sup>a</sup>If patient is HIV positive, consider highly active antiretroviral therapy.

<sup>b</sup>Contrast CT, if patient cannot have MRI.

<sup>c</sup>If stereotatic biopsy is not available refer to a specialized center.

<sup>d</sup>Tissue sampling and CSF should include flow cytometry, CSF cytology, and may consider gene rearrangements.

**Note:** All recommendations are category 2A unless otherwise indicated.

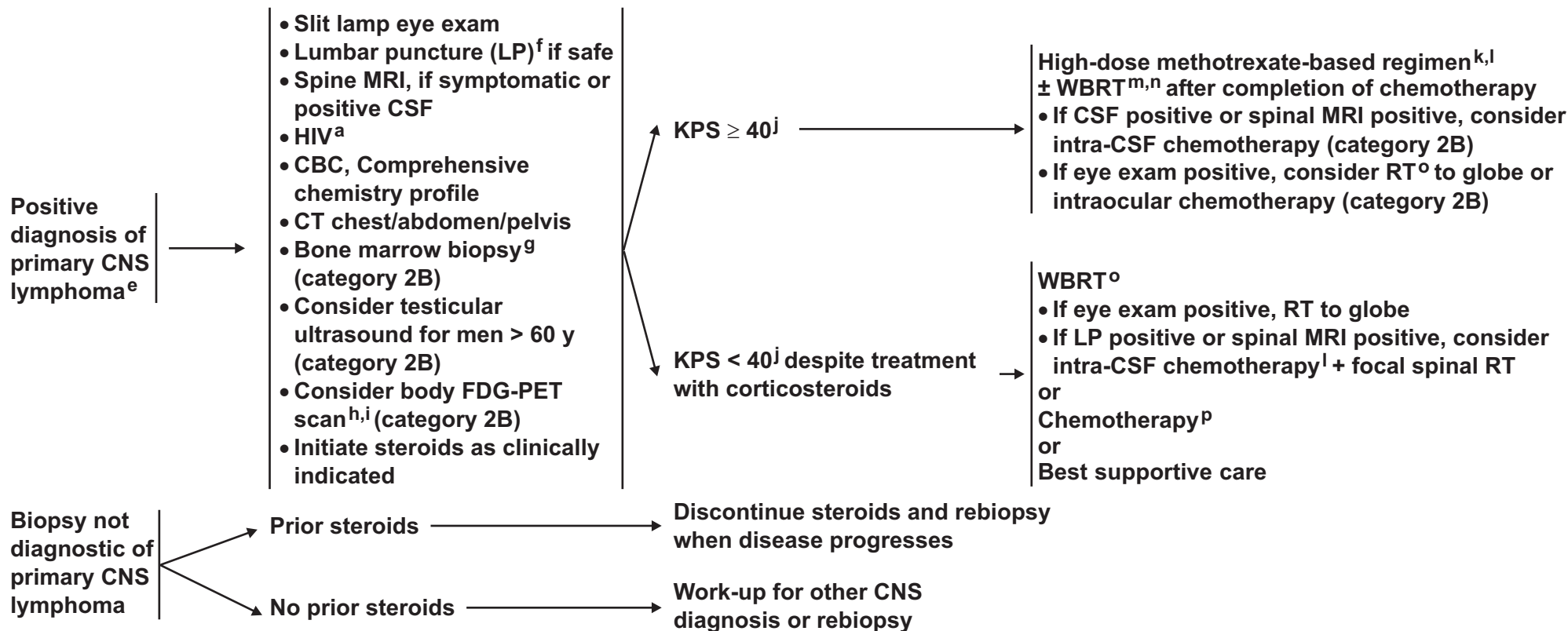
**Clinical Trials:** NCCN believes that the best management of any cancer patient is in a clinical trial. Participation in clinical trials is especially encouraged.



# NCCN Guidelines Version 2.2014

## Primary CNS Lymphoma<sup>a</sup>

### STAGING EVALUATION/WORKUP



<sup>a</sup>If patient is HIV positive, consider highly active antiretroviral therapy.

<sup>e</sup>May institute primary therapy and workup simultaneously.

<sup>f</sup>Caution is indicated in patients who are anticoagulated, thrombocytopenic, or who have a bulky intra-cranial mass.

<sup>g</sup>Some institutions do bone marrow biopsy, however, evidence is lacking.

<sup>h</sup>Body PET scan may replace CT, bone marrow, and testicular ultrasound, but data for its use in Primary CNS lymphoma (PCNSL) is lacking.

<sup>i</sup>For full primary CNS lymphoma staging guidelines, refer to Abrey LE, Batchelor TT, Ferreri AJM, et al. Report of an international workshop to standardize baseline evaluation and response criteria for primary CNS lymphoma. J Clin Oncol 2005;23:5034-5043.

<sup>j</sup>KPS may improve dramatically with steroids. Reassess KPS after initial course of steroids for potential change in therapy.

<sup>k</sup>Dose adjusted for GFR.

<sup>l</sup>[See Principles of Brain and Spinal Cord Systemic Therapy \(BRAIN-D\).](#)

<sup>m</sup>WBRT may increase toxicity, especially in patients > 60 y and may be withheld in the primary setting.

<sup>n</sup>If eye exam positive, monitor carefully for response to treatment. Consider RT to orbits or intraocular chemotherapy.

<sup>o</sup>[See Principles of Brain Tumor Radiation Therapy \(BRAIN-C\).](#)

<sup>p</sup>Consider alternate chemotherapy regimens for patients who cannot tolerate methotrexate.

**Note:** All recommendations are category 2A unless otherwise indicated.

**Clinical Trials:** NCCN believes that the best management of any cancer patient is in a clinical trial. Participation in clinical trials is especially encouraged.

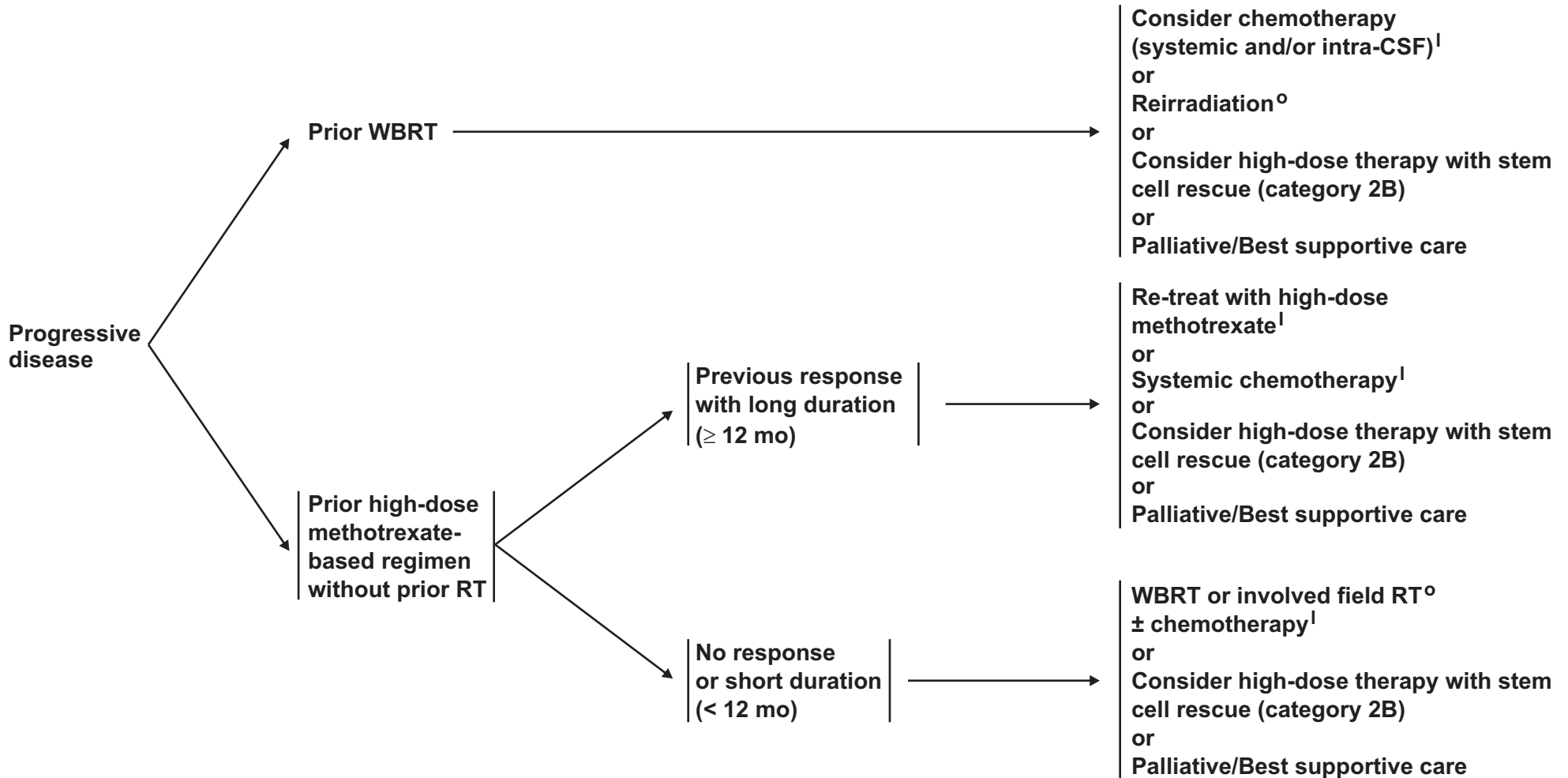


# NCCN Guidelines Version 2.2014

## Primary CNS Lymphoma<sup>a</sup>

### PROGRESSIVE DISEASE

### TREATMENT



<sup>a</sup>If patient is HIV positive, consider highly active antiretroviral therapy.

<sup>1</sup>See [Principles of Brain and Spinal Cord Systemic Therapy \(BRAIN-D\)](#).

<sup>o</sup>See [Principles of Brain Tumor Radiation Therapy \(BRAIN-C\)](#).

**Note:** All recommendations are category 2A unless otherwise indicated.

**Clinical Trials:** NCCN believes that the best management of any cancer patient is in a clinical trial. Participation in clinical trials is especially encouraged.



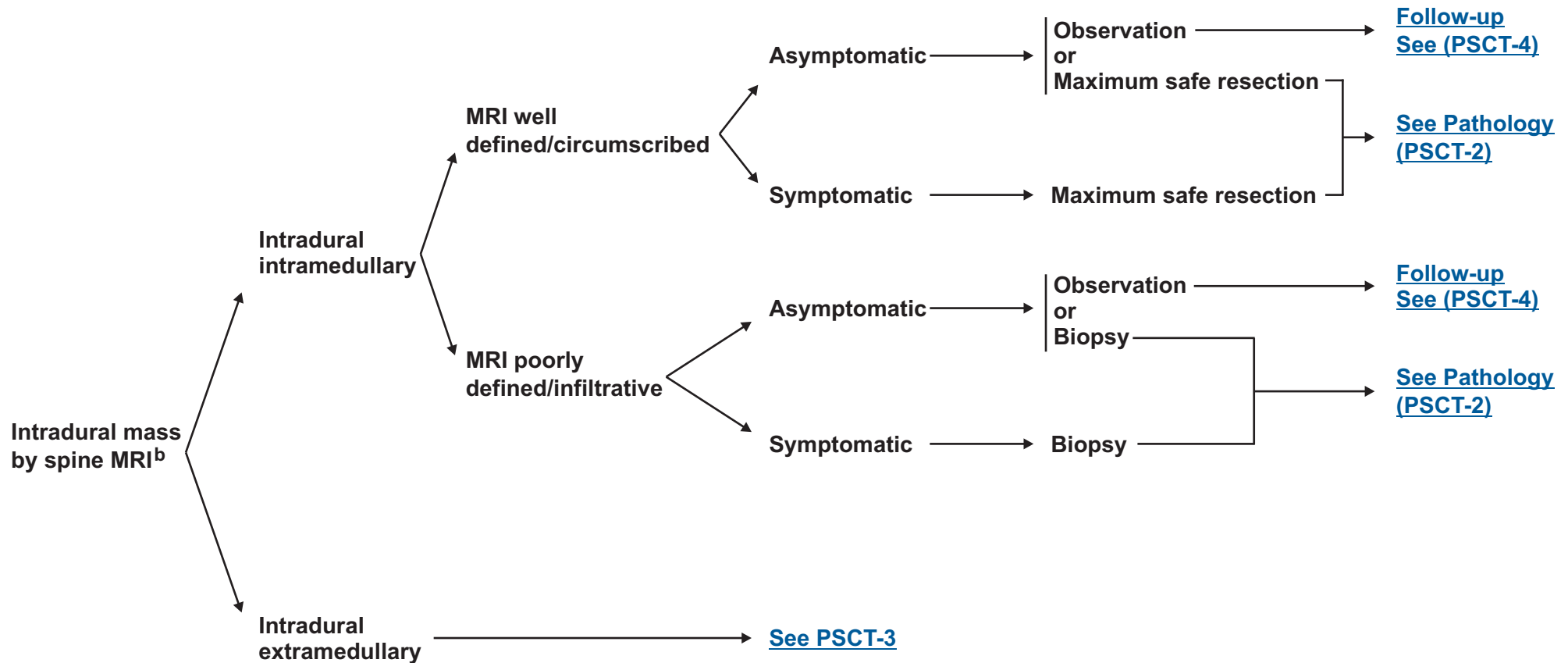
# NCCN Guidelines Version 2.2014

## Primary Spinal Cord Tumors

### RADIOLOGIC PRESENTATION<sup>a</sup>

### CLINICAL PRESENTATION

### SURGERY<sup>c</sup>

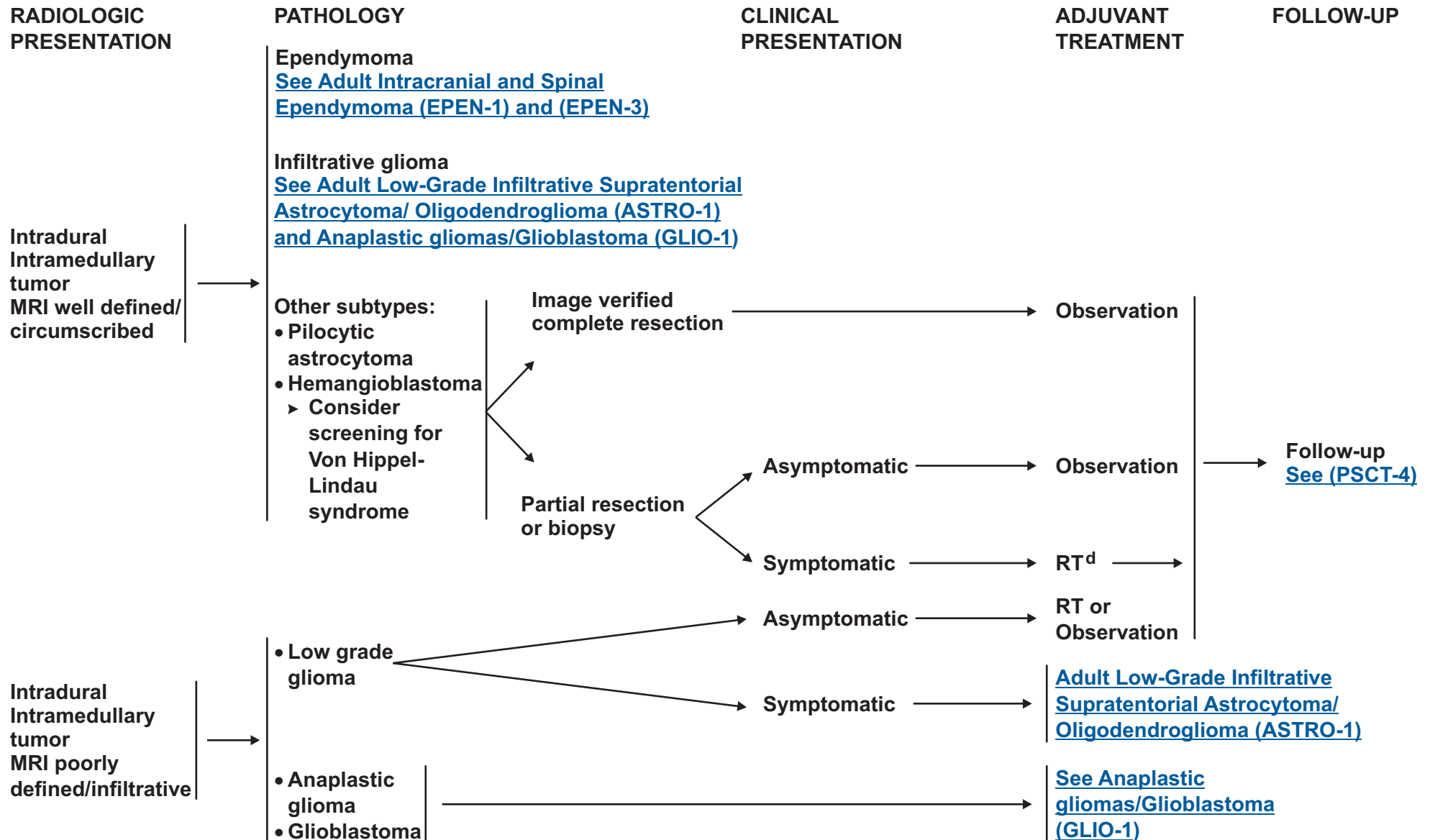


<sup>a</sup> See Principles of Brain Tumor Imaging (BRAIN-A).

<sup>b</sup> Consider a multidisciplinary review in treatment planning, before surgery and once pathology is available (See Principles of Brain Tumor Management [BRAIN-E]).

<sup>c</sup> See Principles of Brain Tumor Surgery (BRAIN-B).

**Note:** All recommendations are category 2A unless otherwise indicated.  
**Clinical Trials:** NCCN believes that the best management of any cancer patient is in a clinical trial. Participation in clinical trials is especially encouraged.



<sup>d</sup>[See Principles of Brain Tumor Radiation Therapy \(BRAIN-C\).](#)

**Note:** All recommendations are category 2A unless otherwise indicated.  
**Clinical Trials:** NCCN believes that the best management of any cancer patient is in a clinical trial. Participation in clinical trials is especially encouraged.



# NCCN Guidelines Version 2.2014

## Primary Spinal Cord Tumors

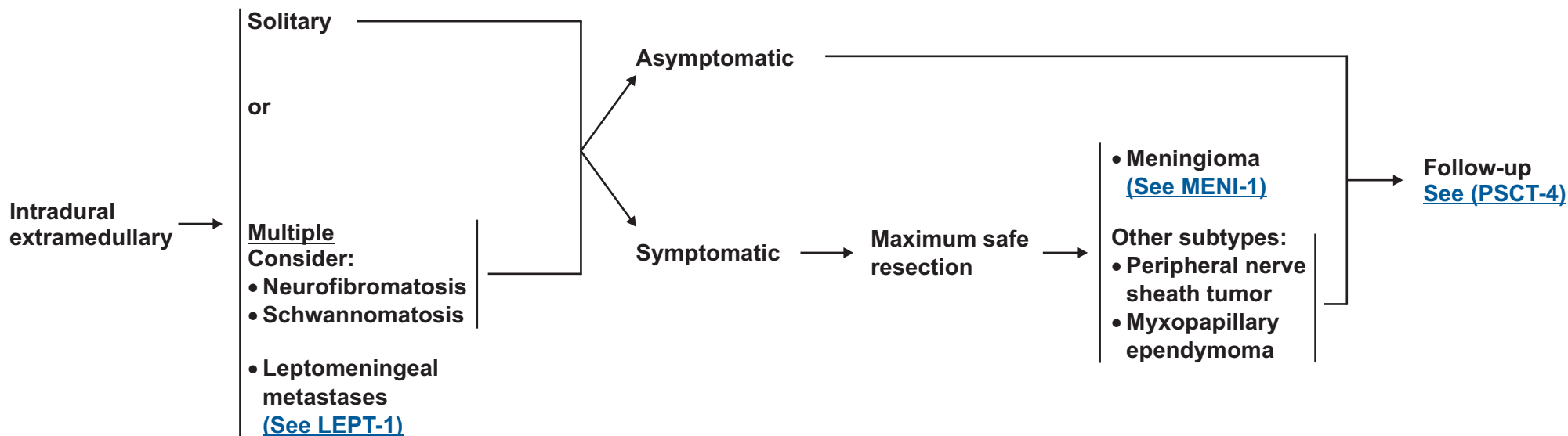
### RADIOLOGIC PRESENTATION

### CLINICAL PRESENTATION

### SURGERY<sup>c</sup>

### PATHOLOGY

### FOLLOW-UP



<sup>c</sup>See Principles of Brain Tumor Surgery (BRAIN-B).

**Note:** All recommendations are category 2A unless otherwise indicated.  
**Clinical Trials:** NCCN believes that the best management of any cancer patient is in a clinical trial. Participation in clinical trials is especially encouraged.



# NCCN Guidelines Version 2.2014

## Primary Spinal Cord Tumors

FOLLOW-UP<sup>a</sup>

RECURRENCE

TREATMENT FOR RECURRENCE

**Patients managed by:**  
Observation  
or  
Maximum safe  
resection for  
intradural  
intramedullary tumor  
or intradural  
extramedullary tumor

→ Sequential MRI →

New or worsening symptoms  
or radiographic progression

→

Re-resection  
or  
RT<sup>d</sup> or re-irradiation (include stereotactic radiotherapy),  
if surgery not possible  
or  
Chemotherapy if further surgery or RT not possible

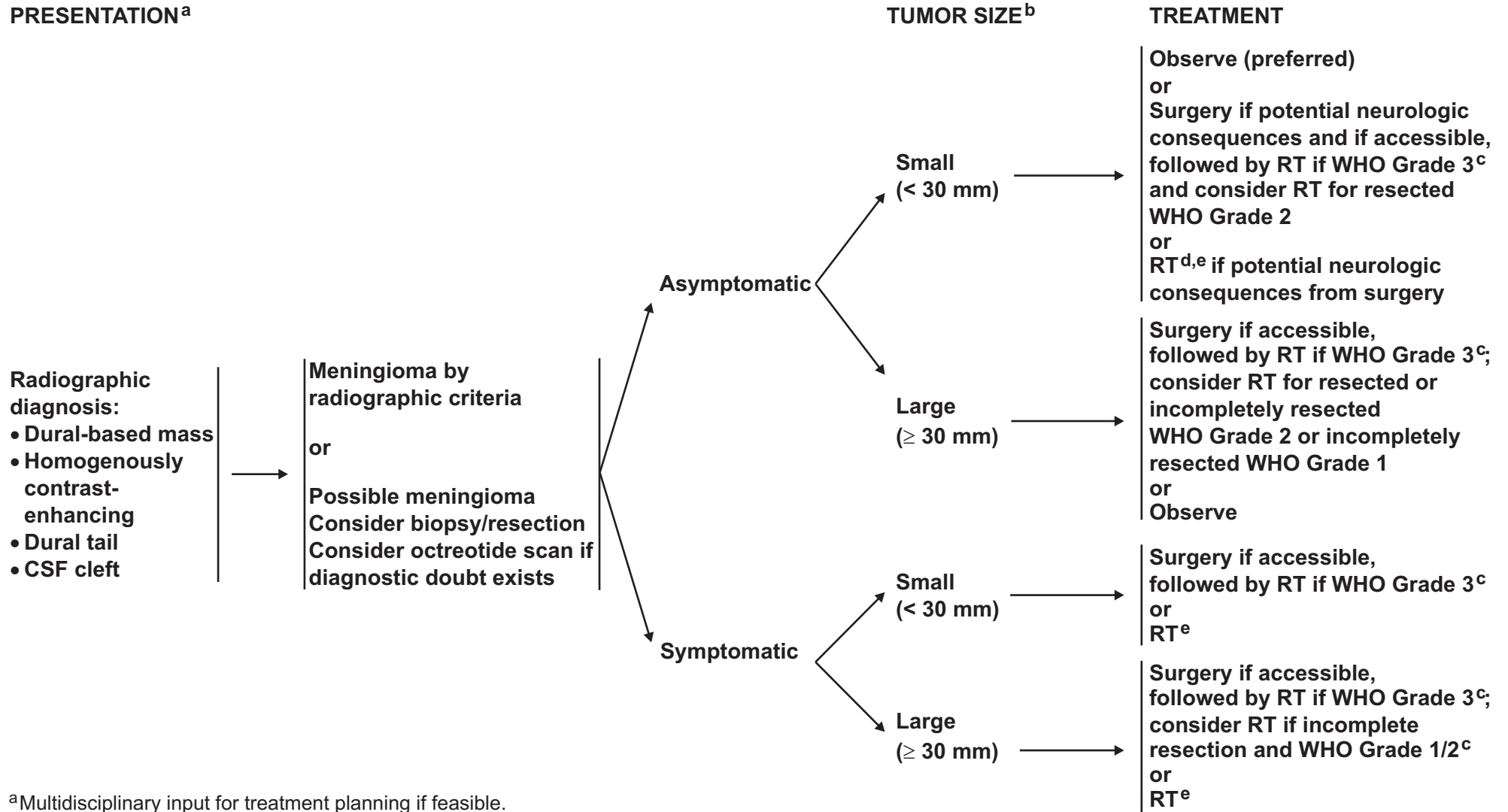
<sup>a</sup>[See Principles of Brain Tumor Imaging \(BRAIN-A\).](#)

<sup>d</sup>[See Principles of Brain Tumor Radiation Therapy \(BRAIN-C\).](#)

**Note:** All recommendations are category 2A unless otherwise indicated.  
**Clinical Trials:** NCCN believes that the best management of any cancer patient is in a clinical trial. Participation in clinical trials is especially encouraged.



### PRESENTATION<sup>a</sup>



<sup>a</sup>Multidisciplinary input for treatment planning if feasible.

<sup>b</sup>The median growth rate for meningiomas is 4mm per annum.

<sup>c</sup>WHO Grade 1 = Benign meningioma, WHO Grade 2 = Atypical meningioma, WHO Grade 3 = Malignant (anaplastic) meningioma

<sup>d</sup>RT can be either external-beam or stereotactic radiosurgery (SRS).

<sup>e</sup>[See Principles of Brain Tumor Radiation Therapy \(BRAIN-C\).](#)

**Note:** All recommendations are category 2A unless otherwise indicated.

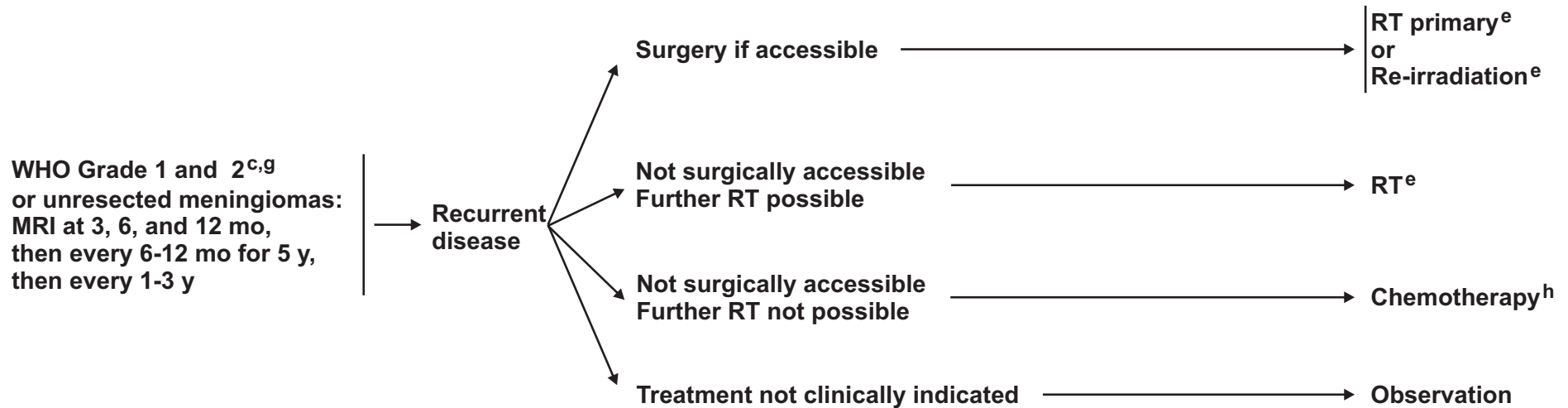
**Clinical Trials:** NCCN believes that the best management of any cancer patient is in a clinical trial. Participation in clinical trials is especially encouraged.



**FOLLOW-UP<sup>f</sup>**

**RECURRENCE/  
PROGRESSION**

**TREATMENT**



<sup>c</sup>WHO Grade 1 = Benign meningioma, WHO Grade 2 = Atypical meningioma, WHO Grade 3 = Malignant (anaplastic) meningioma

<sup>e</sup>[See Principles of Brain Tumor Radiation Therapy \(BRAIN-C\).](#)

<sup>f</sup>Less frequent follow-up after 5-10 y.

<sup>g</sup>More frequent imaging may be required for WHO Grade 3 meningiomas, and for meningioma of any grade that are treated for recurrence or with chemotherapy.

<sup>h</sup>[See Principles of Brain and Spinal Cord Systemic Therapy \(BRAIN-D\).](#)

**Note:** All recommendations are category 2A unless otherwise indicated.

**Clinical Trials:** NCCN believes that the best management of any cancer patient is in a clinical trial. Participation in clinical trials is especially encouraged.

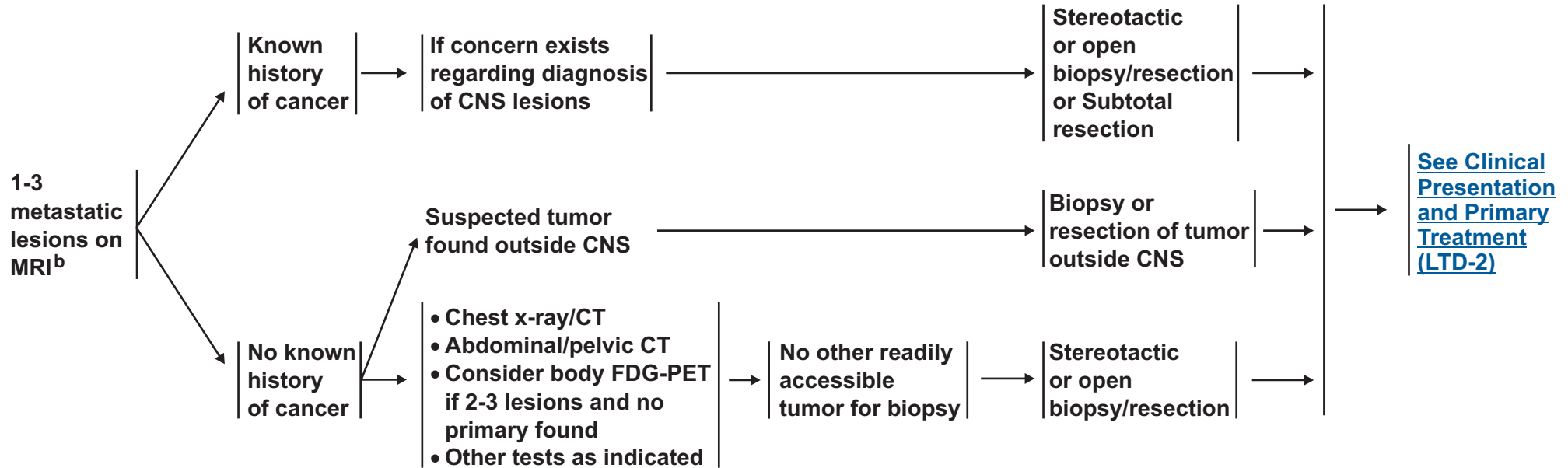


# NCCN Guidelines Version 2.2014

## Limited (1-3) Metastatic Lesions

### CLINICAL PRESENTATION<sup>a</sup>

### WORKUP



<sup>a</sup>[See Principles of Brain Tumor Imaging \(BRAIN-A\).](#)

<sup>b</sup>Consider a multidisciplinary review in treatment planning, especially once pathology is available ([See Principles of Brain Tumor Management \[BRAIN-E\]](#)).

**Note:** All recommendations are category 2A unless otherwise indicated.  
**Clinical Trials:** NCCN believes that the best management of any cancer patient is in a clinical trial. Participation in clinical trials is especially encouraged.

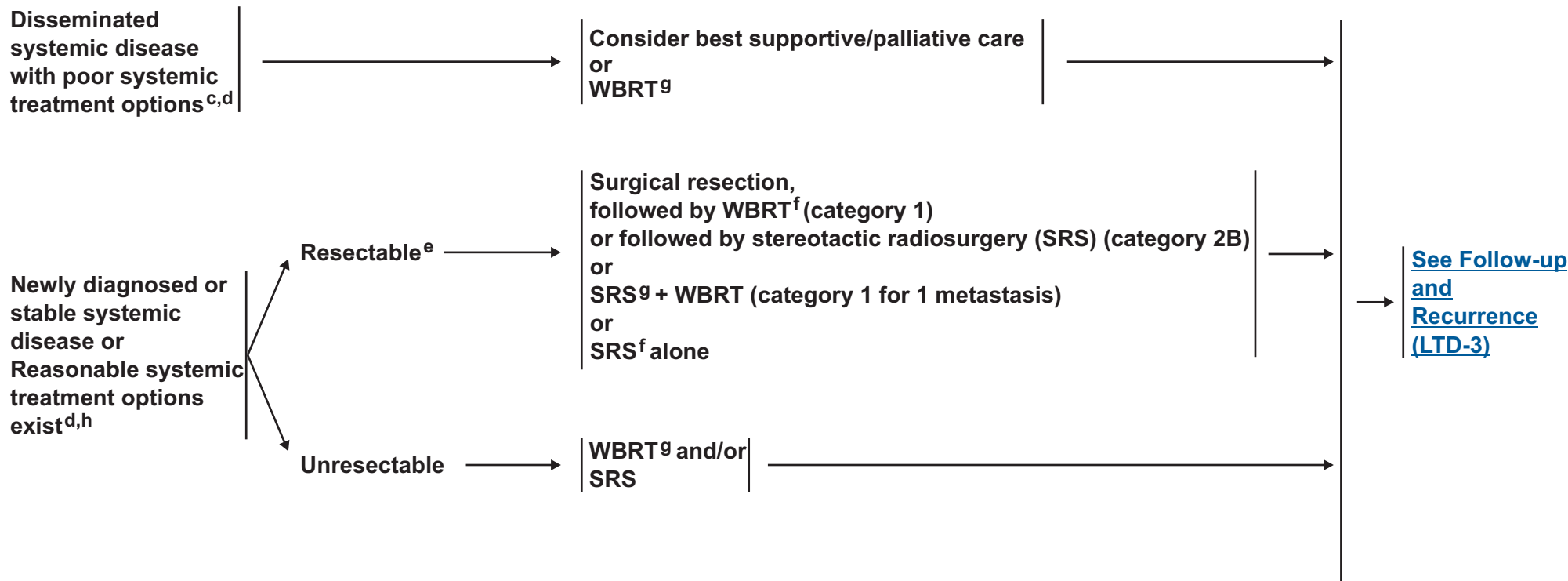


# NCCN Guidelines Version 2.2014

## Limited (1-3) Metastatic Lesions

### CLINICAL PRESENTATION

### PRIMARY TREATMENT<sup>f,g</sup>



<sup>c</sup>Consider surgery to relieve mass effect.

<sup>d</sup>Solid brain metastases with systemic non-primary CNS lymphoma are not well defined, but treatment may include systemic treatment, whole-brain radiotherapy, or focal RT.

<sup>e</sup>The decision to resect a tumor may depend upon the need to establish histologic diagnosis, the size of the lesion, its location, and institutional expertise. For example, smaller (< 2cm), deep, asymptomatic lesions may be considered for treatment with SRS versus larger (> 2 cm), symptomatic lesions that may be more appropriate for surgery. (Ewend MG, Morris DE, Carey LA, Latha AM, Brem S: Guidelines for the initial management of metastatic brain tumors: role of surgery, radiosurgery, and radiation therapy. J Natl Compr Cancer Netw 2008; 6:505-513.)

<sup>f</sup>[See Principles of Brain Tumor Surgery \(BRAIN-B\).](#)

<sup>g</sup>[See Principles of Brain Tumor Radiation Therapy \(BRAIN-C\).](#)

<sup>h</sup>Chemotherapy may be considered in select patients (eg, patients who have asymptomatic brain metastases that are otherwise small and who have not had prior chemotherapy). Treatment as per the regimens of the primary tumor.

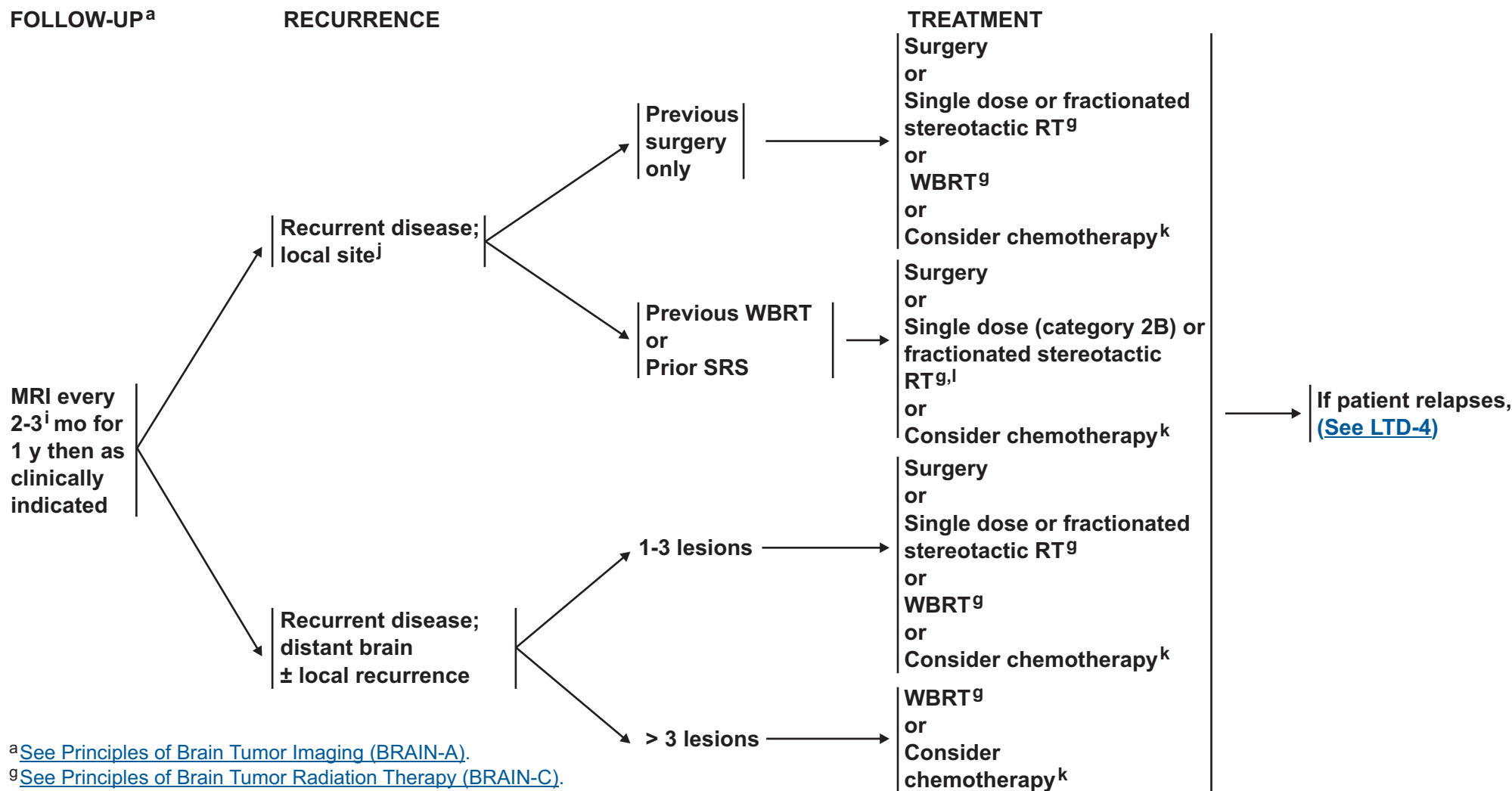
**Note:** All recommendations are category 2A unless otherwise indicated.

**Clinical Trials:** NCCN believes that the best management of any cancer patient is in a clinical trial. Participation in clinical trials is especially encouraged.



# NCCN Guidelines Version 2.2014

## Limited (1-3) Metastatic Lesions



<sup>a</sup>See Principles of Brain Tumor Imaging (BRAIN-A).

<sup>g</sup>See Principles of Brain Tumor Radiation Therapy (BRAIN-C).

<sup>i</sup>MRI every 2 months (instead of 3 mo) for those patients treated with SRS alone.

<sup>j</sup>After stereotactic radiosurgery, recurrence on radiograph can be confounded by treatment effects, consider tumor tissue sampling if there is a high index of suspicion of recurrence.

<sup>k</sup>See Principles of Brain and Spinal Cord Systemic Therapy (BRAIN-D).

<sup>l</sup>If patient had previous SRS with a good response > 6 mo, then reconsider SRS if imaging supports active tumor and not necrosis.

**Note:** All recommendations are category 2A unless otherwise indicated.  
**Clinical Trials:** NCCN believes that the best management of any cancer patient is in a clinical trial. Participation in clinical trials is especially encouraged.

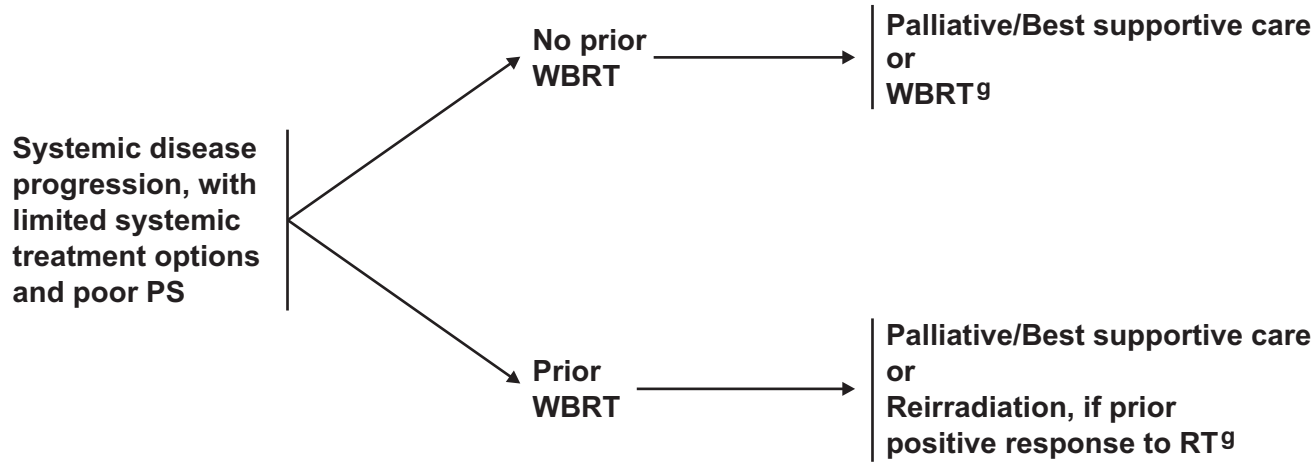


# NCCN Guidelines Version 2.2014

## Limited (1-3) Metastatic Lesions

### RECURRENCE

### TREATMENT



<sup>9</sup>[See Principles of Brain Tumor Radiation Therapy \(BRAIN-C\).](#)

**Note:** All recommendations are category 2A unless otherwise indicated.  
**Clinical Trials:** NCCN believes that the best management of any cancer patient is in a clinical trial. Participation in clinical trials is especially encouraged.



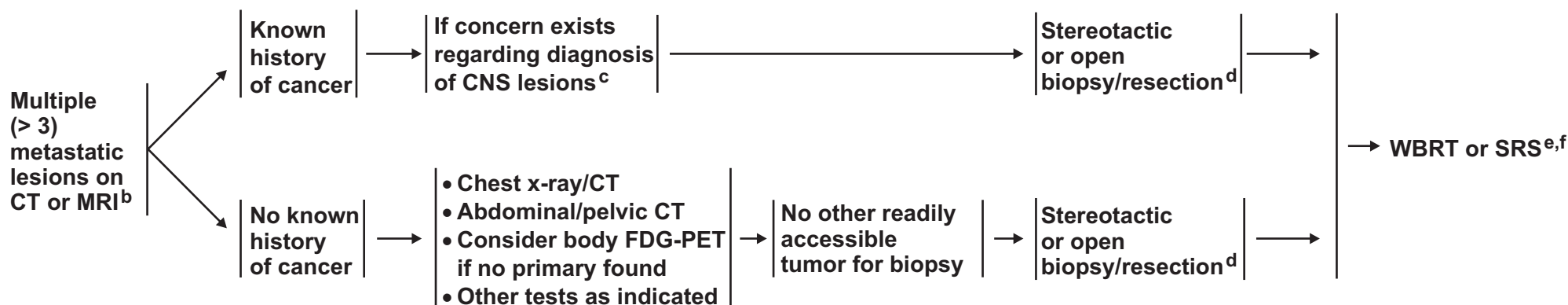
# NCCN Guidelines Version 2.2014

## Multiple (>3) Metastatic Lesions

### CLINICAL PRESENTATION<sup>a</sup>

### WORKUP

### PRIMARY TREATMENT<sup>e</sup>



<sup>a</sup>See [Principles of Brain Tumor Imaging \(BRAIN-A\)](#).

<sup>b</sup>Consider a multidisciplinary review in treatment planning, especially once pathology is available ([See Principles of Brain Tumor Management \[BRAIN-E\]](#)).

<sup>c</sup>As part of diagnostic evaluation, neuroimaging modalities such as MRI, DW-MRI, MRI-SPECT, or PET scan may be considered.

<sup>d</sup>Consider surgery to relieve mass effect.

<sup>e</sup>See [Principles of Brain Tumor Radiation Therapy \(BRAIN-C\)](#).

<sup>f</sup>SRS can be considered for patients with good performance and low overall tumor volume. (Chang WS, Kim HY, Chang JW, et al. Analysis of radiosurgical results in patients with brain metastases according to the number of brain lesions: is stereotactic radiosurgery effective for multiple brain metastases? J Neurosurg 2010;113 Suppl:73-78).

**Note:** All recommendations are category 2A unless otherwise indicated.

**Clinical Trials:** NCCN believes that the best management of any cancer patient is in a clinical trial. Participation in clinical trials is especially encouraged.

[See Follow-up and Recurrence \(MU-2\)](#)



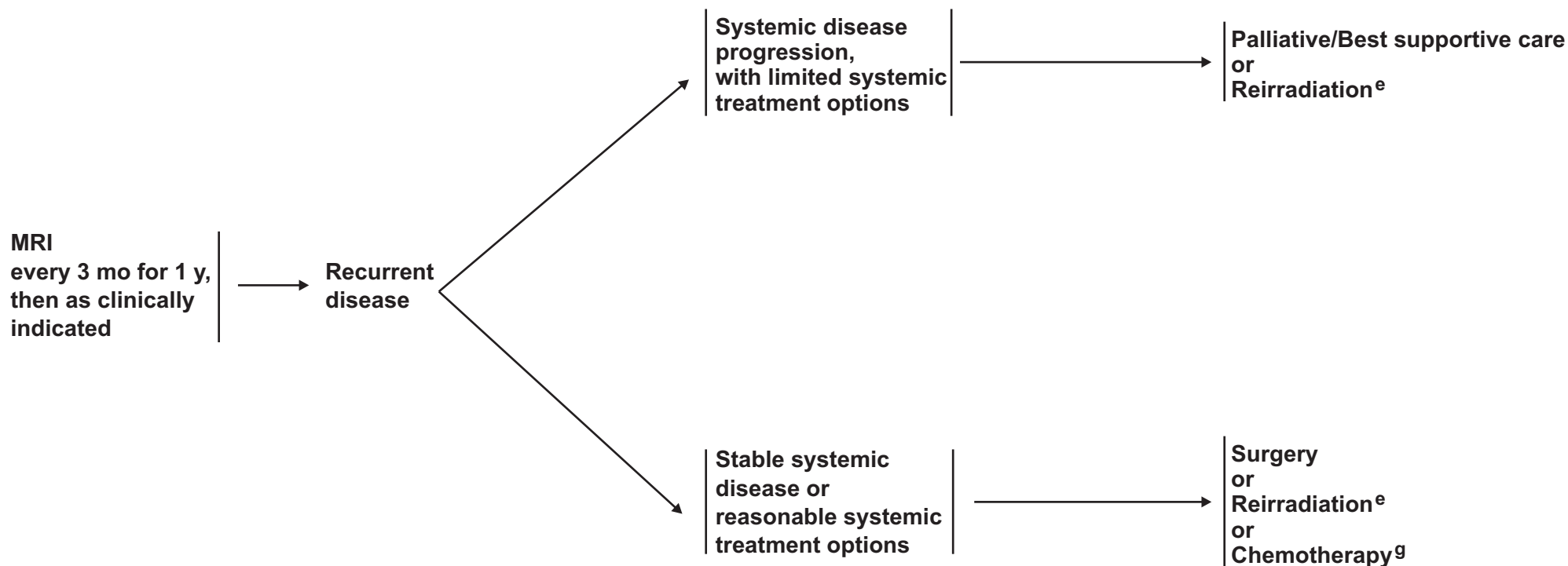
# NCCN Guidelines Version 2.2014

## Multiple (>3) Metastatic Lesions

### FOLLOW-UP<sup>a</sup>

### RECURRENCE

### TREATMENT



<sup>a</sup>[See Principles of Brain Tumor Imaging \(BRAIN-A\).](#)

<sup>e</sup>[See Principles of Brain Tumor Radiation Therapy \(BRAIN-C\).](#)

<sup>g</sup>[See Principles of Brain and Spinal Cord Systemic Therapy \(BRAIN-D\).](#)

**Note:** All recommendations are category 2A unless otherwise indicated.  
**Clinical Trials:** NCCN believes that the best management of any cancer patient is in a clinical trial. Participation in clinical trials is especially encouraged.



# NCCN Guidelines Version 2.2014

## Leptomeningeal Metastases

### WORKUP

### DIAGNOSIS

### RISK STATUS

Signs and symptoms suggestive of leptomeningeal disease<sup>a</sup>

- Physical exam with careful neurologic evaluation
- Brain and spine MRI if patient is a candidate for radiotherapy and/or intra-CSF chemotherapy<sup>b</sup>
- CSF exam<sup>c,d</sup>
- Neuroaxis imaging

- CSF positive for tumor cells<sup>d</sup> or Positive radiologic findings with supportive clinical findings or Signs and symptoms with suggestive CSF<sup>e</sup> in a patient known to have a malignancy

- Poor risk:<sup>f</sup>
- KPS <60
  - Multiple, serious, major neurologic deficits
  - Extensive systemic disease with few treatment options
  - Bulky CNS disease
  - Encephalopathy

- Good risk:
- KPS ≥ 60
  - No major neurologic deficits
  - Minimal systemic disease
  - Reasonable systemic treatment options, if needed

→ [See Treatment \(LEPT-2\)](#)

→ [See Treatment \(LEPT-2\)](#)

<sup>a</sup>Consider a multidisciplinary review in treatment planning, especially once pathology is available ([See Principles of Brain Tumor Management \[BRAIN-E\]](#)).

<sup>b</sup>Intra-CSF chemotherapy includes intrathecal (intralumbar) and intraventricular (intra-Ommaya).

<sup>c</sup>Caution is indicated in patients who are anticoagulated, thrombocytopenic, or who have a bulky intra-cranial mass.

<sup>d</sup>With all malignancies, send for a cell count, differential (including hematopathology review), glucose, and protein. For solid malignancies, CSF analysis utilizes cytopathology. For hematologic malignancies, use flow cytometry.

<sup>e</sup>Suggestive CSF includes high WBC, low glucose, and high protein. If CSF is not positive for tumor cells, a second lumbar puncture is sometimes helpful. This is a volume dependent test and ideally ≥ 10 mL should be sent for cytologic analysis.

<sup>f</sup>Patients with exceptionally chemosensitive tumors (eg, small cell lung cancer, lymphoma) may be treated.

**Note:** All recommendations are category 2A unless otherwise indicated.

**Clinical Trials:** NCCN believes that the best management of any cancer patient is in a clinical trial. Participation in clinical trials is especially encouraged.



# NCCN Guidelines Version 2.2014

## Leptomeningeal Metastases

### RISK STATUS

### TREATMENT

#### Poor risk:<sup>f</sup>

- KPS <60
- Multiple, serious, major neurologic deficits
- Extensive systemic disease with few treatment options
- Bulky CNS disease
- Encephalopathy



Consider fractionated external beam RT<sup>g</sup> to symptomatic sites<sup>h</sup>  
and  
Palliative/Best supportive care

#### Good risk:

- KPS ≥60
- No major neurologic deficits
- Minimal systemic disease
- Reasonable systemic treatment options, if needed



Involved field RT<sup>g</sup> to bulky disease, symptomatic sites



[See CSF flow scan \(LEPT-3\)](#)

<sup>f</sup>Patients with exceptionally chemosensitive tumors (eg, SCLC, lymphoma) may be treated.

<sup>g</sup>[See Principles of Brain Tumor Radiation Therapy \(BRAIN-C\).](#)

<sup>h</sup>Usually WBRT and/or partial spine field recommended.

**Note:** All recommendations are category 2A unless otherwise indicated.

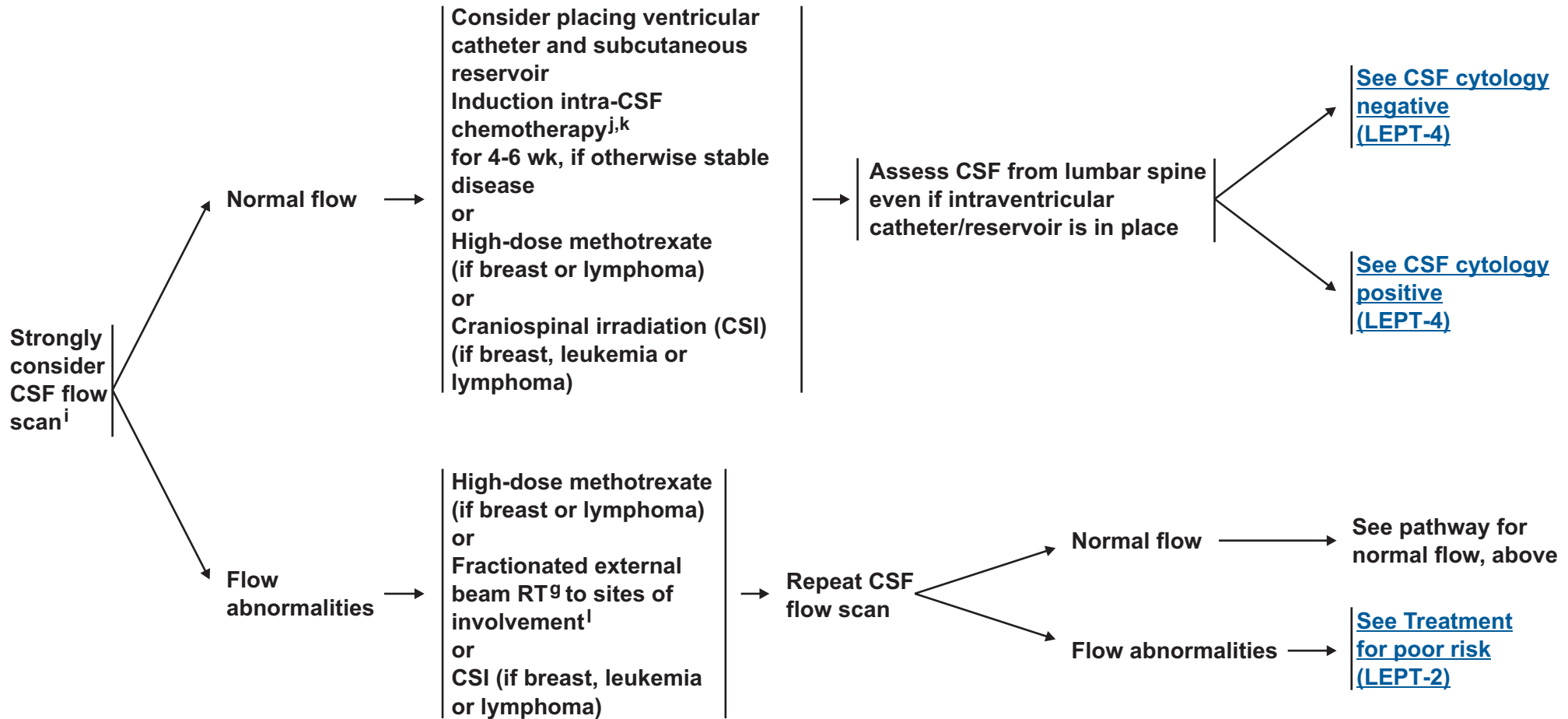
**Clinical Trials:** NCCN believes that the best management of any cancer patient is in a clinical trial. Participation in clinical trials is especially encouraged.



# NCCN Guidelines Version 2.2014

## Leptomeningeal Metastases

### PRIMARY TREATMENT



<sup>g</sup>See [Principles of Brain Tumor Radiation Therapy \(BRAIN-C\)](#).

<sup>i</sup>Highly recommended to ensure patency of CSF flow if intraventricular catheter was placed.

<sup>j</sup>See [Principles of Brain and Spinal Cord Systemic Therapy \(BRAIN-D\)](#).

<sup>k</sup>Induction intra-CSF chemotherapy can start with radiation (concomitant) or high-dose methotrexate for lymphoma or CSI.

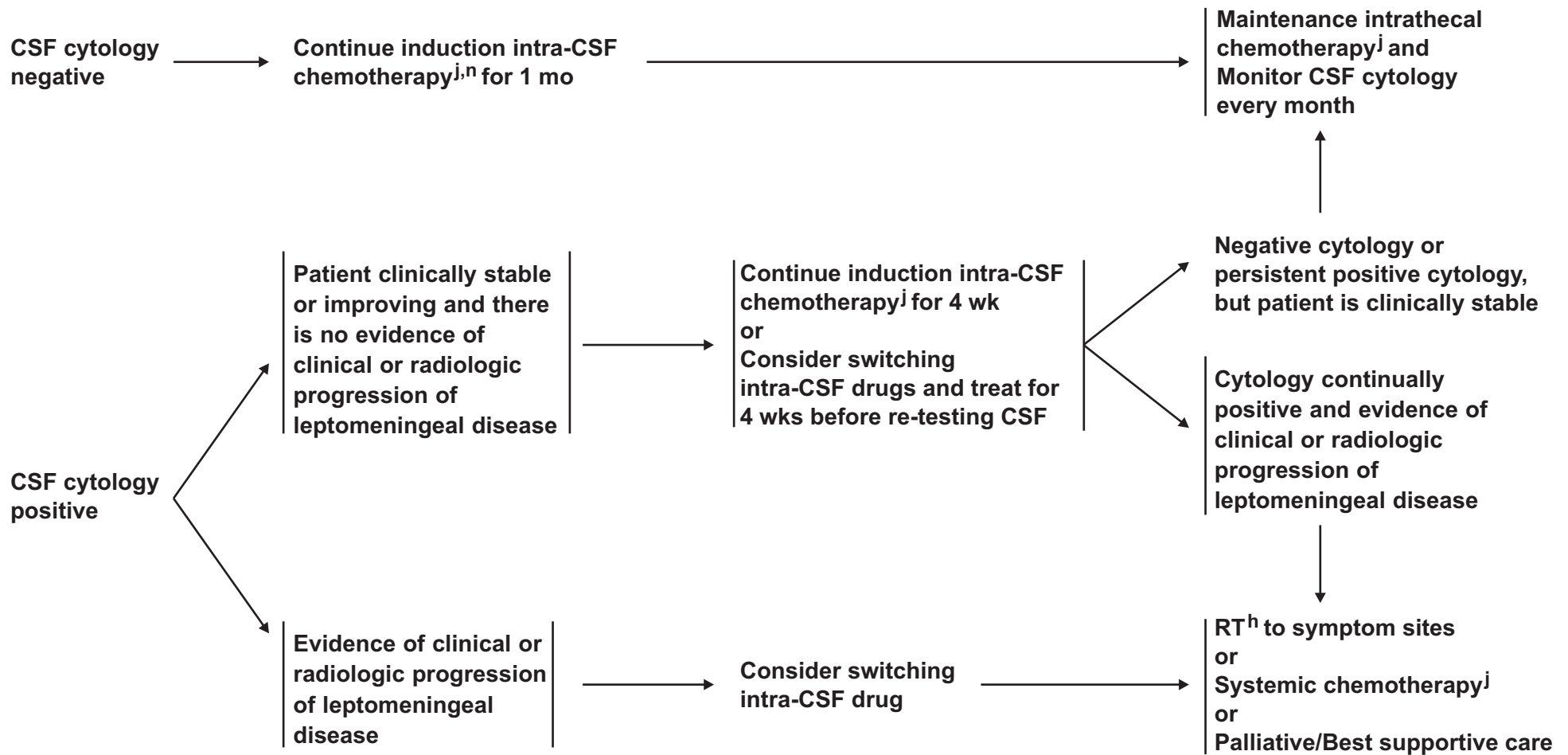
<sup>l</sup>Usually WBRT and/or partial spine field recommended.

**Note:** All recommendations are category 2A unless otherwise indicated.

**Clinical Trials:** NCCN believes that the best management of any cancer patient is in a clinical trial. Participation in clinical trials is especially encouraged.



### POSTINDUCTION THERAPY<sup>m</sup>



<sup>g</sup>See Principles of Brain Tumor Radiation Therapy (BRAIN-C).

<sup>j</sup>See Principles of Brain and Spinal Cord Systemic Therapy (BRAIN-D).

<sup>m</sup>After completion of induction, consider neuroaxis imaging to assess sites that were previously radiographically positive.

<sup>n</sup>Induction intra-CSF chemotherapy can start with radiation (concomitant) or high-dose methotrexate for lymphoma or CSI.

**Note:** All recommendations are category 2A unless otherwise indicated.

**Clinical Trials:** NCCN believes that the best management of any cancer patient is in a clinical trial. Participation in clinical trials is especially encouraged.



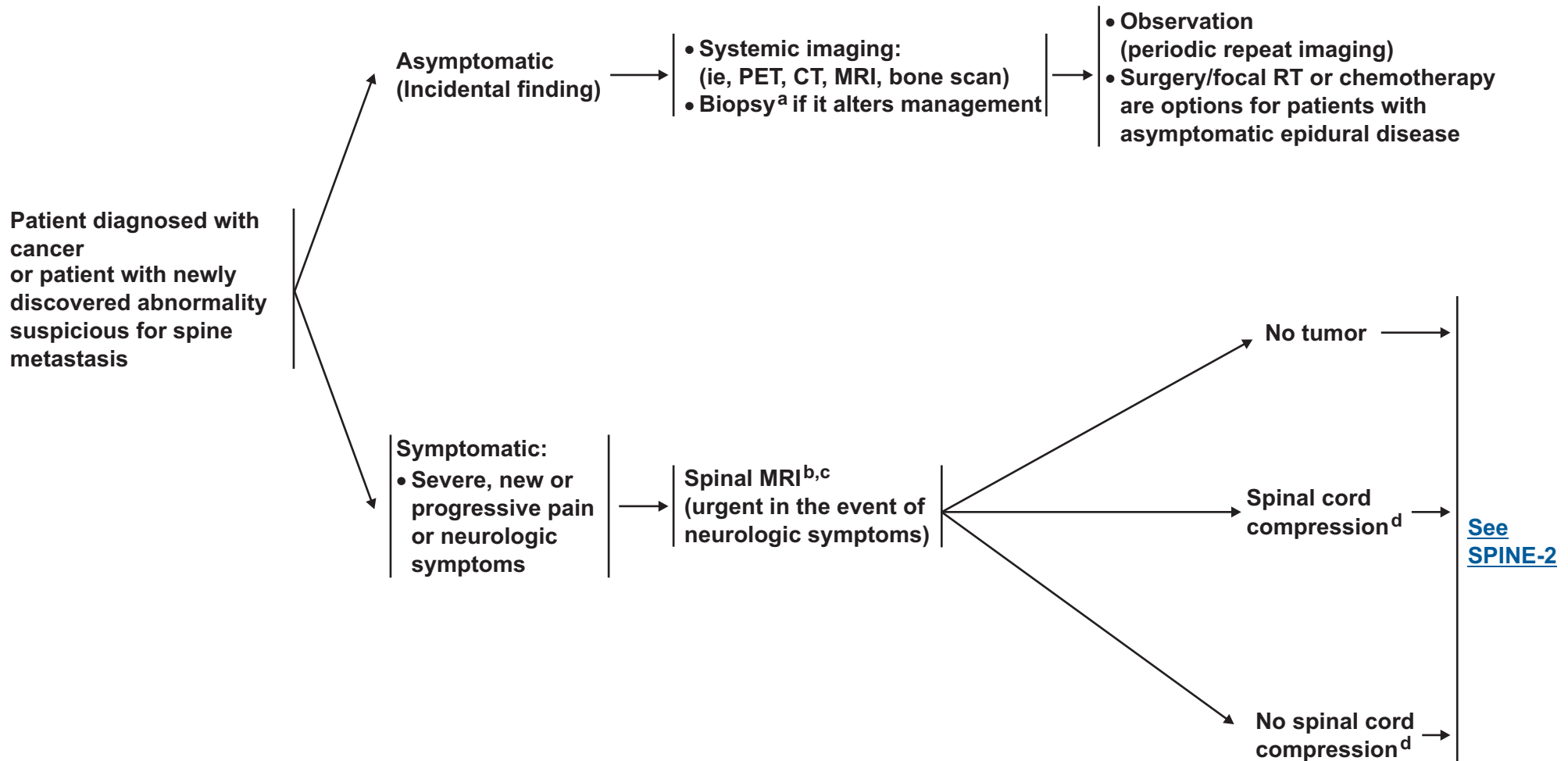
# NCCN Guidelines Version 2.2014

## Metastatic Spine Tumors

### PRESENTATION

### WORKUP

### TREATMENT



<sup>a</sup>Biopsy if remote history of cancer.

<sup>b</sup>If the patient is unable to have an MRI, then a CT myelogram is recommended.

<sup>c</sup>15-20% of patients have additional lesions. Highly recommend complete spine imaging.

<sup>d</sup>Includes cauda equina syndrome.

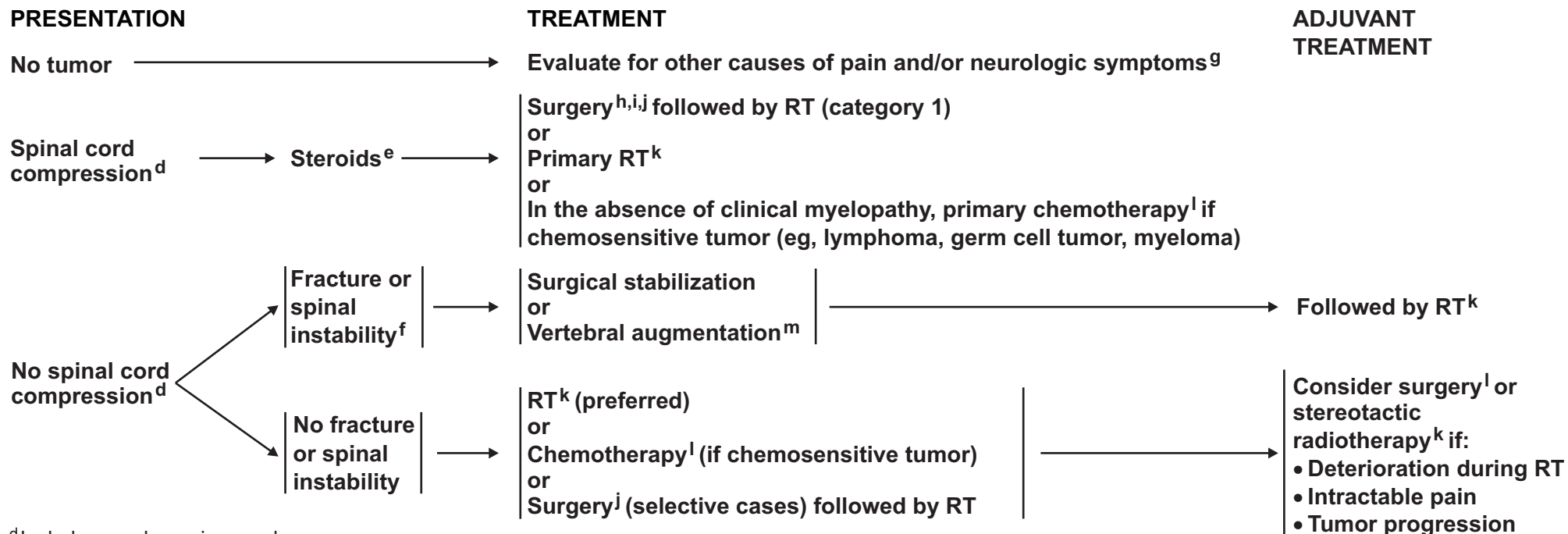
**Note:** All recommendations are category 2A unless otherwise indicated.

**Clinical Trials:** NCCN believes that the best management of any cancer patient is in a clinical trial. Participation in clinical trials is especially encouraged.



# NCCN Guidelines Version 2.2014

## Metastatic Spine Tumors



<sup>d</sup>Includes cauda equina syndrome.

<sup>e</sup>The recommended minimum dose of steroids is 4 mg of dexamethasone every 6 hours, although dose of steroids may vary (10-100 mg). A randomized trial supported the use of high-dose steroids (Sorensen PS, et al. Eur J Cancer 1994;30A:22-27).

<sup>f</sup>Spinal instability is grossly defined as the presence of significant kyphosis or subluxation (deformity), or of significantly retropulsed bone fragment.

<sup>g</sup>Consider alternative diagnosis of leptomeningeal disease ([See LEPT-1](#))

<sup>h</sup>Tumor resection with or without spinal stabilization. Surgery should be focused on anatomic pathology.

<sup>i</sup>Regarding surgery, note the following:

- Category 1 evidence supports the role of surgery in patients with a solitary epidural spinal cord compression by a tumor not known to be radiosensitive and who are willing to undergo surgery. (Patchell RA, et al. Lancet 2005;366(9486):643-648)
- For surgery, patients with hematologic tumors (lymphoma, myeloma, leukemia) should be excluded, life expectancy should be ≥ 3 mo, and the patient should not be paraplegic for > 24 h.
- Surgery is especially indicated if the patient has any of the following: spinal instability, no history of cancer, rapid neurologic deterioration during RT, previous RT to site, and single site spinal cord compression.

<sup>j</sup>[See Principles of Brain Tumor Surgery \(BRAIN-B\).](#)

<sup>k</sup>[See Principles of Brain Tumor Radiation Therapy \(BRAIN-C\).](#)

<sup>l</sup>[See Principles of Brain and Spinal Cord Systemic Therapy \(BRAIN-D\).](#)

<sup>m</sup>Vertebral augmentation: vertebroplasty, kyphoplasty.

**Note:** All recommendations are category 2A unless otherwise indicated.

**Clinical Trials:** NCCN believes that the best management of any cancer patient is in a clinical trial. Participation in clinical trials is especially encouraged.



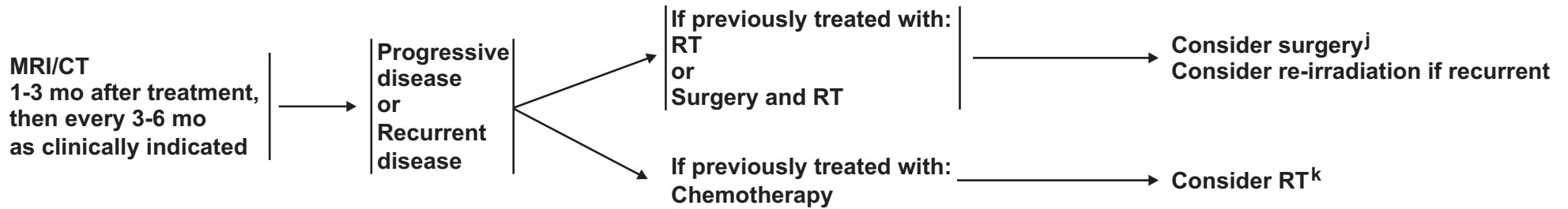
# NCCN Guidelines Version 2.2014

## Metastatic Spine Tumors

### FOLLOW-UP

### PRESENTATION (Symptom or MRI based)

### TREATMENT FOR RECURRENCE OR PROGRESSIVE DISEASE



<sup>j</sup>See Principles of Brain Tumor Surgery (BRAIN-B).

<sup>k</sup>See Principles of Brain Tumor Radiation Therapy (BRAIN-C).

**Note:** All recommendations are category 2A unless otherwise indicated.

**Clinical Trials:** NCCN believes that the best management of any cancer patient is in a clinical trial. Participation in clinical trials is especially encouraged.



### PRINCIPLES OF BRAIN TUMOR IMAGING<sup>1</sup>

- **MRI<sup>2</sup> of the brain and spine (± contrast):**
  - ▶ **Gold standard**
  - ▶ **Provides a “static” picture of tumors**
  - ▶ **Benefits: Provides a reasonably good delineation of tumors. Higher grade tumors and brain leptomeningeal metastasis usually enhance. Lower grade tumors usually do not enhance.**
  - ▶ **Limitations: Sensitive to movement, metallic objects cause artifact, patients with implantable devices cannot have an MRI, claustrophobia may be an issue, or renal insufficiency**
- **CT of the brain and spine (± contrast):**
  - ▶ **Should be used in patients who cannot have an MRI**
  - ▶ **Benefits: Claustrophobia or implantable devices are not an issue, can be done faster than an MRI**
  - ▶ **Limitations: Lacks resolution of MRI, especially in posterior fossa, or renal insufficiency**
- **MR Spectroscopy: Assess metabolites within tumors and normal tissue**
  - ▶ **May be useful in differentiating tumor from radiation necrosis; may be helpful in grading tumors or assessing response.**
  - ▶ **Area most abnormal would be the best place to target for a biopsy**
  - ▶ **Limitations: Tumors near vessels, air spaces, or bone. Extra time in MRI and others as noted under MRI**
- **MR Perfusion: Measures cerebral blood volume in tumors**
  - ▶ **May be useful in differentiating grade of tumor or tumor versus radiation necrosis. Area of highest perfusion would be the best place to biopsy.**
  - ▶ **Limitations: Tumors near vessels, air spaces, bone, small volume lesions, or tumors in the spinal cord. Extra time in MRI and others as noted under MRI**
- **Brain amino acid FDG-PET scanning: Assess metabolism within tumor and normal tissue by using radio-labeled tracers**
  - ▶ **May be useful in differentiating tumor from radiation necrosis but has some limitations; may also correlate with tumor grade or provide the optimal area for biopsy**
  - ▶ **Limitations: Accuracy of interpretations, availability of equipment and isotopes**

**This is a list of imaging modalities available and used in neuro-oncology primarily to make treatment decisions. The most common use for MR spectroscopy, MR perfusion, and body PET is to differentiate radiation necrosis from active tumor, as this might obviate the need for surgery or the discontinuation of an effective therapy.**

<sup>1</sup>The imaging modalities listed may not be available at every institution.

<sup>2</sup>Wen PY, Macdonald DR, Reardon DA, et al. Updated response assessment for high-grade gliomas: Response Assessment in neuro-oncology working group. J Clin Oncol 2010;28:1963-1972.

**Note: All recommendations are category 2A unless otherwise indicated.**

**Clinical Trials: NCCN believes that the best management of any cancer patient is in a clinical trial. Participation in clinical trials is especially encouraged.**

## PRINCIPLES OF BRAIN TUMOR SURGERY

### GUIDING PRINCIPLES

- Maximal tumor removal when appropriate
- Minimal surgical morbidity
- Accurate diagnosis

### FACTORS

- Age
- Performance status (PS)
- Feasibility of decreasing the mass effect with surgery
- Resectability, including number of lesions, location of lesions, time since last surgery (recurrent patients)
- New versus recurrent tumor
- Suspected pathology – benign vs. malignant, possibility of other non-cancer diagnoses, projected natural history

### OPTIONS

- Gross total resection where feasible
- Stereotactic biopsy
- Open biopsy/debulking followed by planned observation or adjuvant therapy
- Chemotherapy implants, when indicated (See footnote g on [GLIO-1](#))

### TISSUE

- Sufficient tissue to pathologist for neuropathology evaluation and molecular correlates.
- Frozen section analysis when possible to help with intraoperative decision making
- Review by experienced neuropathologist

- Postoperative MRI should be performed within 24-72 hours for gliomas and parenchymal brain tumors to determine the extent of resection.
- The extent of resection should be judged on the postoperative study and used as a baseline to assess further therapeutic efficacy or tumor progression.

Note: All recommendations are category 2A unless otherwise indicated.

Clinical Trials: NCCN believes that the best management of any cancer patient is in a clinical trial. Participation in clinical trials is especially encouraged.

**PRINCIPLES OF BRAIN TUMOR RADIATION THERAPY****Low Grade Gliomas (Grades I/II)**

- Tumor volumes are best defined using pre- and postoperative imaging, usually FLAIR and or T2 signal abnormality on MRI for GTV. CTV (GTV plus 1-2 cm margin) should receive 45-54 Gy in 1.8-2.0 Gy fractions.
- SRS has not been established to have a role in the management of low grade gliomas. Phase I trials using SRS do not support its role as initial treatment.

**High Grade Gliomas (Grades III/IV)**

- The gross tumor volume (GTV) is best defined using pre- and postoperative MRI imaging using enhanced T1 and FLAIR/T2. The GTV is expanded by 2-3 cm (Clinical target volume, CTV) to account for sub-diagnostic tumor infiltration. Fields are usually reduced for the last phase of the treatment (boost).
- The recommended dose is 60 Gy in 1.8 to 2.0 Gy fractions. A slightly lower dose, such as 55.8 to 59.4 Gy in 1.8 Gy or 57 Gy in 1.9 Gy fractions, can be applied when the tumor volume is very large (gliomatosis) or for Grade III astrocytoma.
- In poorly performing patients or the elderly a hypofractionated accelerated course was found to be effective with the goal of completing the treatment in 2-4 weeks. Typical fractionation schedules are 34 Gy/10, 40.05 Gy/15 or 50 Gy/20.<sup>1,2</sup>

CR: Complete response  
CTV: Clinical target volume  
FLAIR: Fluid-attenuated inversion recovery  
GTV: Gross tumor volume

**Ependymoma**

- Limited Fields: Intracranial tumor volumes are best defined using pre- and postoperative imaging, usually enhanced T1 and or FLAIR/T2. Anatomic areas touched by preoperative tumor volume plus postoperative signal abnormality on MRI for GTV. CTV (GTV plus 1-2 cm margin) should receive 54-59.4 Gy in 1.8 to 2.0 Gy fractions.
- Craniospinal:† Whole brain and spine (to bottom of thecal sac) receive 36 Gy in 1.8 Gy fractions, followed by limited field to spine lesions to 45 Gy. Primary brain site should receive total dose of 54-59.4 Gy in 1.8 to 2.0 Gy fraction.
- For spine ependymomas, see section on primary spinal cord tumors ([BRAIN-C 2 of 3](#))

**Adult Medulloblastoma and Supratentorial PNET:**

- Standard risk for recurrence:
  - ▶ Conventional dose: 30-36 Gy CSI:<sup>3,†</sup> and boosting the primary brain site to 54-55.8 Gy without adjuvant chemotherapy
  - ▶ Reduced dose: 23.4 Gy CSI:<sup>3,†</sup> and boosting the primary brain site to 54-55.8 Gy with adjuvant chemotherapy<sup>1</sup>
- High risk for recurrence: 36 Gy CSI:<sup>3,†</sup> with boosting primary brain site to 54-55.8 Gy<sup>††</sup>

**Primary CNS Lymphoma**

- WBRT may be withheld in the primary setting in patients treated with chemotherapy. When used, WBRT doses should be limited to 24-36 Gy in 1.8-2.0 Gy fractions following a CR to chemotherapy. For less than CR, consider the same WBRT dose followed by a limited field to gross disease to 45 Gy.
- Lower doses of radiation are less toxic and may be as effective.

† Considering protons over photons (if available) for craniospinal irradiation in adults is reasonable.

†† Regimen supported by data from pediatric trials only.

Note: All recommendations are category 2A unless otherwise indicated.

Clinical Trials: NCCN believes that the best management of any cancer patient is in a clinical trial. Participation in clinical trials is especially encouraged.

[Continued](#)



### PRINCIPLES OF BRAIN TUMOR RADIATION THERAPY

#### Primary Spinal Cord Tumors:

- Doses of 45-50.4 Gy are recommended using fractions of 1.8 Gy. In tumors below the conus medularis higher doses up to 60 Gy can be delivered.

#### Meningiomas

- WHO grade 1 and 2 meningiomas may be treated by fractionated conformal radiotherapy with doses of 45-54 Gy.
- WHO grade 3 meningiomas should be treated as malignant tumors with tumor bed and gross tumor + a margin (2-3 cm) receiving 54-60 Gy in 1.8-2 Gy fractions.
- WHO grade 1 meningiomas may also be treated with stereotactic radiosurgery doses of 12-14 Gy in a single fraction when appropriate.

#### Brain Metastases

- Whole brain radiotherapy (WBRT): Doses vary between 20 and 40 Gy delivered in 5-20 fractions. The standard regimens include 30 Gy in 10 fractions or 37.5 Gy in 15 fractions. Nevertheless 20 Gy in 5 fractions is a good option in poor performers.<sup>5</sup>
- Stereotactic radiosurgery: Maximum marginal doses of 24, 18, or 15 Gy according to tumor volume is recommended (RTOG 90-05).<sup>6-7</sup>

#### Leptomeningeal Metastases

- Volumes and dose depend on primary source and sites requiring palliation.

#### Metastatic Spine

- Doses to vertebral body metastases will depend on patient's performance status, spine stability, location in relationship to spinal cord, and primary histology. Generally doses of 15-40 Gy are delivered in 1-15 fractions over 1 day - 3 weeks. It is critical to consider tolerance at the spine and/or nerve route. In selected cases, or recurrences after previous radiation, stereotactic radiotherapy is appropriate. At the retreatment site, it is critical to consider tolerance of the spine and/or spinal nerve roots. Generally recommended that 6 months or more of time between treatments is required.

CR: Complete response  
CTV: Clinical target volume  
FLAIR: Fluid-attenuated inversion recovery  
GTV: Gross tumor volume

**Note:** All recommendations are category 2A unless otherwise indicated.

**Clinical Trials:** NCCN believes that the best management of any cancer patient is in a clinical trial. Participation in clinical trials is especially encouraged.

[References on next page](#)



### PRINCIPLES OF BRAIN TUMOR RADIATION THERAPY (References)

- <sup>1</sup>Roa W, Brasher PM, Bauman G, et al. Abbreviated course of radiation therapy in older patients with glioblastoma multiforme: a prospective randomized clinical trial. *J Clin Onc* 2004;22:1583-1588.
- <sup>2</sup>Malmström A, Grønberg BH, Marosi C, et al. Temozolomide versus standard 6-week radiotherapy versus hypofractionated radiotherapy in patients older than 60 years with glioblastoma: the Nordic randomised, phase 3 trial. *Lancet Oncol* 2012;13:916-920.
- <sup>3</sup>Brown AP, Barney CL, Grosshans DR. Proton beam craniospinal irradiation reduces acute toxicity for adults with medulloblastoma. *Int J Radiat Oncol Biol Phys* 2013;86:277-284.
- <sup>4</sup>Packer RJ, Gajjar A, Vezina G, et al. Phase III study of craniospinal radiation therapy followed by adjuvant chemotherapy for newly diagnosed average-risk medulloblastoma. *J Clin Oncol* 2006;24:4202-4208.
- <sup>5</sup>Andrews DW, Scott CB, Sperduto PW, et al. Whole brain radiation therapy with or without stereotactic radiosurgery boost for patients with one to three brain metastases: phase III results of the RTOG 9508 randomized trial. *Lancet* 2004;363:1665-1672.
- <sup>6</sup>Shaw E, Scott C, Souhami L, et al. Single dose radiosurgical treatment of recurrent previously irradiated primary brain tumors and brain metastases: final report of RTOG protocol 90-05. *J Radiat Oncol Biol Phys* 2000;47:291-298.
- <sup>7</sup>Aoyama H, Shirato H, Tago M, et al. Stereotactic radiosurgery plus whole-brain radiation therapy vs stereotactic radiosurgery alone for treatment of brain metastases: A randomized controlled trial. *JAMA* 2006;295:2483-2491.

**Note:** All recommendations are category 2A unless otherwise indicated.

**Clinical Trials:** NCCN believes that the best management of any cancer patient is in a clinical trial. Participation in clinical trials is especially encouraged.



**PRINCIPLES OF BRAIN AND SPINAL CORD TUMOR SYSTEMIC THERAPY**

**Adult Low-Grade Infiltrative Supratentorial Astrocytoma/  
Oligodendroglioma (excluding pilocytic astrocytoma)**

- **Adjuvant Treatment:**
  - ▶ Temozolomide<sup>1-3</sup>
- **Recurrence or Progressive, Low grade disease:**
  - ▶ Temozolomide\*,<sup>2-4</sup>
  - ▶ Lomustine or carmustine
  - ▶ Combination PCV (lomustine + procarbazine + vincristine)<sup>5</sup>
  - ▶ Platinum based regimens<sup>6-8</sup>

**Anaplastic Gliomas**

- **Adjuvant Treatment:**
  - ▶ Temozolomide or PCV with deferred RT<sup>9-11</sup>
  - ▶ Concurrent (with RT) temozolomide<sup>12</sup> 75 mg/m<sup>2</sup> daily
- **Recurrence/Salvage therapy**
  - ▶ Temozolomide<sup>3,4,13,14</sup>
  - ▶ Lomustine or carmustine<sup>15</sup>
  - ▶ Combination PCV
  - ▶ Bevacizumab†,<sup>16-18</sup>
  - ▶ Bevacizumab + chemotherapy††  
(irinotecan,<sup>19,20</sup> carmustine/lomustine,<sup>21</sup> temozolomide,  
carboplatin [category 2B for carboplatin]<sup>22,23</sup>)
  - ▶ Irinotecan<sup>24,25</sup>
  - ▶ Cyclophosphamide (category 2B)<sup>26,27</sup>
  - ▶ Platinum-based regimens<sup>α</sup>
  - ▶ Etoposide<sup>28</sup>

**Anaplastic Oligoastrocytoma**  
**Anaplastic Oligodendroglioma**

- **Adjuvant Treatment**
  - ▶ RT and PCV for 1p19q co-deleted (category 1)<sup>29</sup>

**Glioblastoma**

- **Adjuvant Treatment:**
  - ▶ Concurrent (with RT) temozolomide<sup>12</sup> 75 mg/m<sup>2</sup> daily
  - ▶ Post RT temozolomide<sup>12</sup> 150-200 mg/m<sup>2</sup> 5/28 schedule
  - ▶ Temozolomide<sup>12,30</sup> 150-200 mg/m<sup>2</sup> 5/28 schedule
- **Recurrence/Salvage therapy**
  - ▶ Bevacizumab†,<sup>31-33</sup>
  - ▶ Bevacizumab + chemotherapy††  
(irinotecan,<sup>32-34</sup> carmustine/lomustine,<sup>21</sup> temozolomide, carboplatin  
[category 2B for carboplatin]<sup>22,23</sup>)
  - ▶ Temozolomide<sup>4,12,35</sup>
  - ▶ Lomustine or carmustine<sup>15</sup>
  - ▶ Combination PCV
  - ▶ Cyclophosphamide (category 2B)<sup>26</sup>
  - ▶ Platinum-based regimens<sup>α</sup>

**Adult Intracranial and Spinal Ependymoma  
(excluding subependymoma)**

- **Recurrence**
  - ▶ Platinum-based regimens:<sup>α</sup> Single agent or combination<sup>36</sup>
  - ▶ Etoposide
  - ▶ Lomustine or carmustine<sup>36</sup>
  - ▶ Bevacizumab†
  - ▶ Temozolomide

\*For patients not previously treated.

<sup>α</sup>Platinum-based regimens include cisplatin or carboplatin.

†Patients who have good performance status but evidence of radiographic progression may benefit from continuation of bevacizumab to prevent rapid neurologic deterioration.

††Bevacizumab + chemotherapy can be considered for patients who have failed monotherapy with bevacizumab.

**Note:** All recommendations are category 2A unless otherwise indicated.

**Clinical Trials:** NCCN believes that the best management of any cancer patient is in a clinical trial. Participation in clinical trials is especially encouraged.

[Continued](#)

**PRINCIPLES OF BRAIN AND SPINAL CORD TUMOR SYSTEMIC THERAPY****Adult Medulloblastoma and Supratentorial PNET****• Adjuvant Treatment**

- ▶ **Weekly vincristine<sup>φ</sup> during craniospinal radiation therapy followed by either of the following regimens:**

- ◊ **Cisplatin, cyclophosphamide, and vincristine<sup>37,φ</sup>**
- ◊ **Cisplatin, lomustine, and vincristine<sup>37,φ</sup>**

**• Recurrence/Salvage therapy**

- ▶ **No prior chemotherapy**

- ◊ **High-dose cyclophosphamide ± etoposide**
- ◊ **Carboplatin, etoposide, and cyclophosphamide**
- ◊ **Cisplatin, etoposide, and cyclophosphamide**
- ◊ **Consider high-dose chemotherapy with autologous stem cell reinfusion<sup>38</sup> in patients who achieve a complete response with conventional doses of salvage chemotherapy or have no residual disease after re-resection**

- ▶ **Prior chemotherapy**

- ◊ **High dose cyclophosphamide ± etoposide**
- ◊ **Oral etoposide<sup>39,40</sup>**
- ◊ **Temozolomide<sup>3</sup>**
- ◊ **Consider high-dose chemotherapy with autologous stem cell reinfusion<sup>38</sup> in patients who achieve a complete response with conventional doses of salvage chemotherapy or have no residual disease after re-resection**

**Primary CNS Lymphoma****• Primary Treatment**

- ▶ **High dose methotrexate 3.5 g/m<sup>2</sup> combined with the following plus RT<sup>λ</sup>:**

- ◊ **Vincristine, procarbazine, cytarabine ± rituximab<sup>41-43</sup>**
- ◊ **Cytarabine<sup>44</sup>**
- ◊ **Ifosfamide ± RT<sup>45</sup>**

- ▶ **High dose methotrexate 8 g/m<sup>2</sup> combined with the following plus deferred RT<sup>46</sup>**

- ◊ **Rituximab<sup>47,48</sup>**
- ◊ **Rituximab and temozolomide<sup>49</sup>**

- ▶ **Consider urgent glucarpidase (carboxypeptidase G2) for prolonged methotrexate clearance due to methotrexate induced renal toxicity<sup>50</sup>**

**• Recurrence or Progressive Disease**

- ▶ **Retreat with high-dose methotrexate<sup>46</sup>**
- ▶ **Temozolomide**
- ▶ **Rituximab ± temozolomide<sup>51</sup>**
- ▶ **Topotecan**
- ▶ **Consider high-dose chemotherapy with autologous stem cell reinfusion in patients who achieve a complete response with conventional doses of salvage chemotherapy**
- ▶ **High-dose cytarabine<sup>52</sup>**
- ▶ **Dexamethasone, high-dose cytarabine, cisplatin<sup>53</sup>**
- ▶ **Pemetrexed<sup>54</sup>**

**Meningiomas**

- **Interferon alfa (category 2B)<sup>55</sup>**
- **Somatostatin analogue<sup>56</sup>**

<sup>φ</sup>Omission of vincristine during radiotherapy phase of therapy or dose modification may be required for adults because they do not tolerate this regimen as well.

Data supporting vincristine's use have been found in pediatric trials only. Patients should be closely monitored for neurologic toxicity with periodic exams.

<sup>λ</sup>Other combinations with methotrexate may be used.

**Note:** All recommendations are category 2A unless otherwise indicated.

**Clinical Trials:** NCCN believes that the best management of any cancer patient is in a clinical trial. Participation in clinical trials is especially encouraged.

[Continued](#)



### PRINCIPLES OF BRAIN AND SPINAL CORD TUMOR SYSTEMIC THERAPY

#### Limited (1-3) Metastatic or Multiple (> 3) Metastatic Lesions

- **Recurrent Disease<sup>‡</sup>**
  - ▶ Treatment as per the regimens of the primary tumor
  - ▶ Carmustine wafer<sup>57</sup>
  - ▶ Temozolomide 5/28 schedule
  - ▶ High dose methotrexate<sup>58,59</sup> (breast<sup>58</sup> and lymphoma)
  - ▶ Capecitabine ± lapatinib,<sup>60,61</sup> cisplatin,<sup>62,63</sup> etoposide<sup>62,63</sup> (breast)<sup>64-68</sup>
  - ▶ Topotecan (small cell lung)
  - ▶ Ipilimumab (melanoma)<sup>69</sup>
  - ▶ BRAF inhibitors (melanoma)
    - ※ Dabrafenib<sup>70</sup>
    - ※ Vemurafenib<sup>71</sup>

#### Leptomeningeal Metastases

- **Treatment**
  - ▶ Organ specific systemic chemotherapy; emphasizing drugs with good CNS penetration
  - ▶ Intra-CSF chemotherapy<sup>72</sup>
    - ◇ Liposomal cytarabine [lymphoma/leukemias]<sup>73,74</sup>
    - ◇ Methotrexate [lymphoma/leukemias, breast]
    - ◇ Cytarabine [lymphoma/leukemias]
    - ◇ Thiotepea
    - ◇ Rituximab (lymphoma)<sup>74</sup>
    - ◇ Topotecan<sup>75</sup>
    - ◇ Etoposide<sup>76</sup>
    - ◇ Interferon alfa (category 2B)<sup>77</sup>
    - ◇ Trastuzumab (breast)<sup>78</sup>
  - ▶ High-dose methotrexate for lymphoma and breast<sup>58</sup>
  - ▶ Weekly pulse erlotinib for EGFR exon 19 deletion or exon 21 L858R mutation (non-small cell lung cancer) (category 2B)<sup>79</sup>

#### Metastatic Spine Tumors

- Use regimen for disease specific site

<sup>‡</sup>Use agents active against primary tumor.

**Note:** All recommendations are category 2A unless otherwise indicated.

**Clinical Trials:** NCCN believes that the best management of any cancer patient is in a clinical trial. Participation in clinical trials is especially encouraged.

[References on next page](#)

**PRINCIPLES OF BRAIN AND SPINAL CORD TUMOR SYSTEMIC THERAPY (References)**

- <sup>1</sup>Pouratian N, Gasco J, Sherman JH, Shaffrey ME, Schiff D. Toxicity and efficacy of protracted low dose temozolomide for the treatment of low grade gliomas. *J Neurooncol.* 2007;82:281-288.
- <sup>2</sup>Kesari S, Schiff D, Drappatz J, et al. Phase II study of protracted daily temozolomide for low-grade gliomas in adults. *Clin Cancer Res.* 2009;15:330-337.
- <sup>3</sup>Nicholson HS, Kretschmar CS, Krailo M, et al. Phase 2 study of temozolomide in children and adolescents with recurrent central nervous system tumors: a report from the Children's Oncology Group. *Cancer* 2007;110:1542-1550.
- <sup>4</sup>Perry JR, Rizek P, Cashman R, Morrison M, Morrison T. Temozolomide rechallenge in recurrent malignant glioma by using a continuous temozolomide schedule: the "rescue" approach. *Cancer.* 2008;113:2152-2157.
- <sup>5</sup>Triebels VH, Taphoorn MJ, Brandes AA, et al. Salvage PCV chemotherapy for temozolomide-resistant oligodendrogliomas. *Neurology* 2004;63:904-906.
- <sup>6</sup>Massimino M, Spreafico F, Riva D, et al. A lower-dose, lower-toxicity cisplatin-etoposide regimen for childhood progressive low-grade glioma. *J Neurooncol.* 2010.
- <sup>7</sup>Moghrabi A, Friedman HS, Ashley DM, et al. Phase II study of carboplatin (CBDCA) in progressive low-grade gliomas. *Neurosurg Focus.* 1998;4:e3.
- <sup>8</sup>Brandes AA, Basso U, Vastola F, et al. Carboplatin and teniposide as third-line chemotherapy in patients with recurrent oligodendroglioma or oligoastrocytoma: a phase II study. *Ann Oncol* 2003;14:1727-1731.
- <sup>9</sup>Mikkelsen T, Doyle T, Anderson J, et al. Temozolomide single-agent chemotherapy for newly diagnosed anaplastic oligodendroglioma. *J Neurooncol* 2009;92:57-63.
- <sup>10</sup>Taliansky-Aronov A, Bokstein F, Lavon I, Siegal T. Temozolomide treatment for newly diagnosed anaplastic oligodendrogliomas: a clinical efficacy trial. *J Neurooncol* 2006;79:153-157.
- <sup>11,2</sup>Wick W, Hartmann C, Engel C, et al. NOA-04 randomized phase III trial of sequential radiochemotherapy of anaplastic glioma with procarbazine, lomustine, and vincristine or temozolomide. *J Clin Oncol* 2009;27:5874-5880.
- <sup>12</sup>Stupp R, Mason WP, van den Bent MJ, et al. Radiotherapy plus concomitant and adjuvant temozolomide for glioblastoma. *N Engl J Med.* 2005;352:987-996.
- <sup>13</sup>ung WK, Prados MD, Yaya-Tur R, et al. Multicenter phase II trial of temozolomide in patients with anaplastic astrocytoma or anaplastic oligoastrocytoma at first relapse. *Temodal Brain Tumor Group. J Clin Oncol* 1999;17:2762-2771.
- <sup>14</sup>Perry JR, Belanger K, Mason WP, et al. Phase II trial of continuous dose-intense temozolomide in recurrent malignant glioma: RESCUE study. *J Clin Oncol* 2010;28:2051-2057.
- <sup>15</sup>Wick W, Puduvalli VK, Chamberlain C, et al. Phase III Study of Enzastaurin Compared with lomustine in the treatment of recurrent intracranial glioblastoma. *J Clin Oncol* 2010;29:1168-1174.
- <sup>16</sup>Norden AD, Young GS, Setayesh K, et al. Bevacizumab for recurrent malignant gliomas: efficacy, toxicity, and patterns of recurrence. *Neurology* 2008;70:779-787.
- <sup>17</sup>Chamberlain MC, Johnston S. Bevacizumab for recurrent alkylator-refractory anaplastic oligodendroglioma. *Cancer* 2009;115:1734-1743.
- <sup>18</sup>Chamberlain MC, Johnston S. Salvage chemotherapy with bevacizumab for recurrent alkylator-refractory anaplastic astrocytoma. *J Neurooncol* 2009;91:359-367.
- <sup>19</sup>Taillibert S, Vincent LA, Granger B, et al. Bevacizumab and irinotecan for recurrent oligodendroglial tumors. *Neurology* 2009;72:1601-1606.
- <sup>20</sup>Vredenburgh JJ, Desjardins A, Herndon JE, 2nd, et al. Phase II trial of bevacizumab and irinotecan in recurrent malignant glioma. *Clin Cancer Res* 2007;13:1253-1259.
- <sup>21</sup>Soffiotti R, Ruda R, Trevisan E, et al. Phase II study of bevacizumab and nitrosourea in patients with recurrent malignant glioma: A multicenter Italian study [abstract]. *J Clin Oncol* 2009;27(Suppl 15S):2012.
- <sup>22</sup>Mrugala MM, Crew LK, Fink JR, et al. Carboplatin and bevacizumab for recurrent malignant glioma. *Oncol Lett.* 2012;4:1082-1086.
- <sup>23</sup>Thompson EM, Dosa E, Kraemer DF, et al. Treatment with bevacizumab plus carboplatin for recurrent malignant glioma. *Neurosurgery.* 2010;67:87-93.
- <sup>24</sup>Chamberlain MC, Wei-Tsao DD, Blumenthal DT, Glantz MJ. Salvage chemotherapy with CPT-11 for recurrent temozolomide-refractory anaplastic astrocytoma. *Cancer* 2008;112:2038-2045.

**Note:** All recommendations are category 2A unless otherwise indicated.

**Clinical Trials:** NCCN believes that the best management of any cancer patient is in a clinical trial. Participation in clinical trials is especially encouraged.

[Continued](#)



### PRINCIPLES OF BRAIN AND SPINAL CORD TUMOR SYSTEMIC THERAPY (References)

- <sup>25</sup>Chamberlain MC. Salvage chemotherapy with CPT-11 for recurrent oligodendrogliomas. *J Neurooncol* 2002;59:157-163.
- <sup>26</sup>Chamberlain MC, Tsao-Wei D. Salvage chemotherapy with cyclophosphamide for recurrent, temozolomide-refractory glioblastoma multiforme. *Cancer* 2004;100:1213-1220.
- <sup>27</sup>Chamberlain MC, Tsao-Wei D, Groshen S. Salvage chemotherapy with cyclophosphamide for recurrent temozolomide-refractory anaplastic astrocytoma. *Cancer* 2006;106:172-179.
- <sup>28</sup>Fulton D, Urtasun R, Forsyth P. Phase II study of prolonged oral therapy with etoposide (VP16) for patients with recurrent malignant glioma. *J Neurooncol* 1996;27:149-155.
- <sup>29</sup>van den Bent MJ, Brandes AA, Taphoorn MJ. Adjuvant Procarbazine, Lomustine, and Vincristine Chemotherapy in Newly Diagnosed Anaplastic Oligodendroglioma: Long-Term Follow-Up of EORTC Brain Tumor Group Study 26951. *J Clin Oncol* 2012; Epub ahead of print.
- <sup>30</sup>Malmstrom A, Gronberg BH, Marosi C, et al. Temozolomide versus standard 6-week radiotherapy versus hypofractionated radiotherapy in patients older than 60 years with glioblastoma: the Nordic randomised, phase 3 trial. *Lancet Oncol* 2012;13:916-926.
- <sup>31</sup>Cloughesy T, Prados MD, Mikkelsen T. A phase 2 randomized non-comparative clinical trial of the effect of bevacizumab alone or in combination with irinotecan on 6-month progression free survival in recurrent refractory glioblastoma [abstract]. *J Clin Oncol* 2008;26(Suppl 15):2010b.
- <sup>32</sup>Friedman HS, Prados MD, Wen PY, et al. Bevacizumab alone and in combination with irinotecan in recurrent glioblastoma. *J Clin Oncol* 2009;27:4733-4740.
- <sup>33</sup>Kreisl TN, Kim L, Moore K, et al. Phase II trial of single-agent bevacizumab followed by bevacizumab plus irinotecan at tumor progression in recurrent glioblastoma. *J Clin Oncol* 2009;27:740-745.
- <sup>34</sup>Vredenburgh JJ, Desjardins A, Herndon JE, 2nd, et al. Bevacizumab plus irinotecan in recurrent glioblastoma multiforme. *J Clin Oncol* 2007;25:4722-4729.
- <sup>35</sup>Yung WK, Albright RE, Olson J, et al. A phase II study of temozolomide vs. procarbazine in patients with glioblastoma multiforme at first relapse. *Br J Cancer* 2000;83:588-593.
- <sup>36</sup>Gornet MK, Buckner JC, Marks RS, et al. Chemotherapy for advanced CNS ependymoma. *J Neurooncol* 1999;45:61-67.
- <sup>37</sup>Packer RJ, Gajjar A, Vezina G, et al. Phase III study of craniospinal radiation therapy followed by adjuvant chemotherapy for newly diagnosed average-risk medulloblastoma. *J Clin Oncol* 2006;24:4202-4208.
- <sup>38</sup>Dunkel IJ, Gardner SL, Garvin JH, Jr., et al. High-dose carboplatin, thiotepa, and etoposide with autologous stem cell rescue for patients with previously irradiated recurrent medulloblastoma. *Neuro Oncol* 2010;12:297-303.
- <sup>39</sup>Ashley DM, Meier L, Kerby T, et al. Response of recurrent medulloblastoma to low-dose oral etoposide. *J Clin Oncol* 1996;14:1922-1927.
- <sup>40</sup>Chamberlain MC, Kormanik PA. Chronic oral VP-16 for recurrent medulloblastoma. *Pediatr Neurol* 1997;17:230-234.
- <sup>41</sup>DeAngelis LM, Seiferheld W, Schold SC, et al. Combination chemotherapy and radiotherapy for primary central nervous system lymphoma: Radiation Therapy Oncology Group Study 93-10. *J Clin Oncol* 2002;20:4643-4648.
- <sup>42</sup>Shah GD, Yahalom J, Correa DD, et al. Combined immunochemotherapy with reduced whole-brain radiotherapy for newly diagnosed primary CNS lymphoma. *J Clin Oncol* 2007;25:4730-4735. Erratum in: *J Clin Oncol*. 2008;26:340.
- <sup>43</sup>Gavrilovc IT, Hormigo A, Yahalom J, et al. Long-term follow-up of high-dose methotrexate-based therapy with and without whole brain irradiation for newly diagnosed primary CNS lymphoma. *J Clin Oncol* 2006;24: 4570-4574.
- <sup>44</sup>Ferreri AJ, Reni M, Foppoli M, et al. High-dose cytarabine plus high-dose methotrexate versus high-dose methotrexate alone in patients with primary CNS lymphoma: a randomised phase 2 trial. *Lancet* 2009;374:1512-1520.
- <sup>45</sup>Thiel E, Korfel A, Martus P, et al. High-dose methotrexate with or without whole brain radiotherapy for primary CNS lymphoma (G-PCNSL-SG-1): a phase 3, randomised, non-inferiority trial. *Lancet Oncol*. 2010 Nov;11:1036-1047. Epub 2010 Oct 20.

**Note:** All recommendations are category 2A unless otherwise indicated.

**Clinical Trials:** NCCN believes that the best management of any cancer patient is in a clinical trial. Participation in clinical trials is especially encouraged.

[Continued](#)

**PRINCIPLES OF BRAIN AND SPINAL CORD TUMOR SYSTEMIC THERAPY (References)**

- <sup>46</sup>Batchelor T, Carson K, O'Neill A, et al. Treatment of primary CNS lymphoma with methotrexate and deferred radiotherapy: a report of NABTT 96-07. *J Clin Oncol* 2003;21:1044-1049.
- <sup>47</sup>Chamberlain MC and Johnston SK. High-dose methotrexate and rituximab with deferred radiotherapy for newly diagnosed primary B-cell CNS lymphoma. *Neuro Oncol* 2010;12:736-744.
- <sup>48</sup>Gregory G, Arumugaswamy A, Leung T, et al. Rituximab is associated with improved survival for aggressive B cell CNS lymphoma. 2013;15:1068-1073
- <sup>49</sup>Wieduwilt MJ, Valles F, Issa S, et al. Immunochemotherapy with Intensive Consolidation for Primary Central Nervous System Lymphoma: A Pilot Study and Prognostic Assessment by Diffusion-Weighted MRI. *Clin Cancer Res*. 2012 Jan 6. [Epub ahead of print]
- <sup>50</sup>Widemann BC, Balis FM, Kim A, et al. Glucarpidase, leucovorin, and thymidine for high-dose methotrexate-induced renal dysfunction: clinical and pharmacologic factors affecting outcome. *J Clin Oncol* 2010;28:3979-3986.
- <sup>51</sup>Enting RH, Demopoulos A, DeAngelis LM, Abrey LE. Salvage therapy for primary CNS lymphoma with a combination of rituximab and temozolomide. *Neurology* 2004;63:901-903.
- <sup>52</sup>De Angelis L, Kreis W, Chan K, et al. Pharmacokinetics of ara-C and ara-U in plasma and CSF after high-dose administration of cytosine arabinoside. *Cancer Chemother Pharmacol* 1992;29:173-177.
- <sup>53</sup>McLaughlin P, Velasquez WS, Redman JR, et al. Chemotherapy with dexamethasone, high-dose cytarabine, and cisplatin for parenchymal brain lymphoma. *J Natl Cancer Inst* 1988;80:1408-1412.
- <sup>54</sup>Raizer JJ, Rademaker A, Evens AM, et al. Pemetrexed in the treatment of relapsed/refractory primary central nervous system lymphoma. *Cancer* 2012;118:3743-3748.
- <sup>55</sup>Chamberlain MC, Glantz MJ. Interferon-alpha for recurrent World Health Organization grade 1 intracranial meningiomas. *Cancer* 2008;113:2146-2151.
- <sup>56</sup>Chamberlain MC, Glantz MJ, Fadul CE. Recurrent meningioma: salvage therapy with long-acting somatostatin analogue. *Neurology* 2007;69:969-973.
- <sup>57</sup>Ewend MG, Brem S, Gilbert M, et al. Treatment of single brain metastasis with resection, intracavity carmustine polymer wafers, and radiation therapy is safe and provides excellent local control. *Clin Cancer Res* 2007;13:3637-3641.
- <sup>58</sup>Lassman AB, Abrey LE, Shah GD, et al. Systemic high-dose intravenous methotrexate for central nervous system metastases. *J Neurooncol* 2006;78:255-260.
- <sup>59</sup>Bokstein F, Lossos A, Lossos IS, Siegal T. Central nervous system relapse of systemic non-Hodgkin's lymphoma: results of treatment based on high-dose methotrexate combination chemotherapy. *Leuk Lymphoma* 2002;43:587-593.
- <sup>60</sup>Metro G, Foglietta J, Russillo M et al. Clinical outcome of patients with brain metastases from HER2-positive breast cancer treated with lapatinib and capecitabine. *Ann Oncol*. 2011;22:625-630.
- <sup>61</sup>Sutherland S, Ashley S, Miles D, et al. Treatment of HER2-positive metastatic breast cancer with lapatinib and capecitabine in the lapatinib expanded access programme, including efficacy in brain metastases--the UK experience. *Br J of Cancer* 2010;102:995-1002.
- <sup>62</sup>Cocconi G, Lottici R, Bisagni G, et al. Combination therapy with platinum and etoposide of brain metastases from breast carcinoma. *Cancer Invest* 1990;8:327-334.
- <sup>63</sup>Franciosi V, Cocconi G, Michiara M, et al. Front-line chemotherapy with cisplatin and etoposide for patients with brain metastases from breast carcinoma, nonsmall cell lung carcinoma, or malignant melanoma: a prospective study. *Cancer* 1999;85:1599-1605.
- <sup>64</sup>Rivera E, Meyers C, Groves M, et al. Phase I study of capecitabine in combination with temozolomide in the treatment of patients with brain metastases from breast carcinoma. *Cancer* 2006;107:1348-1354.
- <sup>65</sup>Fabi A, Vidiri A, Ferretti G, et al. Dramatic regression of multiple brain metastases from breast cancer with Capecitabine: another arrow at the bow? *Cancer Invest* 2006;24:466-468.
- <sup>66</sup>Siegelmann-Danieli N, Stein M, Bar-Ziv J. Complete response of brain metastases originating in breast cancer to capecitabine therapy. *Isr Med Assoc J* 2003;5:833-834.

**Note:** All recommendations are category 2A unless otherwise indicated.

**Clinical Trials:** NCCN believes that the best management of any cancer patient is in a clinical trial. Participation in clinical trials is especially encouraged.

[Continued](#)



### PRINCIPLES OF BRAIN AND SPINAL CORD TUMOR SYSTEMIC THERAPY (References)

- <sup>67</sup>Wang ML, Yung WK, Royce ME, et al. Capecitabine for 5-fluorouracil-resistant brain metastases from breast cancer. *Am J Clin Oncol* 2001;24:421-424.
- <sup>68</sup>Hikino H, Yamada T, Johbara K, et al. Potential role of chemo-radiation with oral capecitabine in a breast cancer patient with central nervous system relapse. *Breast* 2006;15:97-99.
- <sup>69</sup>Margolin K, Ernstoff MS, Hamid O, et al. Ipilimumab in patients with melanoma and brain metastases: an open-label, phase 2 trial. *The Lancet Oncology* 2012;13:459-465.
- <sup>70</sup>Long GV et al. Dabrafenib in patients with Val600Glu or Val600Lys BRAF-mutant melanoma metastatic to the brain (BREAK-MB): a multicentre, open-label, phase 2 trial. *Lancet Oncol* 2012;13:1087-95.
- <sup>71</sup>Dummer R, Goldinger SM, Turtzchi CP, et al. Vemurafenib in patients with BRAF(V600) mutation-positive melanoma with symptomatic brain metastases: Final results of an open-label pilot study. *Eur J Cancer* 2014;50:611-621.
- <sup>72</sup>Chamberlain MC. Leptomeningeal metastasis. *Curr Opin Neurol* 2009;22:665-674.
- <sup>73</sup>Jaeckle KA, Phuphanich S, Bent MJ, et al. Intrathecal treatment of neoplastic meningitis due to breast cancer with a slow-release formulation of cytarabine. *Br J Cancer* 2001;84:157-163.
- <sup>74</sup>Chamberlain MC, Johnston SK, Van Horn A, Glantz MJ. Recurrent lymphomatous meningitis treated with intra-CSF rituximab and liposomal ara-C. *J Neurooncol* 2009;91:271-277.
- <sup>75</sup>Groves MD, Glantz MJ, Chamberlain MC, et al. A multicenter Phase II trial of intrathecal topotecan in patients with meningeal malignancies. *Neuro-Oncology* 2008;10:208-215.
- <sup>76</sup>Chamberlain MC, Wei-Tao DD, Groshen S. A Phase II trial of intra-CSF etoposide in the treatment of neoplastic meningitis. *Cancer* 2006;31:2021-2027.
- <sup>77</sup>Chamberlain MC. Alpha-Interferon in the treatment of neoplastic meningitis. *Cancer* 2002;94:2675-2680.
- <sup>78</sup>Zagouri F, Sergentanis TN, Bartsch R, et al. Intrathecal administration of trastuzumab for the treatment of meningeal carcinomatosis in HER2-positive metastatic breast cancer: a systematic review and pooled analysis. *Breast Cancer Res Treat* 2013;139:13-22.
- <sup>79</sup>Grommes C, Oxnard GR, Kris MG, et al. "Pulsatile" high-dose weekly erlotinib for CNS metastases from EGFR mutant non-small cell lung cancer. *Neuro Oncol* 2011;13:1364-1369.

**Note: All recommendations are category 2A unless otherwise indicated.**

**Clinical Trials: NCCN believes that the best management of any cancer patient is in a clinical trial. Participation in clinical trials is especially encouraged.**



### PRINCIPLES OF BRAIN TUMOR MANAGEMENT

#### **General**

Patients diagnosed with a tumor involving the brain, spinal cord, and related support structures should be referred to practitioners who are experienced in the diagnosis and management of these lesions.<sup>1</sup> The patient may (and should) be presented with options for care which may include procedures or treatments best done by other specialists. The care options should then be discussed with the patient, and their chosen supports, in a manner that is understandable, as well as culturally and educationally sensitive.

#### **Multidisciplinary Care**

- During the course of their treatment, most patients will be seen by physicians from more than one specialty. Where possible, use of a local brain tumor board, or multidisciplinary clinic facilitates these interactions and allows for input from each of the major neuro-oncology disciplines, as well as allied services (physical/occupational therapy, social work, psychology, nursing) when available, in formulating a plan of care for the patient. When not possible in a single clinic or institution, close and regular communication between the various disciplines involved becomes essential.
- As treatment proceeds, it is important that the patient and family understand the role of each team member. One practitioner should be identified early on as the main point of contact for follow-up care questions. This individual can facilitate referral to the appropriate specialist.
- Offering patients the option of participation in a clinical trial is strongly encouraged. Practitioners should discuss any local, regional and national options for which the patient may be eligible and the advantages and disadvantages of participation. Centers treating neuro-oncology patients are encouraged to participate in large collaborative trials in order to have local options to offer patients.
- As the patient's treatment unfolds, their quality of life is the highest priority and should guide clinical decisions. While responses on imaging are benchmarks of successive therapy, other indicators of success such as overall well being, function in day-to-day activities, social and family interactions, nutrition, pain control, long term consequences of treatment, and psychological issues must be considered.
- Patients should be informed of the possibility of pseudoprogression, its approximate incidence and potential investigations that may be needed in the event that pseudoprogression is suspected. Close follow-up imaging, MR Spectroscopy, PET/CT imaging, and repeat surgery may be necessary if clinically indicated.

<sup>1</sup>Depending upon local referral patterns and available expertise, this physician may be a neurosurgeon, neurologist, medical oncologist, or radiation oncologist.

**Note:** All recommendations are category 2A unless otherwise indicated.

**Clinical Trials:** NCCN believes that the best management of any cancer patient is in a clinical trial. Participation in clinical trials is especially encouraged.

[Continued](#)

**PRINCIPLES OF BRAIN TUMOR MANAGEMENT****Medical Management****1. Corticosteroids**

- **Steroid therapy should be carefully monitored.** If a patient is asymptomatic, steroids may be unnecessary. Careful questioning for subtle symptoms should be undertaken if edema is extensive on imaging. In general, the lowest dose of steroids should be used for the shortest time possible.<sup>2</sup> Downward titration of the dose should be attempted whenever possible. Patients with extensive mass effect should receive steroids for at least 24h before radiation therapy. Patients with high risk of GI side effects (perioperative patients, prior history of ulcers/GI bleed, receiving NSAIDs or anticoagulation) should receive H<sub>2</sub> blockers or proton pump inhibitors. Care should be taken to watch for development of steroid side effects.<sup>3</sup>

**2. Antiepileptic Drugs (AED's)**

- **Seizures are frequent in patients with primary or metastatic brain tumors .** Despite this, studies have shown that the use of older, “traditional” antiepileptic drugs (AED's) including phenytoin, phenobarbital and valproic acid as prophylaxis against seizures in patients who have never had a seizure or who are undergoing neurosurgical procedures is ineffective, and is not recommended. Newer agents (levetiracetam, topiramate, lamotrigine, pregabalin) have not yet been systematically studied. Seizure prophylaxis is not recommended as routine in asymptomatic patients; but reasonable to consider perioperatively.
- **Many AED's have significant effects on the cytochrome P450 system, and may have effects on the metabolism of numerous chemotherapeutic agents such as irinotecan, gefitinib, erlotinib, temsirolimus among others).** Where possible, such enzyme inducing AED's (EIAED's) should be avoided (phenytoin, phenobarbital, carbamazepine), and nonEIAED's should be used instead (levetiracetam, topiramate, valproic acid). Patients should be closely monitored for any adverse effects of the AED's or chemotherapeutic agents.

**3. Endocrine disorders**

- **Endocrinopathies are common with brain tumor patients.** This may be affected by concomitant steroid use as well as radiotherapy, surgery, and certain medical therapies. Patients who present with a declining sense of well being or quality of life should be evaluated not only for abnormalities related to their hypothalamic pituitary and adrenal axis, but also with regard to thyroid and gonad function.

**4. Fatigue (Also see the [NCCN Guidelines for Cancer-Related Fatigue](#))**

- **Fatigue is commonly experienced by brain tumor patients.** This symptom can be severe, persistent, emotionally overwhelming and not related to the degree or duration of physical activity. Screening should be initiated to identify any underlying medical sources of this symptom, after which patients can be taught energy-conservation and organizational skills to help manage this effect. Supervised, moderate exercise may be of assistance for those in otherwise good general medical condition. More data is needed on the use of CNS stimulants and these agents are not routinely recommended

<sup>2</sup>An exception to this rule is in the case of suspected CNS lymphoma. Steroids should be avoided where possible ([see PCNS-1](#)) prior to biopsy, to allow best chance of diagnosis.

<sup>3</sup>Refractory hyperglycemia, skin changes, visual changes, fluid retention, and myopathy. If any of these changes occur, it is imperative to evaluate potential palliative treatments for them and also to evaluate the current dose of steroids to see if it can be reduced in an attempt to mitigate these side effects.

**Note:** All recommendations are category 2A unless otherwise indicated.

**Clinical Trials:** NCCN believes that the best management of any cancer patient is in a clinical trial. Participation in clinical trials is especially encouraged.

[Continued](#)



### PRINCIPLES OF BRAIN TUMOR MANAGEMENT

#### Medical Management---continued

##### 5. Psychiatric disorders (Also see the [NCCN Guidelines for Distress Management](#))

- Depression is common in brain tumor patients. These symptoms are greater than simple sadness or anxiety associated with the diagnosis of a tumor. The vegetative symptoms associated with depression or severe anxiety may become very disabling for the patient and distressing for the family. These symptoms will respond to psychotropic medications as they do in non-tumor patients. If less severe, strong support from behavioral health allies and other qualified counselors is also extremely beneficial. Physicians, and other members of their healthcare teams, should be sensitive to these symptoms and inquire about them in follow-up visits in order to determine if the patient may be a candidate for psychological or psychiatric treatment. Communication between members of the patient's health care team regarding the patient's response to treatment is important.
- Antiepileptic drugs, anxiolytics, some chemotherapy agents, antiemetics and other agents used directly in cancer therapy may affect mental status, alertness and mood. Alterations in thought processes should trigger an investigation for any reversible causes, including endocrine disorders, infection, side effects of medication or tumor progression.

##### 6. Venous thromboembolism (VTE)

- See the [NCCN Guidelines for Venous Thromboembolic Disease](#).

#### Allied Services

- Physical therapy, occupational therapy, and speech therapy may be helpful for many patients with CNS tumors, either benign or malignant. Surgical intervention is not a pre-requisite for referral, and these therapies should not be withheld from patients because of the uncertain course of certain malignant tumors. Many patients with aggressive, malignant primary brain tumors or CNS metastases can benefit from inpatient rehabilitation.
- Practitioners are encouraged to serve as a resource for referrals to social service, tumor support, and educational agencies for their patients. Institutional or community resources that can assist patients and families in dealing with financial, insurance, and legal issues are important.
- Practitioners should be familiar with their state laws concerning seizures and driving so that they can advise patients and families appropriately.
- Practitioners should become familiar with palliative and hospice care resources that are available in their community in order to help educate patients and families that involvement of these services does not indicate a state of hopelessness, of no further treatment or abandonment.

**Note:** All recommendations are category 2A unless otherwise indicated.

**Clinical Trials:** NCCN believes that the best management of any cancer patient is in a clinical trial. Participation in clinical trials is especially encouraged.



# NCCN Guidelines Version 2.2014 Central Nervous System Cancers

## Discussion

### NCCN Categories of Evidence and Consensus

**Category 1:** Based upon high-level evidence, there is uniform NCCN consensus that the intervention is appropriate.

**Category 2A:** Based upon lower-level evidence, there is uniform NCCN consensus that the intervention is appropriate.

**Category 2B:** Based upon lower-level evidence, there is NCCN consensus that the intervention is appropriate.

**Category 3:** Based upon any level of evidence, there is major NCCN disagreement that the intervention is appropriate.

**All recommendations are category 2A unless otherwise noted.**

## Table of Contents

<b>Overview</b> .....	<b>MS-2</b>
Principles of Management .....	MS-2
Treatment Principles .....	MS-2
Tumor Types .....	MS-3
<b>Low-Grade Infiltrative Astrocytomas &amp; Oligodendrogliomas</b> ..	<b>MS-3</b>
Treatment Overview .....	MS-4
NCCN Recommendations .....	MS-6
<b>Anaplastic Gliomas and Glioblastomas</b> .....	<b>MS-6</b>
Treatment Overview .....	MS-7
NCCN Recommendations .....	MS-11
<b>Intracranial Ependymomas</b> .....	<b>MS-12</b>
Treatment Overview .....	MS-12

NCCN Recommendations .....	MS-13
<b>Medulloblastoma and Supratentorial PNET</b> .....	<b>MS-14</b>
Treatment Overview .....	MS-14
NCCN Recommendations .....	MS-15
<b>Primary CNS Lymphomas</b> .....	<b>MS-16</b>
Treatment Overview .....	MS-16
NCCN Recommendations .....	MS-18
<b>Primary Spinal Cord Tumors</b> .....	<b>MS-20</b>
Treatment Overview .....	MS-20
NCCN Recommendations .....	MS-21
<b>Meningiomas</b> .....	<b>MS-21</b>
Imaging .....	MS-22
Treatment Overview .....	MS-22
NCCN Recommendations .....	MS-23
<b>Brain Metastases</b> .....	<b>MS-24</b>
Treatment Overview .....	MS-24
NCCN Recommendations .....	MS-27
<b>Leptomeningeal Metastases</b> .....	<b>MS-29</b>
Treatment Overview .....	MS-29
NCCN Recommendations .....	MS-30
<b>Metastatic Spinal Tumors</b> .....	<b>MS-31</b>
Treatment Overview .....	MS-32
NCCN Recommendations .....	MS-34
<b>References</b> .....	<b>MS-37</b>

### Overview

In the year 2014, an estimated 23,380 people in the United States will be diagnosed with primary malignant brain and other central nervous system neoplasms.<sup>1</sup> These tumors will be responsible for approximately 14,320 deaths. The incidence of primary brain tumors has been increasing over the last 30 years, especially in elderly persons.<sup>2</sup> Metastatic disease to the central nervous system (CNS) occurs much more frequently, with an estimated incidence about 10 times that of primary brain tumors. It is estimated that between 20% and 40% of patients with systemic cancer will develop brain metastases.<sup>3</sup>

### Principles of Management

Primary and metastatic brain tumors are a heterogeneous group of neoplasms with varied outcomes and management strategies. Primary brain tumors range from pilocytic astrocytomas, which are very uncommon, noninvasive, and surgically curable, to glioblastoma multiforme, the most common intraparenchymal brain tumor in adults, which is highly invasive and virtually incurable. Likewise, patients with metastatic brain disease may have rapidly progressive systemic disease or no systemic cancer at all. These patients may have one or dozens of brain metastases, and they may have a malignancy that is highly responsive or, alternatively, highly resistant to radiation therapy (RT) or chemotherapy. Because of this marked heterogeneity, the prognostic features and treatment options for brain tumors must be carefully reviewed on an individual basis and sensitively communicated to each patient. In addition, CNS tumors are associated with a range of symptoms and complications such as edema, seizures, endocrinopathy, fatigue, psychiatric disorders, and venous thromboembolism that can seriously impact patients' quality of life. The involvement of an interdisciplinary team, including neurosurgeons, RT therapists, oncologists, neurologists, or neuroradiologists, is a key factor in the

appropriate management of these patients. For any subtype of malignant brain lesions, the NCCN Panel encourages thorough multidisciplinary review of each patient case once the pathology is available. Further discussion of multidisciplinary care and allied services, as well as guidelines on medical management of various disease complications, can be found in the algorithm section, *Principles of Brain Tumor Management*.

### Treatment Principles

Several important principles guide surgical and RT for adults with brain tumors. Regardless of tumor histology, neurosurgeons generally provide the best outcome for their patients if they remove as much tumor as possible (maximal safe resection), minimize surgical morbidity and ensure an accurate diagnosis by providing sufficient representative tumor tissue. Decisions regarding aggressiveness of surgery for primary brain lesions are complex and depend on the: 1) age and performance status (PS) of the patient; 2) proximity to “eloquent” areas of the brain; 3) feasibility of decreasing the mass effect with aggressive surgery; 4) resectability of the tumor (including the number and location of lesions); and 5) time since last surgery in patients with recurrent disease.<sup>4</sup>

The surgical options include stereotactic biopsy, open biopsy, subtotal resection (STR), or complete resection (gross total resection: GTR). The pathologic diagnosis is critical and may be difficult to determine accurately without sufficient tumor tissue. Review by an experienced neuropathologist is highly recommended. In addition, a postoperative MRI scan, with and without contrast, should be obtained 24 to 72 hours after surgery to document the extent of disease after surgical intervention.

Radiation oncologists use several different treatment modalities in patients with primary brain tumors, including brachytherapy, stereotactic



fractionated RT (SRT), and stereotactic radiosurgery (SRS). Standard fractionated external beam RT (EBRT) is the most common approach, while hypofractionation is emerging as an option for select patients i.e. elderly and patients with compromised performance. RT for patients with primary brain tumors is administered within a limited field (tumor and surround), while whole brain RT (WBRT) and SRS are used primarily for brain metastases.

Clinicians are advised to consult the algorithm sections, *Principles of Brain Tumor Imaging* and *Principles of Brain Tumor Surgery* for further discussion of these diagnostic and treatment modalities. The dose of RT administered varies depending on the pathology as seen in *Principles of Brain Tumor Radiation Therapy*. Appropriate chemotherapeutic and biologic regimens for each tumor subtype are listed under *Principles of Brain Tumor Systemic Therapy*.

### Tumor Types

The NCCN Guidelines for CNS Cancers focus on management of adult CNS cancers: anaplastic gliomas and glioblastoma multiforme, low-grade infiltrative astrocytomas, oligodendrogliomas, ependymomas, brain metastases, leptomeningeal metastases, non-AIDS primary CNS lymphomas (PCNSLs), and metastatic spinal tumors. In versions 2010 and 2011, specific guidelines on managing meningiomas, primary spinal cord tumors, and primitive neuroectodermal tumors (PNETs) excluding esthesioneuroblastomas were added. These guidelines are updated annually to include new information or treatment philosophies as they become available. However, because this field evolves continually, practitioners should use all of the available information to determine the best clinical options for their patients.

### Low-Grade Infiltrative Astrocytomas and Oligodendrogliomas

Diffusely infiltrative low-grade gliomas (i.e., astrocytomas, oligodendrogliomas, mixed oligoastrocytomas) are a diverse group of relatively uncommon malignancies classified as grade II under the WHO grading system.<sup>5</sup> Multivariate analysis of two phase III trials conducted by the EORTC revealed that age  $\geq 40$  years, astrocytoma histology, largest dimension of tumor  $\geq 6$  cm, tumor crossing midline, and presence of neurologic deficit before resection to be unfavorable prognostic factors.<sup>6</sup> In a separate validation study of 203 patients treated in a North American Intergroup trial, high-risk patients as defined by EORTC criteria (more than two risk factors) had a median overall survival of 3.9 years compared to 10.8 years in the low-risk group.<sup>7</sup>

Seizure is a common symptom (81%) of low-grade gliomas, and is more frequently associated with oligodendrogliomas.<sup>8</sup> The median duration from onset of symptoms to diagnosis ranges from 6 to 17 months. These tumors typically are non-enhancing, low-attenuation/signal intensity lesions on CT or MRI scans.

Diffuse astrocytomas are poorly circumscribed and invasive, and most gradually evolve into higher-grade astrocytomas. Although these were traditionally considered benign, they can behave aggressively and will undergo anaplastic transformation within 5 years in approximately half of patients.<sup>9,10</sup> The most common non-infiltrative astrocytomas are pilocytic astrocytomas, which are circumscribed, often surgically resectable, and rarely transform; however, the NCCN algorithm does not encompass pilocytic astrocytomas because these tumors are curable by surgery alone.



Oligodendrogliomas are thought to arise from oligodendrocytes, whereas mixed oligoastrocytomas probably develop from a common glial stem cell. Radiographically, low-grade oligodendrogliomas appear well demarcated, occasionally contain calcifications, and do not enhance with contrast. The typical “fried egg” appearance of these tumors is evident in paraffin but not in frozen sections. Over half of oligodendrogliomas have specific molecular genetic alterations (allelic losses of chromosomes 1p and 19q) that can help distinguish them from other types of gliomas.<sup>11</sup> Grade II oligodendrogliomas have a much better 5-year survival rate (70%) than mixed gliomas (56%) and astrocytomas (37%).<sup>12</sup>

## Treatment Overview

### *Surgery*

The best management strategy for infiltrative low-grade gliomas has yet to be defined.<sup>13</sup> Surgery remains an important diagnostic and therapeutic modality. The primary surgical goal is to provide adequate tissue for a pathologic diagnosis and grading. Needle biopsies are often performed when lesions are in deep or critical regions of the brain. Biopsy results can be misleading, because gliomas often have varying degrees of cellularity, mitoses, or necrosis from one region to another; thus, small samples can provide a lower histologic grade.

The role of maximal tumor resection in low-grade astrocytomas remains unresolved. Because these tumors are relatively uncommon, published series generally include patients treated for decades, which introduces additional variables. For example, the completeness of surgical excision was based on the surgeon’s report in older studies. This approach is relatively unreliable when compared with assessment by modern postoperative imaging studies. Furthermore, most patients also received RT, and thus the net effect of the surgical procedure on outcome is difficult to evaluate. Most of the available retrospective

biomedical literature suggests a survival benefit from aggressive surgical resection,<sup>14-17</sup> although there are data that reported no difference.<sup>18</sup> Maximal safe resection may also delay or prevent malignant progression<sup>19-21</sup> and recurrence.<sup>22</sup>

Biological considerations also favor an attempt at a complete excision of an astrocytoma. First, the tumor may contain higher-grade foci, which may not be reflected in a small specimen. Second, complete excision may decrease the risk of future dedifferentiation to a more malignant astrocytoma.<sup>19</sup> Third, a large tumor burden is removed, which also may enhance the effect of RT. As a result of these considerations, the general recommendation for treating an astrocytoma is to first attempt as complete an excision of tumor as possible (based on postsurgical MRI verification) without compromising function. Low-grade oligodendrogliomas are often amenable to total excision due to their location in the frontal lobes and distinct tumor margins. However, for tumors that involve eloquent areas, a total removal may not be feasible and an aggressive approach could result in neurologic deficits.

### *Radiation Therapy*

No consensus exists regarding the proper timing of postoperative EBRT in low-grade gliomas. Some oncologists advocate immediate fractionated EBRT, whereas others delay RT until tumor progression is evident. A randomized trial of early versus delayed RT in adult patients was conducted by the EORTC.<sup>23</sup> In this EORTC 22845 trial, patients with low-grade gliomas were randomly assigned to either 54-Gy postoperative RT or no immediate therapy. In an interim analysis, the 5-year disease-free survival was better with immediate postoperative RT (44% vs. 37%;  $P = .02$ ). However, overall survival was similar indicating that deferring postoperative therapy can be an option for a selected group of patients. Long-term follow-up of these patients showed that overall survival was not increased in patients who had received early

RT (7.4 vs. 7.2 years); however, seizures were better controlled in these patients.<sup>24</sup> Although delaying RT in young, healthy patients without progressive neurologic decline can be controversial, there is a consensus to proceed with immediate postoperative RT in older patients after a less-than-total resection, because their survival is as poor as patients with anaplastic astrocytoma. When RT is deferred, regular follow-up is essential for patients receiving observation alone after resection. There is however a consensus that high-risk patients with low-grade gliomas as defined by the EORTC benefit with respect to both PFS and OS with early up-front RT.

When RT is given to patients with low-grade gliomas, it is administered with restricted margins. A T2-weighted and/or fluid-attenuated inversion recovery (FLAIR) MRI scan is the best means for evaluating tumor extent, because these tumors enhance weakly or not at all. The clinical target volume is defined by the FLAIR or T2-weighted tumor with a 1 to 2 cm margin. Every attempt should be made to decrease the RT dose outside the target volume. This can be achieved with 3-dimensional planning or intensity-modulated RT (IMRT). The standard RT dose for low-grade astrocytomas is 45 to 54 Gy, delivered in 1.8 to 2.0 Gy fractions. The selection of 45 to 54 Gy as the standard dose range is based on its relative safety when applied to a limited volume of the brain and on the lack of evidence for increased efficacy with higher doses.<sup>25,26</sup> In a randomized trial conducted by the EORTC in patients with low-grade astrocytomas, no survival difference was observed when 45 Gy was compared with 59.4 Gy.<sup>27</sup> With a median follow-up of 6 years, the 5-year disease-free survival and overall survival were the same. Patients were randomly assigned to receive either 1) 50.4 Gy in 28 fractions; or 2) 64.8 Gy in 36 fractions in another combined NCCTG (North Central Cancer Treatment Group), RTOG, and ECOG study.<sup>28</sup> With a median follow-up of 6.3 years, the 5-year disease-free survival

and overall survival were again the same indicating that lower doses of RT are probably as effective as higher doses of RT for low-grade gliomas. Enthusiasm for SRS in low-grade gliomas has waned due to insufficient evidence for therapeutic advantage.<sup>29</sup>

### **Systemic Therapy**

Chemotherapy is not a traditional mainstay of upfront treatment for low-grade gliomas. There are some data that support temozolomide as adjuvant therapy, and it is included as a category 2B recommendation based on non-uniform panel consensus. A phase II trial of temozolomide achieved a 61% objective response rate in 46 patients.<sup>30</sup> Alternate protracted dosing schedules have produced response rates of 20% to 52%.<sup>31,32</sup> RTOG conducted a clinical trial (RTOG 9802) that allowed observation alone for favorable patients (age <40 with gross total resection [GTR]) and randomly assigned unfavorable patients (age ≥40 following any resection or younger patients who were subtotaly resected) to postoperative RT with or without combination PCV (lomustine [CCNU], procarbazine, and vincristine). In a report of early results, PCV improved progression-free survival but not overall survival,<sup>33</sup> although data suggest that PCV may confer survival benefits in the long term.<sup>34,35</sup>

In the absence of randomized trial data, a number of regimens are currently considered acceptable for recurrence or progressive disease, including temozolomide,<sup>31,36</sup> lomustine or carmustine, PCV, and platinum-based therapy.<sup>37-39</sup>

Patients with low-grade oligodendrogliomas, especially those with 1p/19q deletions, may represent favorable candidates for chemotherapy in light of good response rates reported in literature however this has never been prospectively determined.<sup>40-45</sup>

### NCCN Recommendations

#### *Primary and Adjuvant Treatment*

When possible, maximal safe resection is recommended for low-grade infiltrative astrocytomas and oligodendrogliomas, and the actual extent of resection should be documented with a T2-weighted or FLAIR MRI scan within 72 hours after surgery. If the tumor is found to have components of oligodendroglioma, 1p/19q deletion testing should be considered, as it is a favorable prognostic factor. Managing the disease by serial observation alone is appropriate for selected patients. The NCCN Panel also discussed the role of the isocitrate dehydrogenase 1 or 2 (IDH1, IDH2) genes in low-grade gliomas. Mutations in the IDH genes are common in patients and are reported to be a significant marker of positive prognosis.<sup>46</sup> However, routine IDH testing as a recommendation is not included in the algorithm at this point because its impact on treatment is still unclear.

The following are considered low-risk features for low-grade gliomas: age <40 years, Karnofsky Performance Status (KPS)  $\geq 70$ , minor or no neurologic deficit, oligodendroglioma or mixed oligoastrocytoma, tumor dimension <6 cm, 1p and 19q co-deleted, and IDH1 or 2 mutated. Patients are categorized as having high risk if they have three or more of the following: age  $\geq 40$  years, KPS under 70, tumor larger than or equal to 6 cm, tumor crossing midline, or preoperative neurologic deficit of more than minor degree. Other adverse factors to consider include increased perfusion on imaging and one or no deletion on 1p and 19q, wild type IDH1 or 2. If GTR is achieved, most low-risk patients may be observed without adjuvant therapy. However, close follow-up is essential as over half of these patients eventually progress.<sup>47</sup> Low-grade gliomas can behave aggressively in high-risk patients and adjuvant RT or chemotherapy (category 2B for chemotherapy) is recommended for this group, although select patients may be observed.

Patients who only had a stereotactic biopsy, open biopsy, or subtotal excision should be treated with immediate fractionated EBRT or chemotherapy (category 2B), particularly if their symptoms are uncontrolled or progressive. Because of concerns about the neurotoxicity of RT,<sup>48</sup> patients with asymptomatic residual tumors or stable symptoms may also be followed until their disease progresses. Patients should be followed using MRI every 3 to 6 months for 5 years and then at least annually.

#### *Recurrence*

At the time of recurrence, surgery is recommended (if resectable) followed by chemotherapy if patients have previously had fractionated EBRT. At progression following chemotherapy, the options are: 1) consider another regimen; 2) consider reirradiation; and 3) palliative/best supportive care. Reirradiation is a good choice if the patient has been progression-free for over 2 years after prior RT, the new lesion is outside the target of previous RT, or the recurrence is small and geometrically favorable. If the patient has not previously received RT, they should first undergo surgery if the lesion is resectable. Patients may receive RT or chemotherapy after surgery (category 2B for chemotherapy).

### **Anaplastic Gliomas and Glioblastomas**

Anaplastic astrocytomas (grade III) and glioblastomas (grade IV astrocytomas) are the most common of the primary malignant brain tumors in adults, accounting for 6% and 54% of all gliomas, respectively.<sup>49</sup> Glioblastoma is the most lethal brain tumor with only a third of patients surviving for one year and less than 5% living beyond 5 years. The 5-year survival rate for anaplastic astrocytoma is 27%. The most important prognostic factors identified in an analysis of 1578 patients are histologic diagnosis, age, and PS.<sup>50</sup>



High-grade astrocytomas diffusely infiltrate surrounding tissues and frequently cross the midline to involve the contralateral brain. Patients with these neoplasms often present with symptoms of increased intracranial pressure, seizures, or focal neurologic findings related to the size and location of the tumor and to associated peritumoral edema. These tumors usually do not have associated hemorrhage or calcification but produce considerable edema and mass effect and enhance after the administration of intravenous contrast (>65% of anaplastic gliomas and 96% of glioblastoma). Tumor cells have been found in the peritumoral edema, which corresponds to the T2-weighted MRI abnormalities. As a result, this volume is frequently used to define RT portals.

It is difficult to assess the results of therapy using CT scans or MRI scans, because the extent and distribution of contrast enhancement, edema, and mass effect are more a function of blood-brain barrier (BBB) integrity than of changes in the size of the tumor. Thus, other factors that exacerbate BBB dysfunction (such as surgery, RT, and tapering of corticosteroids) can mimic tumor progression by increasing contrast enhancement, T2-weighted abnormalities, and mass effect.

Anaplastic oligodendrogliomas are relatively rare; they are characterized by high cellularity, nuclear pleomorphism, frequent mitosis, endothelial proliferation, and necrosis. On histopathologic assessment, these tumors can be confused with glioblastoma multiforme; however, characteristic allelic losses of chromosomes 1p and 19q are present in anaplastic oligodendrogliomas.<sup>11</sup> This distinct histologic subtype has a much better prognosis compared to anaplastic astrocytomas and glioblastomas due to its marked sensitivity to chemotherapy;<sup>51</sup> half of the patients are alive at 5 years.<sup>52</sup>

## Treatment Overview

### **Surgery**

The goals of surgery are to obtain a diagnosis, alleviate symptoms related to increased intracranial pressure or compression, increase survival, and decrease the need for corticosteroids. A prospective study in 565 patients with malignant glioma showed that aggressive surgery is a strong prognostic factor when compared with biopsy alone ( $P < .0001$ ).<sup>53</sup> Retrospective analyses also suggest that GTR lengthens survival and is especially effective in patients with good PS.<sup>54-56</sup> Unfortunately, the infiltrative nature of high-grade astrocytomas frequently renders gross total removal difficult. On the other hand, total resection is often possible for oligodendrogliomas, because most occur in the frontal lobes and the tumors are frequently well demarcated.

Unfortunately, nearly all glioblastomas recur. At recurrence, reoperation may improve the outcome for select patients.<sup>57</sup> According to an analysis by Park et al,<sup>58</sup> tumor involvement in specific critical brain areas, poor Karnofsky score, and large tumor volume were associated with unfavorable re-resection outcomes.

### **Radiation Therapy**

Fractionated EBRT after surgery is standard adjuvant therapy for patients with high-grade astrocytomas. Use of RT is based on two randomized trials conducted in the 1970s that showed extension in survival. Walker et al<sup>59</sup> compared postoperative supportive care, carmustine (BCNU), RT, and RT plus BCNU in 303 patients; median survival was 14 weeks, 18.5 weeks, 35 weeks, and 34.5 weeks, respectively. Another trial of 118 patients also found a benefit in median survival with RT following surgery compared to no RT (10.8 vs. 5.2 months).<sup>60</sup> The typical dose is 60 Gy in 1.8 to 2.0 Gy fractions. Some centers use 55.8 to 59.4 Gy in 1.8 Gy fractions or 57 Gy in 1.9 Gy fractions for grade III astrocytomas or when gliomatosis is present. Use



of hypofractionated courses of RT has been shown to be efficacious in older patients with glioblastoma.<sup>61-63</sup> Typical schemes are 34 Gy in 10 fractions, 40.05 Gy in 15 fractions or 50 Gy in 20 fractions. Studies including a radiosurgery boost or brachytherapy boost to conventional RT did not show a survival benefit.<sup>64,65</sup>

There is a lack of prospective data for re-irradiating recurrent gliomas. Based on retrospective patient series, repeat RT using modern high-precision techniques such as fractionated stereotactic RT may be a palliative option for select patients with good PS and small recurrent tumors.<sup>66,67</sup>

### **Chemotherapy/Systemic Therapy**

Traditionally, chemotherapy was felt to be of marginal value in the treatment of newly diagnosed patients with high-grade gliomas, but this perception has shifted. In particular, combined chemoradiation has emerged as a new standard of care for patients with 1p/19q co-deleted anaplastic oligodendroglioma or oligoastrocytoma as well as good performance status non-elderly glioblastoma.

Most earlier trials studied nitrosourea-based chemotherapy regimens. The Medical Research Council reported results from the largest randomized trial of adjuvant chemotherapy in high-grade gliomas.<sup>68</sup> In this study, 674 patients were randomly assigned either to RT alone or to RT plus PCV. No survival benefit was seen with the addition of PCV, even in patients with anaplastic astrocytomas. In contrast, 2 meta-analyses reviewed data from randomized trials of high-grade glioma patients, and both found a modest survival benefit when chemotherapy was added to postoperative RT.<sup>69,70</sup> Specifically, the Glioma Meta-Analysis Trialists Group reviewed 12 studies involving approximately 3000 patients and reported an absolute increase in 1-year survival from 40% to 46% and a 2-month increase in median survival when

chemotherapy was added to postoperative RT (HR, 0.85; 95% CI, 0.78–0.91;  $P < .0001$ ).<sup>69</sup> An earlier analysis by Fine and colleagues on 16 randomized trials also found a 10% and 9% increase in survival at 1 and 2 years, respectively.<sup>70</sup>

### *Implanted Wafers*

Other routes of chemotherapy drug delivery have been evaluated. Local administration of carmustine using a biodegradable polymer (wafer) placed intraoperatively in the surgical cavity has demonstrated a statistically significant improvement in survival for patients with recurrent high-grade gliomas (31 vs. 23 weeks; adjusted HR, 0.67;  $P = .006$ ).<sup>71</sup> As a result, the U.S. Food and Drug Administration (FDA) approved the carmustine wafer for this indication. A phase III placebo-controlled study in 32 patients with malignant glioma showed a statistically significant prolongation of survival when BCNU polymer was used as initial therapy in combination with RT.<sup>72</sup> A larger phase III trial in 240 newly diagnosed patients with malignant glioma also found a statistically significant improvement in median survival from 11.6 months in the placebo group to 13.9 months in the BCNU wafer-treated group.<sup>73</sup> This benefit was maintained 2 and 3 years after implantation.<sup>74</sup> On the basis of these studies, the FDA extended the approval of BCNU polymer wafers for use in malignant gliomas as initial therapy. Clinicians and patients should be aware that carmustine can potentially interact with other agents resulting in increased toxicity (see below). Implantation of the wafer may however preclude future participation of clinical trials of adjuvant therapy.

### *Temozolomide*

Temozolomide, an alkylating (methylating) agent, is now the standard of care in conjunction with postoperative RT for younger, good performance patients with glioblastoma. Stupp et al<sup>75</sup> conducted a phase III, randomized study that assessed the drug in 573 glioblastoma

patients' age  $\leq 70$  years with a WHO PS of 2 or less. Patients received either 1) daily temozolomide administered concomitantly with postoperative RT followed by 6 cycles of adjuvant temozolomide; or 2) RT alone. Side effects for temozolomide include hair loss, nausea, vomiting, headaches, fatigue, and anorexia. Due to the risk of lymphocytopenia and subsequent opportunistic infection, prophylaxis against *Pneumocystis carinii* pneumonia (PCP) is required when the agent is administered with RT. The chemoradiation arm resulted in a statistically better median survival (14.6 vs. 12.1 months) and 2-year survival (26.5% vs. 10.4%) when compared with RT. Final analysis confirmed the survival advantage at 5 years (10% vs. 2%).<sup>76</sup> However, the study design does not shed light on which is responsible for the improvement: temozolomide administered with RT, following RT, or both. The temozolomide dose used in this trial is 75 mg/m<sup>2</sup> daily concurrent with RT, then 150 to 200 mg/m<sup>2</sup> post-irradiation on a 5-day schedule every 28 days. Alternate schedules such as a 21/28 dose-dense regimen or a 50 mg/m<sup>2</sup> continuous daily schedule have been explored in a phase II trial for newly diagnosed glioblastoma.<sup>77</sup> A comparison of the dose-dense 21/28 and standard 5/28 schedules have been completed with RTOG 0525 and the results demonstrated no improvement with the post-irradiation dose-dense temozolomide arm when compared to the standard temozolomide arm.<sup>78</sup>

Wick et al<sup>79</sup> performed a phase III trial of sequential radiochemotherapy in 318 patients with anaplastic gliomas. The three randomized arms were: 1) RT; 2) PCV; and 3) temozolomide. At progression, patients in arm 1 received PCV or temozolomide, while patients in arms 2 and 3 were irradiated. The three strategies resulted in comparable time-to-progression and survival. Another phase III study conducted by the same group (NOA-08) randomized 412 patients with anaplastic astrocytoma (11%) or glioblastoma (89%) who were older than 65 years

and had a good performance score (KPS  $\geq 60$ ) to receive temozolomide alone or RT alone.<sup>80</sup> Temozolomide treatment was non-inferior to RT in terms of survival.

The international Nordic trial randomized 291 patients with glioblastoma and good PS across 3 groups: temozolomide, hypofractionated RT, or standard RT.<sup>63</sup> Patients older than 70 years had better survival with temozolomide or fractionated RT compared to standard RT.

MGMT (O-6-methylguanine-DNA methyltransferase) is a DNA repair enzyme that can cause resistance to DNA-alkylating drugs. Oligodendrogliomas frequently exhibit MGMT hypermethylation and low expression levels, which may explain its enhanced chemosensitivity.<sup>81</sup> In the temozolomide arm of both the Nordic and German trials, patients with MGMT promoter methylation had longer survival than those without (9.7 vs. 6.8 months; HR, 0.56; 95% CI, 0.34–0.93).<sup>63</sup> This difference was not observed in the RT groups.

There are no published data directly comparing the benefit of temozolomide to lomustine or carmustine for postoperative chemoradiation in patients with newly diagnosed anaplastic astrocytomas. This RTOG study (RTOG 9813) was prematurely discontinued due to lack of availability of BCNU.

There have been safety concerns regarding adjuvant use of temozolomide in patients with implanted carmustine wafer. However, temozolomide combined with RT after carmustine wafer placement appeared to be safe in multiple studies.<sup>82-84</sup> For patients old than 70 years but with good performance, there is some evidence from small monocentric studies suggesting the usefulness of temozolomide in addition to adjuvant RT despite old age.<sup>85,86</sup> For frail patients, temozolomide may be administered alone. A retrospective review of

patients age 70 years or older with mean Karnofsky score of 70 found no survival difference between those receiving RT alone and those taking monthly temozolomide only.<sup>87</sup> Given the susceptibility of elderly patients to RT-induced neurotoxicity, especially when the PS is poor, chemotherapy alone appears to be a reasonable option.

### *Combination Chemoradiation*

Improved survival observed in 2 randomized clinical trials established combined PCV chemotherapy and RT as the new standard for treating patients with pure or mixed anaplastic oligodendroglioma harboring the 1p/19q co-deletion. RTOG 9402 randomized 291 patients to PCV followed by immediate RT or RT alone.<sup>88</sup> No difference was observed between the two arms for the entire cohort. However, an unplanned analysis showed that patients with the co-deletion lived longer than those without, and among patients with co-deleted tumors, median survival was doubled when PCV was added to RT (14.7 vs. 7.3 years; HR, 0.59; 95% CI, 0.37–0.95;  $P = .03$ ). This difference was not observed for patients without 1p/19q co-deletion.

Similarly, EORTC 26951 randomly assigned 368 patients with pure or mixed anaplastic oligodendroglioma to RT or RT followed by PCV.<sup>89</sup> At a median follow-up of 140 months, overall survival was longer in the combination arm than in the RT arm (42.3 vs. 30.6 months; HR, 0.75; 95% CI, 0.60–0.95). Median survival was not reached in patients with co-deleted tumors who received PCV/RT compared to 112 months for those in the RT group. No survival advantage was found with the addition of PCV among patients without the co-deletion.

### *Systemic Therapy for Recurrence*

Unfortunately, currently available chemotherapy does not provide cures. Patients with malignant gliomas eventually recur or progress. In addition to temozolomide<sup>36,90,91</sup> and nitrosoureas,<sup>71,92</sup> regimens that are commonly

used as second-line or salvage chemotherapy include combination PCV,<sup>93</sup> cyclophosphamide (category 2B recommendation),<sup>94,95</sup> and platinum-based regimens (category 2B recommendation).<sup>39</sup> Anaplastic gliomas may also be treated by irinotecan<sup>96</sup> or etoposide.<sup>97</sup>

Bevacizumab, an anti-angiogenic agent, received accelerated approval in 2009 for recurrent glioblastoma based on two phase II studies. AVF 3708g randomized 167 patients to bevacizumab with or without irinotecan. MRI-defined objective response was achieved in 28% and 38% of patients, respectively.<sup>98</sup> Median survival was around 9 months, similar to that of a previous phase II trial.<sup>99</sup> A published report of the other pivotal study (NCI 06-C-0064E) recorded a median survival of 31 weeks in 48 heavily-pretreated patients.<sup>100</sup> In the case that patients with good performance status who have received bevacizumab monotherapy showed signs of radiographic progression, continuation of bevacizumab therapy may prevent rapid neurologic deterioration. Bevacizumab in combination with irinotecan, carmustine or lomustine, carboplatin (category 2B) or temozolomide has also been used in anaplastic gliomas.<sup>101-108</sup> These combinations may be considered for patients who have failed bevacizumab monotherapy. While efficacious, bevacizumab is associated with potentially serious adverse events including hypertension, impaired wound healing, colonic perforation, and thromboembolism.

### *Alternating Electric Field Therapy*

In 2011, the FDA approved a portable medical device that generates low-intensity electric fields termed Tumor Treating Fields (TTF) for the treatment of recurrent glioblastoma. Approval was based on results of a clinical trial that randomized 237 patients to TTF or chemotherapy.<sup>109</sup> Similar survival was observed in the two arms, and TTF therapy was associated with lower toxicity and improved quality of life. Due to the lack of efficacy, not all Panelists recommended the treatment.

### NCCN Recommendations

#### **Primary Treatment**

When a patient presents with a clinical and radiologic picture suggestive of high-grade glioma, neurosurgical input is needed regarding the feasibility of maximal safe tumor resection. Whenever possible, major tumor removal should be performed. One exception is when CNS lymphoma is suspected; a biopsy should be performed first and management should follow the corresponding pathway if the diagnosis is confirmed. If high-grade glioma is supported by intraoperative frozen section diagnosis, BCNU wafer placement is an option (category 2B). The extent of tumor debulking should be documented with a postoperative MRI scan within 72 hours after surgery, with and without contrast. If major tumor removal is deemed too risky, a stereotactic or open biopsy or subtotal resection should be performed to establish the diagnosis. Multidisciplinary consultation is encouraged once the pathology is available.

#### **Adjuvant Therapy**

After surgical intervention, the choice of adjuvant therapy depends on the tumor pathology, status of the 1p/19q loci, and PS of the patient. For patients with 1p/19q co-deleted anaplastic oligodendroglioma or oligoastrocytoma, fractionated EBRT plus PCV given before or after RT is a category 1 recommendation. The Panel recommends adjuvant PCV after RT as per EORTC 26951 over intensive neoadjuvant PCV used by RTOG 9402 due to better tolerance. Fractionated RT plus concurrent temozolomide is an acceptable option, while PCV or temozolomide alone is designated category 2B. In the case of anaplastic astrocytoma, anaplastic oligodendroglioma or oligoastrocytoma without 1p/19q co-deletion, fractionated EBRT remains the standard (category 1). Other choices include fractionated RT plus concurrent temozolomide, and PCV or temozolomide chemotherapy (deferred RT). Patients with a

poor performance score (below 60) can be managed by RT (hypofractionation is preferred over standard fractionation), PCV or temozolomide chemotherapy (category 2B), or palliative/best supportive care. The optimal duration of treatment with temozolomide for anaplastic astrocytoma is unknown.

If glioblastoma is diagnosed, the adjuvant options mainly depend on the patient PS. Patients with good PS (KPS  $\geq 60$ ) are further stratified by age. Fractionated RT plus concurrent and adjuvant temozolomide is a category 1 recommendation for patients aged 70 years or younger. The panel noted that although data are focused on 6 cycles of post-irradiation temozolomide, 12 cycles are increasingly common, especially in recent clinical trial designs. Benefit of treatment with temozolomide for glioblastomas beyond 6 months is unknown. Options for those  $>70$  years include fractionated RT plus concurrent and adjuvant temozolomide (category 2A for this group), hypofractionated RT (category 1), or chemotherapy with deferred RT. Patients opting for chemotherapy should receive temozolomide if they had MGMT methylation.

For patients with glioblastoma and with KPS below 60, options include fractionated EBRT, chemotherapy, or palliative/best supportive care. In the absence of data, panelists debated whether chemoradiation is appropriate for elderly patients with poor PS and ultimately agreed not to include this option.

The panel noted that given the complexity of symptoms and handicaps that can arise from malignant gliomas, KPS score is a suboptimal measure of fitness for all patients. Similarly, a patient's ability to tolerate toxic therapy does not necessarily correlate with chronologic age.<sup>110</sup>

### ***Follow-up and Recurrence***

Patients should be followed closely with serial MRI scans (at 2–6 weeks post-irradiation, then every 2–4 months for 2–3 years, then less frequently) after the completion of RT. Because RT can produce additional BBB dysfunction, corticosteroid requirements may actually increase; therefore, scans may appear worse during the first 3 months after completion of RT even though there is no actual tumor progression. Early MRI scans allow for appropriate titration of corticosteroid doses, depending on the extent of mass effect and brain edema. Later scans are used to identify tumor recurrence. Early detection of recurrence is warranted, because local and systemic treatment options are available for patients with recurrent disease. However, MR spectroscopy, MR perfusion, or PET can be considered to rule out RT-induced necrosis or “pseudoprogression.”<sup>111,112</sup>

Management of recurrent tumors depends on the extent of disease and patient condition. For local recurrence, repeat resection, with or without wafer placement in the surgical bed, can be performed if possible. Following re-resection, or if the local recurrence is unresectable, poor performance patients should undergo palliative/best supportive care without further active treatment. If PS is favorable, systemic chemotherapy may be administered (especially for anaplastic oligodendrogliomas); re-irradiation is a category 2B option to consider if prior RT achieved a good/durable response. Patients with recurring glioblastoma may also consider alternating electric field therapy (category 3). In the case of diffuse or multiple recurring lesions, the options are: 1) palliative/best supportive care for poor performance patients; 2) systemic chemotherapy; 3) surgery to relieve mass effect; or 4) consider alternating electric field therapy for glioblastomas (category 3).

All patients should receive best supportive care.

### **Intracranial and Spinal Ependymomas**

Ependymomas constitute up to 4% of adult CNS tumors and 10% of pediatric CNS tumors.<sup>113</sup> In adults, ependymomas occur more often in the spinal canal than in the intracranial compartment (two-thirds infratentorial). These tumors can cause hydrocephalus and increased intracranial pressure, mimic brainstem lesions, cause multiple cranial nerve palsies, produce localizing cerebellar deficits, and cause neck stiffness and head tilt if they infiltrate the upper portion of the cervical cord.<sup>114,115</sup> This section focuses on adult intracranial and spinal grade II differentiated (termed ependymomas) and grade III (termed anaplastic ependymomas) ependymomas. Grade I ependymomas (subependymomas and myxopapillary) are non-infiltrative and can be cured by resection alone.

### **Treatment Overview**

#### ***Surgery***

There is a paucity of robust studies regarding this uncommon disease, but multiple case series have reported that patients with totally resected tumors tend to have the best survival for both low- and high-grade ependymomas.<sup>116-120</sup> Supratentorial ependymomas generally have a poorer prognosis than their infratentorial counterparts, because a greater proportion of supratentorial lesions are of high grade and because larger volumes of residual disease tend to be present after surgical resection at this location.

#### ***Radiation Therapy***

The survival benefits of RT following surgical recovery have been established for anaplastic ependymomas and suboptimally resected tumors, although much of the data are derived from pediatric patients. Rodriguez et al<sup>121</sup> reviewed over 2400 cases of ependymomas in the SEER database and reported the lack of RT to be a poor prognostic

factor in partially resected patients (HR = 1.75;  $P = .024$ ). The short-term and 10-year survival rate after RT reached over 70% and 50%, respectively.<sup>122-124</sup> The value of RT is more controversial for differentiated ependymomas,<sup>117,125</sup> with data demonstrating improved survival mainly for subtotaly resected tumors.<sup>118,121</sup>

In the past, the standard practice was to irradiate the entire craniospinal axis or administer WBRT. However, studies have demonstrated that: 1) local recurrence is the primary pattern of failure; 2) spinal seeding is uncommon in the absence of local failure; 3) the patterns of failure are similar in patients with high-grade tumors who are treated with local fields or craniospinal axis irradiation; and 4) spinal metastases may not be prevented by prophylactic treatment.<sup>126-128</sup> Prophylactic craniospinal or WBRT does not lead to improvement in survival compared to conformal regional RT with higher doses in modern studies of non-disseminated disease.<sup>119,125,129</sup> Typical craniospinal irradiation scheme includes 36 Gy in 1.8 Gy fractions to the whole brain and spine, followed by limited field irradiation to spine lesions to 45 Gy. For intracranial ependymomas, the primary brain site should receive a total of 54 to 59.4 Gy in 1.8 to 2.0 Gy fractions. For spinal ependymomas, patients should receive 45 to 50.4 Gy in 1.8 Gy fractions. Higher doses up to 60 Gy are reasonable for spinal tumors below the conus medullaris. Proton beam craniospinal irradiation may be considered when toxicity is a concern.

SRS have been used as a boost after EBRT or to treat recurrence with some success, although long-term results are still lacking.<sup>130-132</sup>

### **Systemic Therapy**

Research on chemotherapeutic regimens has also centered on pediatric ependymomas, while the role of chemotherapy in the treatment of adult patients remains poorly defined. No study has demonstrated a survival

advantage with the addition of chemotherapy to irradiation in newly diagnosed tumors. However, chemotherapy is sometimes considered as an alternative to palliative/best supportive care or RT in the recurrence setting. Possible options include platinum-based regimens (cisplatin or carboplatin),<sup>133,134</sup> etoposide,<sup>135</sup> lomustine or carmustine,<sup>134</sup> bevacizumab,<sup>136</sup> and temozolomide.

### **NCCN Recommendations**

#### ***Primary and Adjuvant Treatment***

Whenever possible, maximal safe resection should be attempted with contrast-enhanced brain image verification within 24 to 72 hours. Spine MRI should be delayed by at least 2 to 3 weeks after surgery to avoid post-surgical artifacts. Due to the established relationship between the extent of resection and outcome, multidisciplinary review and re-resection (if possible) should be considered if MRI shows that initial resection is incomplete. If maximal resection is not feasible at diagnosis due to anatomic or other factors, biopsy (stereotactic or open) or subtotal resection should be performed. If feasible, reoperation should be considered to complete resection.

The adjuvant treatment algorithm revolves around the extent of surgical resection, histology, and staging by cranial spinal MRI and cerebrospinal fluid (CSF) cytology. For spinal ependymomas, brain MRI is necessary to determine if these are drop metastases from the brain. CSF dissemination develops in up to 15% of intracranial ependymomas. Lumbar puncture for CSF cytology, delayed at least 2 weeks after surgery, should be performed for anaplastic ependymoma and/or if resection is suboptimal. CSF analysis is also indicated for grade II ependymomas following GTR if spine MRI is negative. However, lumbar puncture may be contraindicated in some cases (for example, posterior fossa mass). Patients who have undergone GTR and have negative findings for MRI and CSF may be observed if the tumor is supratentorial

or spinal or consider adjuvant limited-field fractionated EBRT if the tumor is intracranial or myxopapillary. Patients with spinal ependymomas that have been totally resected usually do not require adjuvant RT as the recurrence rate is low. Limited-field fractionated EBRT is the appropriate postoperative management for patients with anaplastic ependymoma and/or subtotal resection, provided MRI (spine MRI for intracranial ependymoma and brain MRI for spinal ependymoma) and CSF findings are both negative. Craniospinal RT is mandatory when MRI spine or CSF results reveal metastatic disease, regardless of histology and extent of resection.

### ***Follow-up and Recurrence***

Follow-up of ependymoma depends on the extent and location of the disease. For localized disease, contrast-enhanced brain and spine MRI (if initially positive) should be done 2 to 3 weeks postoperatively and then every 3 to 4 months for one year. The interval can then be extended to every 4 to 6 months in the second year and then every 6 to 12 months, depending on the physician's concern regarding the extent of disease, histology, and other relevant factors. If tumor recurrence in the brain or spine is noted on one of these scans, restaging by brain and spine MRI as well as CSF analysis is necessary. Resection is recommended if possible. RT should be administered (after surgery if performed) if not given originally; SRS may be considered in geometrically favorable cases.

Upon disease progression, several options are available depending on the histologic type, extent of disease, age of the patient, and PS: 1) RT (including SRS or reirradiation of previously irradiated sites), 2) chemotherapy for patients who are refractory to surgery or RT, or 3) palliative or best supportive care.

### **Medulloblastoma and Supratentorial PNET**

Cranial PNETs are embryonal neoplasms showing varying degrees of differentiation. They are described by their location as infratentorial (medulloblastomas) and supratentorial (cerebral neuroblastoma, pineoblastoma or esthesioneuroblastoma). The WHO classification system further divided these tumors into histologic variants.<sup>5</sup> CNS PNETs are infrequent in children and very rare in adults, with an overall incidence of 0.26 per 100,000 person-years reported by the Central Brain Tumor Registry of the United States (CBTRUS).<sup>137</sup> Overall, it represents only 1.8% of all brain tumors, although it is the most common type among pediatric brain malignancies.

About half of the affected patients will present with elevated intracranial pressure. Headache, ataxia, and nausea are commonly observed symptoms.<sup>138</sup> All PNETs of the brain are WHO grade IV, as they are invasive and rapidly growing. They also have the tendency to disseminate through the CSF. Larger retrospective case series of adult patients reported a 10-year survival of 48% to 55% with frequent recurrence beyond 5 years, commonly in the posterior fossa.<sup>139,140</sup>

### **Treatment Overview**

#### ***Surgery***

Evidence in adult patients is meager for this rare disease and there are no randomized trial data, but there is general consensus that surgical resection should be the routine initial treatment to establish diagnosis, relieve symptoms, and maximize local control. Complete resection can be achieved in half of the patients<sup>138,141,142</sup> and is associated with improved survival.<sup>141,143</sup> In addition, surgical placement of a ventriculoperitoneal shunt can be used to treat hydrocephalus.

### **Radiation Therapy**

Adjuvant RT following surgery is the current standard of care, although most studies are based on the pediatric population. The conventional dose is 30 to 36 Gy of craniospinal irradiation and a boost to a total of 54 to 55.8 Gy to the primary brain site.<sup>141,143</sup> A lower craniospinal dose of 23.4 Gy, combined with chemotherapy, has gained popularity for average-risk patients to lessen side effects while maintaining 54 to 55.8 Gy to the posterior fossa,<sup>139,144,145</sup> although one randomized trial found an increased relapse risk with dose reduction.<sup>146</sup> It is reasonable to consider proton beam for craniospinal irradiation where available as it is associated with less toxicity.<sup>147</sup> SRS demonstrated safety and efficacy in a small series of 12 adult patients with residual or recurrent disease.<sup>148</sup>

### **Systemic Therapy**

The use of post-irradiation chemotherapy to allow RT dose reduction is becoming increasingly common especially for children,<sup>144,145</sup> but optimal use of adjuvant chemotherapy is still unclear for adult patients.<sup>138-140,149,150</sup> A phase III study that enrolled over 400 patients between ages 3 and 21 to receive post-irradiation cisplatin-based chemotherapy regimens recorded an encouraging 86% 5-year survival.<sup>151</sup>

Several regimens are in use in the recurrence setting, most of which include etoposide.<sup>152-154</sup> Temozolomide has also been used in this setting.<sup>155</sup> High-dose chemotherapy in combination with autologous stem cell transplantation is a feasible strategy for patients who have had good response with lower doses.<sup>154,156</sup>

## **NCCN Recommendations**

### **Primary Treatment**

MRI scan is the gold standard in the assessment and diagnosis of PNET. The typical tumor shows enhancement and heterogeneity. Fourth ventricular floor infiltration is a common finding related to worse

prognosis.<sup>139,140,150</sup> Multidisciplinary consultation before treatment initiation is advised. Maximal safe resection is recommended wherever possible. Contrast-enhanced brain MRI should be performed within 24 to 72 hours following surgery, but spinal MRI should be delayed by 2 to 3 weeks. Because of the propensity of PNET to CSF seeding, CSF sampling after spine imaging via lumbar puncture is also necessary for staging. Medulloblastoma should be staged according to the modified Chang system using information from both imaging and surgery.<sup>157,158</sup>

### **Adjuvant Therapy**

Patients should be stratified according to recurrence risk for planning of adjuvant therapy (reviewed by Brandes et al<sup>159</sup>). The NCCN Panel agrees that patients with large cell or anaplastic medulloblastoma, supratentorial PNET, disease dissemination, unresectable tumors, or residual tumors over 1.5 cm<sup>2</sup> postsurgery are at heightened risk. These patients should undergo irradiation of the neuraxis followed by chemotherapy. Collection of stem cells before RT may be considered on the condition that RT is not delayed for potential future autologous stem cell reinfusion at disease progression. For patients at average risk, craniospinal RT alone or craniospinal RT with chemotherapy followed by post-irradiation chemotherapy are both viable options.

### **Recurrence and Progression**

There are no robust data supporting an optimal follow-up schedule for PNETs. General guidelines include brain MRI every 3 months for the first 2 years, biannual brain MRI for the next 3 years, then yearly brain scans. If recurrent disease is detected on these scans, CSF sampling is also required. Concurrent spine imaging should be performed as clinically indicated for patients with previous spinal disease. Bone scans, CT scans, and bone marrow biopsies should be conducted as indicated.

Maximal safe resection should be attempted on recurrent brain tumors. High-dose chemotherapy with autologous stem cell rescue may be considered for patients showing no evidence of disease following resection or conventional reinduction chemotherapy. On disease progression, options include chemotherapy alone, RT alone (including SRS), and chemoradiation. Patients with metastases should be managed by chemotherapy or best supportive care such as palliative RT.

### Primary CNS Lymphomas

PCNSL accounts for approximately 3% of all primary CNS tumors. It is an aggressive form of non-Hodgkin's lymphoma that develops within the brain, spinal cord, eye, or leptomeninges without evidence of systemic involvement. Its age-adjusted incidence has seen a three-fold increase over the past 20 years from 0.15 to 0.48 per 100,000, in part due to the impact of HIV infections.<sup>160</sup> Non-immunosuppressed patients have a better prognosis than AIDS-related cases,<sup>161</sup> and survival of this group has improved over the years with treatment advances.<sup>162</sup>

Pathologically, PCNSL is an angiocentric neoplasm composed of a dense monoclonal proliferation of lymphocytes, usually diffuse large B-cells.<sup>163</sup> The tumor is infiltrative and typically extends beyond the primary lesion, as shown by CT or MRI scans, into regions of the brain with an intact BBB. The brain parenchyma is involved in more than 90% of all PCNSL patients, and the condition can be multifocal in more than 50% of cases. Leptomeningeal involvement may occur, either localized to adjacent parenchymal sites or in diffuse form (that is, positive cytology) in up to 30% of patients. Ocular involvement may develop independently in 10% to 20% of patients. Patients with PCNSL can present with various symptoms because of the multifocal nature of the disease. In a retrospective review of 248 immunocompetent patients,

43% had mental status changes, 33% showed signs of elevated intracranial pressure, 14% had seizures, and 4% suffered visual symptoms at diagnosis.<sup>164</sup>

### Treatment Overview

#### *Steroid Administration*

Steroids can rapidly alleviate signs and symptoms of PCNSL and improve PS. However, as these drugs are cytolytic, they can significantly decrease enhancement and size of tumors on CT and MRI scans as well as affect the histologic appearance. In the absence of significant mass effect, it is recommended that steroids be withheld or used judiciously until diagnostic tissue can be obtained if PCNSL is suspected.

#### *Stereotactic Biopsy*

In contrast to the principles previously outlined for invasive astrocytomas and other gliomas, the surgical goals for PCNSL are more modest, with the goal of obtaining diagnostic tissue under minimal risk of morbidity. Currently, most authors recommend stereotactic biopsy as the surgical method of choice.<sup>165</sup> This approach stems from the fact that data do not demonstrate a survival advantage for patients who have had a complete resection or extensive subtotal resection when compared with those who have had only a stereotactic biopsy. In addition, subtotal resection is associated with risk for postoperative neurologic deficits.<sup>164</sup>

#### *Systemic Therapy*

Methotrexate is the most effective agent against PCNSL. It is commonly used in combination with other drugs such as vincristine, procarbazine, cytarabine, rituximab, and ifosfamide, but it may also be administered as monotherapy if toxicity tolerance is a concern.<sup>166-174</sup> High doses of intravenous methotrexate are necessary (3.5 g/m<sup>2</sup> or higher) to



overcome the BBB. Intrathecal methotrexate, when given as prophylaxis in addition to intravenous methotrexate in primary treatment, confers no clinical advantage and is not recommended,<sup>175</sup> but can be useful where CSF cytology yields positive findings.

Renal dysfunction induced by high-dose methotrexate therapy is a potentially lethal medical emergency due to heightened toxicities resulting from a delay in methotrexate excretion. Early intervention with glucarpidase, a recombinant bacterial enzyme that provides an alternative route for methotrexate clearance, has shown efficacy in rapidly reducing plasma concentrations of methotrexate and preventing severe toxicity.<sup>176,177</sup>

Chemotherapy is usually followed by consolidation RT as initial treatment to maximize response and improve outcome. Pre-irradiation chemotherapy, as opposed to post-irradiation chemotherapy, has been emphasized for several theoretical reasons. Chemotherapy given before RT may be less neurotoxic than if given after RT. Also, drug delivery to a PCNSL may be increased before RT, when the BBB is maximally disrupted by the tumor. RT results in tumor regression as well as partial repair and closure of the BBB behind the regressing tumor. Finally, pre-irradiation chemotherapy allows one to assess the efficacy of chemotherapy without the confounding variable of RT.

Because patients older than 60 years often suffer from significant and sometimes lethal neurotoxic effects from consolidation RT,<sup>170,178,179</sup> a number of phase II trials have adopted the approach of chemotherapy with deferred RT.<sup>166,170,180-184</sup> Complete response to chemotherapy ranged from 42% to 61%, with overall survival between 14 and 55 months. However, a high fraction of patients who have forgone initial RT—typically older or with significant comorbidities—will fail to achieve complete response to chemotherapy and later require salvage WBRT.

Unfortunately, even for patients who initially achieved complete response, half of them will eventually relapse. Re-treatment with high-dose methotrexate may be useful in patients who achieved complete response with prior exposure.<sup>185</sup> Several other regimens, including temozolomide,<sup>186,187</sup> rituximab,<sup>188</sup> rituximab plus temozolomide,<sup>189</sup> topotecan,<sup>190</sup> high-dose cytarabine,<sup>191</sup> dexamethasone plus high-dose cytarabine and cisplatin,<sup>192</sup> and pemetrexed<sup>193</sup> have also shown activity in the recurrence or progressive disease setting, but none has been established as a standard of care. Several groups have tested high-dose chemotherapy with autologous stem cell transplantation with some success,<sup>194-196</sup> although evidence of its advantage over conventional treatment is lacking. The panel included this as a category 2B option to consider for progressive or recurrent disease.

There has been discussion among panel members regarding the role of intra-arterial therapy with mannitol disruption of the BBB.<sup>197,198</sup> A series of 149 patients reported a response rate of 82% and overall survival reaching 3.1 years.<sup>197</sup> However, given the complexity of the procedure and the high level of expertise required for safety, the panel opted not to recommend this technique at the present time.

### ***Radiation Therapy***

Historically, WBRT has been the treatment standard to cover the multifocal nature of the disease. The majority of studies demonstrated the limitation of high-dose RT and led to the currently recommended dose of 24 to 36 Gy in 1.8 to 2.0 Gy fractions to the whole brain, without a boost.<sup>168,171,199-202</sup> Although RT alone is useful for initial tumor control, frequent and rapid relapse of the disease led to a short overall survival of 12 to 17 months.<sup>161,201</sup> This dismal outcome has prompted the addition of pre-irradiation methotrexate-based combination chemotherapy in later studies. This approach yields impressive response rates of up to 94% and improved overall survival ranging from

33 to 60 months.<sup>168-171,178,179,199,203,204</sup> However, excessive grade 3 and 4 hematologic toxicity (up to 78%) as well as RT-induced delayed neurotoxicity (up to 32%) sometimes leading to deaths are primary concerns, although most of these studies utilized a high RT dose of more than or equal to 40 Gy. Of note, younger patients (age<60) consistently fare better, and there is a higher incidence of late neurotoxic effects in older patients.

Thiel and colleagues<sup>172</sup> conducted a randomized, phase III, non-inferiority trial of high-dose methotrexate plus ifosfamide with or without WBRT in 318 patients with PCNSL. There was no difference in overall survival (HR, 1.06; 95% CI, 0.80–1.40;  $P = .71$ ), but the primary hypothesis (0.9 non-inferiority margin) was not proven. Patients who received WBRT had a higher rate of neurotoxicity than those who did not (49% vs. 26%).

Although WBRT alone is seldom sufficient as primary treatment and is primarily reserved for patients who cannot tolerate multimodal treatment, it can be effective as salvage therapy following chemotherapy failure, with response rates reaching nearly 75%.<sup>205</sup>

### NCCN Recommendations

#### *Initial Evaluation*

Neuroradiologic evaluation is important in the diagnosis of PCNSL and to evaluate the effectiveness of subsequent therapy. With MRI, the tumor is often isointense or hypointense on T1- and T2-weighted images and enhances frequently.<sup>206</sup> In addition, restricted diffusion can be seen in the area of the enhancing abnormality on diffusion-weighted imaging (DWI) sequences. On a CT scan, PCNSL is usually isodense or hyperdense compared to the brain and enhances in most cases.

Hallmark features include a periventricular distribution, ring enhancement, multiple lesions, and a smaller amount of edema than

might otherwise be expected from a similar-sized metastatic tumor or glioma. If enhanced-contrasted MRI (or contrast CT if MRI is contraindicated) suggests PCNSL, clinicians are advised to hold the use of steroids if possible before diagnosis is established, since the imaging and histologic features of PCNSL can be profoundly affected by these drugs.

A lumbar puncture with evaluation of CSF should be considered, if it can be done safely and without concern for herniation from increased intracranial pressure. The yield for a positive diagnostic test can be increased by the use of molecular markers of monoclonality, such as an immunoglobulin gene rearrangement. If the CSF is negative, consider an ophthalmologic evaluation including a slit-lamp examination to exclude an obvious malignant uveitis. Ocular biopsy should follow suspicious findings. Despite CSF or uveal evaluation, the intracranial lesion often requires a brain biopsy for a definitive diagnosis.<sup>165</sup>

Because the role of maximal surgical resection is limited to alleviating symptoms of raised intracranial pressure or preventing herniation,<sup>164</sup> stereotactic biopsy is generally preferred to minimize invasiveness. Even with molecular marker testing, however, a biopsy can occasionally be falsely negative, particularly if the patient had been treated previously with steroids. Thus, if a biopsy is nondiagnostic, the panel recommended that the steroids be tapered and that the patient be followed closely, both clinically and radiographically. If and when the lesion recurs, the lesion should be promptly rebiopsied before the initiation of steroids. If, on the other hand, no definitive diagnosis of lymphoma is made from biopsy and the patient has not received steroid therapy, work-up for other diagnoses (for example, inflammatory processes) or rebiopsy is recommended.

### **Staging Workup**

Once the diagnosis of PCNSL is established, the patient should undergo a thorough staging workup detailed by The International PCNSL Collaborative Group.<sup>165</sup> This workup involves a complete CNS evaluation including imaging of the entire neuraxis (MRI of the spine with contrast). This should be done before CSF analysis is attempted to avoid post-lumbar puncture artifacts that can be mistaken for leptomeningeal disease on imaging. A slit-lamp eye examination, if not previously performed, should also be done, as well as a lumbar puncture for CSF flow cytometry. In addition, blood work (CBC and chemistry panel) and a CT of the chest, abdomen, and pelvis are required to rule out systemic involvement.

An HIV blood test should also be performed, because both prognosis and treatment of patients with HIV-related PCNSL may be different than that of patients who are otherwise immunocompetent. HIV-positive patients should consider highly active retroviral therapy.

More elaborate tests such as bone marrow biopsy, testicular ultrasound for older men, and body PET scan<sup>207</sup> may be considered (category 2B), although their value in routine workup is still under debate.

### **Primary Treatment**

Treatment should be initiated as soon as possible following confirmation of diagnosis. Given the dramatic effect of steroids on symptom relief, they are commonly administered concurrently with workup. Selection of primary therapy depends on the general health condition and age of the patient. For healthier patients with KPS 40 or higher, a high-dose methotrexate-containing regimen is recommended. In the case of methotrexate induced-renal dysfunction, consider urgent glucarpidase to aid clearance.

Whether one performs WBRT after systemic chemotherapy depends on the responsiveness of the disease to chemotherapy and on the clinical judgment of the medical and radiation oncologists. WBRT may increase neurotoxicity, especially in patients older than 60 years, and may be withheld in the primary setting. If a patient is found to have malignant uveitis, RT to the globe has been the standard recommendation because of poor penetration of systemic chemotherapy into the uveal fluid. However, there are reports of clearance of ocular lymphoma in patients who were treated with systemic high-dose methotrexate.<sup>166</sup> Therefore, with a PCNSL patient who has asymptomatic ocular involvement, a reasonable strategy is to delay RT to the globe in order to see if high-dose methotrexate is effective. Intraocular injection of chemotherapy (category 2B) is also an option. Additionally, if the patient is found to have a malignant pleocytosis in the CSF, direct intrathecal chemotherapy can be considered (category 2B).

Patients with KPS below 40 are too weak to undergo multi-modal treatment. However, these patients are potentially eligible for a change to more aggressive therapy if their PS improves following steroid therapy. If the health condition remains poor, it is recommended that treatment consist of WBRT in order to rapidly induce a response, diminish neurologic morbidity, and optimize quality of life. RT to the globe is advised if ocular involvement is detected. Chemotherapy is also an option; non-methotrexate-based regimens may be used if the patient cannot tolerate methotrexate. If the lumbar puncture or spinal MRI is positive, consider intra-CSF chemotherapy plus focal spinal RT. Best supportive care is another option.

### **Progressive Disease**

For patients who are treated with prior WBRT and ultimately relapse, they may consider further chemotherapy (systemic and/or intrathecal),

reirradiation, or palliative/best supportive care. High-dose therapy with stem cell rescue can also be considered (category 2B).

For patients who were initially treated with high-dose methotrexate-based chemotherapy but did not receive WBRT, the decision about whether to use more chemotherapy or proceed to RT at the time of relapse depends on the duration of response to initial chemotherapy. If a patient had experienced a relatively long-term response of one year or more, then treating either with the same or another regimen is reasonable. However, for patients who either have no response or relapsed within a very short time after systemic therapy, recommendations include WBRT or involved-field RT, with or without chemotherapy.<sup>205</sup> In either case, palliative/best supportive care remains an option, or high-dose chemotherapy with stem cell transplantation may be considered (category 2B).

### Primary Spinal Cord Tumors

Spinal tumors are classified according to their anatomic location as extradural, intradural-extramedullary, and intradural-intramedullary. Extradural tumors are primarily due to metastatic disease and are discussed in the section *Metastatic Spinal Tumors*. This section focuses on intradural primary spinal tumors.

Primary spinal cord tumors are a histologically diverse set of disease that represents 2% to 4% of all primary CNS tumors. The overall incidence is 0.74 per 100,000 person-years with a 10-year survival rate of 64%.<sup>208</sup> Extramedullary lesions, most commonly benign meningiomas, account for 70% to 80% of spinal cord tumors.<sup>209</sup> Astrocytomas (more prevalent in children) and ependymomas (more prevalent in adults) are the most common intramedullary tumors. Clinicians are advised to refer to the corresponding sections in these

guidelines for further details regarding these subtypes, as intracranial and spinal lesions are biologically similar.

Individuals with type I neurofibromatosis, type II neurofibromatosis, and von Hippel-Lindau syndrome are predisposed to form, respectively, spinal astrocytomas, spinal peripheral nerve sheath tumors, spinal ependymomas, and intramedullary hemangioblastomas.

Since 70% of primary spinal cord tumors are low-grade and slow-growing,<sup>208</sup> it is common for patients to suffer pain for months to years before diagnosis. Pain that worsens at night is a classic symptom for intramedullary lesions. Progressive motor weakness occurs in half of the patients, and patients may experience sensory loss with late autonomic dysfunction (incontinence).

### Treatment Overview

#### Observation

Many asymptomatic primary tumors of the spinal cord, especially grade I meningiomas and peripheral nerve sheath tumors, follow an indolent course and can be followed by observation without immediate intervention.

#### Surgery

Surgery is the preferred treatment when the tumor is symptomatic. For lesions that are radiographically well defined, such as ependymoma, WHO grade I astrocytoma, hemangioblastoma, schwannoma, and WHO grade I meningioma, potentially curative, maximal, safe resection is the goal. En bloc total resection yielded excellent local control rates more than 90%.<sup>210-213</sup>

GTR is seldom feasible with grade II or higher astrocytomas because they are infiltrative and poorly circumscribed. In a study of 202 patients

with intramedullary tumors, over 80% of grade I astrocytomas were completely resected, while total resection was achieved in only 12% of grade II tumors.<sup>214</sup> Nevertheless, Benes et al<sup>215</sup> conducted a review of 38 studies on spinal astrocytomas and concluded that maximal safe resection should be attempted whenever possible based on reports of survival benefit.

### **Radiation Therapy**

RT is not recommended as primary therapy because of limited response, unknown histology without surgery, and low RT tolerance of the spinal cord. It is also not advisable following GTR, as tumors that can be excised completely have a low local recurrence rate.

A large retrospective analysis including over 1700 patients with primary spinal gliomas found an association between RT and worse cause-specific and overall survival, although there may be a bias that patients who received RT had more adverse factors.<sup>216</sup> The role of adjuvant RT following incomplete excision or biopsy remains controversial.<sup>215,217,218</sup>

One exception is primary spinal myxopapillary ependymoma, for which postoperative RT has been demonstrated to reduce the rate of tumor progression.<sup>219,220</sup> On the other hand, EBRT is considered a viable option at disease progression or recurrence. SRS has also shown safety and efficacy in several patient series.<sup>221-223</sup>

### **Systemic Therapy**

Unfortunately, evidence on efficacious chemotherapeutic agents for primary spinal cord tumors is too scant for specific recommendations. The panel agrees that salvage chemotherapy should be an option where surgery and RT fail, but there is no consensus on the best regimen. Chemotherapy is best given in the setting of a clinical trial.

### **NCCN Recommendations**

MRI imaging is the gold standard for diagnosis of spinal cord lesions. Asymptomatic patients may be observed (especially for suspected low-grade) or resected, while all symptomatic patients should undergo some form of surgery. The surgical plan and outcome is influenced by whether a clear surgical plane is available.<sup>224</sup> Whenever possible, maximal safe resection should be attempted. Postoperative adjuvant RT is appropriate if symptoms persist after incomplete resection or biopsy, or for patients with asymptomatic, intramedullary, low-grade glioma. Adjuvant RT may also be considered for patients with myxopapillary ependymoma that has been incompletely resected. Patients should be managed according to the pathology results (see *Low-Grade Infiltrative Astrocytomas & Oligodendrogliomas, Anaplastic Gliomas and Glioblastomas, and Intracranial and Spinal Ependymomas*). Those diagnosed with hemangioblastoma should consider screening for von Hippel-Lindau syndrome including neuraxis imaging.

All patients should be followed by sequential MRI scans. At progression or recurrence, re-resection is the first choice. If this is not feasible, conventional EBRT or SRS is the next option. Chemotherapy is reserved for cases where both surgery and RT are contraindicated.

### **Meningiomas**

Meningiomas are extra-axial CNS tumors arising from the arachnoid cap cells in the meninges. They are most often discovered in middle-to-late adult life, and have a female predominance. The annual incidence for males and females reported by CBTRUS are 1.8 and 3.4 per 100,000 people, respectively.<sup>137</sup> In a review of 319 cases using the WHO grading scale, 92% of meningiomas are grade I (benign), 6% are grade II (atypical), and 2% are grade III (malignant).<sup>225</sup> Small tumors are

often asymptomatic, incidental findings.<sup>226</sup> Seizure is a common presenting symptom occurring in 27% of patients.<sup>227</sup>

### Imaging

Brain imaging with contrast-enhanced CT or MRI is the most common method of diagnosing, monitoring, and evaluating response to treatment (review by Campbell et al<sup>228</sup>). The CT scan best reveals the chronic effects of slowly growing mass lesions on bone remodeling.

Calcification in the tumor (seen in 25%) and hyperostosis of the surrounding skull are features of an intracranial meningioma that can be easily identified on a non-contrast CT scan. Nonetheless, MR imaging reveals a number of imaging characteristics highly suggestive of meningioma, and in stereotactic RT articles, MR has been used to operationally define pathology. These MR findings include a tumor that is dural-based and isointense with gray matter, demonstrates prominent and homogeneous enhancement (>95%), has frequent CSF/vascular cleft(s), and often has an enhancing dural tail (60%). However, approximately 10% to 15% of meningiomas have an atypical MRI appearance mimicking metastases or malignant gliomas. In particular secretory meningiomas may have a significant amount of peritumoral edema. Cerebral angiography is occasionally performed, often for surgical planning, as meningiomas are vascular tumors prone to intraoperative bleeding. In some instances preoperative embolization is helpful for operative hemostasis management. Angiographic findings consistent with a meningioma include a dual vascular supply with dural arteries supplying the central tumor and pial arteries supplying the tumor periphery. A “sunburst effect” may be seen due to enlarged and multiple dural arteries, and a prolonged vascular stain or so-called “blushing” can be seen, which results from intratumoral venous stasis and expanded intratumoral blood volume.

Meningiomas are also known to have high somatostatin receptor density, which allows for the use of octreotide brain scintigraphy to help delineate extent of disease and to pathologically define an extra-axial lesion.<sup>229-231</sup> Octreotide imaging with radiolabeled indium or more recently, gallium, may be particularly useful in distinguishing residual tumor from postoperative scarring in subtotally resected/recurrent tumors.

### Treatment Overview

#### Observation

Studies that examined the growth rate of incidental meningiomas in otherwise asymptomatic patients suggested that many asymptomatic meningiomas may be followed safely with serial brain imaging until either the tumor enlarges significantly or becomes symptomatic.<sup>232,233</sup> These studies confirm the tenet that many meningiomas grow very slowly and that a decision not to operate is justified in selected asymptomatic patients. As the growth rate is unpredictable in any individual, repeat brain imaging is mandatory to monitor an incidental asymptomatic meningioma.

#### Surgery

The treatment of meningiomas is dependent upon both patient-related factors (ie, age, PS, medical comorbidities) and treatment-related factors (ie, reasons for symptoms, resectability, goals of surgery). Most patients diagnosed with surgically accessible symptomatic meningioma undergo surgical resection to relieve neurologic symptoms. Complete surgical resection may be curative and is therefore the treatment of choice. Both the tumor grade and the extent of resection impact the rate of recurrence. In a cohort of 581 patients, 10-year progression-free survival was 75% following GTR but dropped to 39% for patients receiving subtotal resection.<sup>234</sup> Short-term recurrences reported for grade I, II, and III meningiomas were 1% to 16%, 20% to 41%, and 56%



to 63%, respectively.<sup>235-237</sup> The Simpson classification scheme that evaluates meningioma surgery based on extent of resection of the tumor and its dural attachment (grades I to V in decreasing degree of completeness) correlates with local recurrence rates.<sup>238</sup> First proposed in 1957, it is still being widely used by surgeons today.

### ***Radiation Therapy***

Safe GTR is sometimes not feasible due to tumor location. In this case, subtotal resection followed by adjuvant EBRT has been shown to result in long-term survival comparable to GTR (86% vs. 88%, respectively), compared to only 51% with incomplete resection alone.<sup>239</sup> Of 92 patients with grade I tumors, Soyuer and colleagues found that RT following subtotal resection reduced progression compared to incomplete resection alone, but has no effect on overall survival.<sup>240</sup>

Because high-grade meningiomas have a significant probability of recurrence even following GTR,<sup>241</sup> postoperative high-dose EBRT (>54 Gy) has become the accepted standard of care for these tumors to improve local control.<sup>242</sup> A review of 74 patients showed that adjuvant RT improves survival in patients with grade III meningioma and in those with grade II disease with brain invasion.<sup>243</sup> The role of post-GTR RT in benign cases remains controversial.

Technical advances have enabled stereotactic administration of RT by linear accelerator (LINAC), Leksell Gamma Knife™, or Cyberknife™ radiosurgery. The use of stereotactic RT (either single fraction or fractionated) in the management of meningiomas continues to evolve. Advocates have suggested this therapy in lieu of EBRT for small (<35 mm), recurrent, or partially resected tumors. In addition, it has been used as primary therapy in surgically inaccessible tumors (ie, base-of-skull meningiomas) or in patients deemed poor surgical candidates because of advanced age or medical comorbidities. A study of about

200 patients compared surgery with SRS as primary treatment for small meningiomas.<sup>244</sup> The SRS arm had similar 7-year progression-free survival compared to GTR and superior survival over incomplete resection. In another study, Kondziolka and colleagues followed a cohort of 972 meningioma patients managed by SRS over 18 years.<sup>245</sup> Half of the patients have undergone previous surgery. SRS provided excellent tumor control (93%) in patients with grade I tumors. For grade II and III meningiomas, tumor control was 50% and 17%, respectively. Another smaller study of 72 patients also reported good 5-year overall and progression-free survival for grade 0 and I meningioma (79% and 95%, respectively).<sup>246</sup> These results suggest that stereotactic RT is effective as primary and salvage treatment for meningiomas smaller than 3.5 cm.

### ***Systemic Therapy***

Targeted therapies that have shown partial efficacy in refractory meningiomas are somatostatin analogues<sup>247,248</sup> and alpha interferon<sup>249</sup>.

## **NCCN Recommendations**

### ***Initial Treatment***

Meningiomas are typically diagnosed by CT or MRI imaging. Biopsy or octreotide scan may be considered for confirmation. For treatment planning, multidisciplinary panel consultation is encouraged. Patients are stratified by the presence or absence of symptoms and the tumor size. Most asymptomatic patients with small tumors (<30 mm) are best managed by observation. If neurologic impairment is imminent, surgery (if accessible) or RT (EBRT or SRS) is feasible. Asymptomatic tumors 30 mm or larger should be surgically resected or observed. Symptomatic disease requires active treatment by surgery whenever possible. Non-surgical candidates should undergo RT.

Regardless of tumor size and symptom status, all patients with surgically resected grade III meningioma (even after GTR) should receive adjuvant RT to enhance local control. Postoperative RT should be considered for the following: 1) asymptomatic grade II tumors, 2) large asymptomatic grade I tumors that have been incompletely resected, and 3) large symptomatic grade I or II tumors that have been incompletely resected. SRS may be used in lieu of conventional RT as adjuvant or primary therapy in asymptomatic cases.

### **Follow-up and Recurrence**

In the absence of data, panelists have varying opinions on the best surveillance scheme and clinicians should follow patients based on individual clinical conditions. Generally, malignant or recurrent meningiomas are followed more closely than grade I and II tumors. A typical schedule for low-grade tumors is MRI every 3 months in year 1, then every 6 to 12 months for another 5 years. Less frequent imaging is required beyond 5 to 10 years.

Upon detection of recurrence, the lesion should be resected whenever possible, followed by RT. Non-surgical candidates should receive RT. Chemotherapy is reserved for patients with an unresectable recurrence refractory to RT. Regimen options include somatostatin analogues (for somatostatin receptor-positive tumors only) and interferon alfa (category 2B). Observation is an option if there is no clinical indication for treatment at recurrence.

### **Brain Metastases**

Metastases to the brain are the most common intracranial tumors in adults and may occur up to 10 times more frequently than do primary brain tumors. Population-based data reported that about 8% to 10% of cancer patients are affected by symptomatic metastatic tumors in the brain.<sup>250,251</sup> A much higher incidence based on autopsy has been

reported. As a result of advances in the diagnosis and treatment, many patients improve with proper management and do not die of progression of these metastatic lesions. Primary lung cancers are the most common source, accounting for half of intracranial metastases, although melanoma has been documented to have the highest predilection to spread to the brain. Diagnosis of CNS involvement is becoming more common in patients with breast cancer as therapy for metastatic disease is improving.<sup>252</sup>

Nearly 80% of brain metastases occur in the cerebral hemispheres, an additional 15% occur in the cerebellum, and 5% occur in the brainstem.<sup>253</sup> These lesions typically follow a pattern of hematogenous spread to the gray-white junction where the relatively narrow caliber of the blood vessels tends to trap tumor emboli. The majority of cases have multiple brain metastases evident on MRI scans. The presenting signs and symptoms of metastatic brain lesions are similar to those of other mass lesions in the brain, such as headache, seizures, and neurologic impairment.

### **Treatment Overview**

#### **Surgery**

Advances in surgical technique have rendered upfront resection followed by WBRT the standard of care for solitary brain metastases. A retrospective analysis of 13,685 patients admitted for resection of metastatic brain lesions showed a decline in in-hospital mortality from 4.6% in the period of 1988 through 1990 to 2.3% in the period of 1997 through 2000.<sup>254</sup> High-volume hospitals and surgeons produced superior outcomes.

Patchell conducted a study that randomized 95 patients with single intracranial metastases to complete resection alone or surgery plus adjuvant WBRT.<sup>255</sup> Postoperative RT was associated with dramatic



reduction in tumor recurrence (18% vs. 70%;  $P < .001$ ) and likelihood of neurologic deaths (14% vs. 44%;  $P = .003$ ). Overall survival, a secondary endpoint, showed no difference between the arms. Comparison of surgery plus WBRT versus WBRT alone is discussed in the WBRT section.

In the case of multiple lesions, the role of surgery is more restricted to obtaining biopsy samples or relieving mass effect due to large symptomatic metastases. However, evidence from retrospective series suggested survival benefits from tumor resection for selected patients of good prognosis with up to three metastatic sites.<sup>256,257</sup>

#### ***Stereotactic Radiosurgery***

The advent of SRS offered a minimally invasive option as opposed to surgery. Patients undergoing SRS avoid the risk of surgery-related morbidity. Late side effects such as edema and RT necrosis are uncommon.<sup>258</sup>

Accumulating evidence suggests that low disease volume is a better selection criterion for SRS than a low number of metastatic lesions. A multivariate analysis of 205 patients who received SRS for 4 or more brain metastases demonstrated total treatment volume to be the most significant prognostic factor of survival, while the number of metastases did not reach significance.<sup>259</sup> The same group conducted another analysis that identified a favorable subgroup of patients with a total treatment volume less than 7 cc and less than 7 brain lesions. These patients had significantly prolonged median survival (13 months) than other patients (6 months;  $P < .00005$ ).<sup>260</sup> A cohort study revealed that patients with a total SRS-treated volume of less than 5 cc or 5 to 10 cc survived longer than those with a total treated volume greater than 10 cc.<sup>261</sup> No survival difference was observed between patients with a single metastasis or multiple metastases. Another group analyzed

patients divided by their number of brain lesions and found no difference in survival times or local control rates among the groups after SRS treatment.<sup>262</sup> However, patients with more than 15 lesions had a higher risk of developing new lesions and distant disease progression.

Taken together, patients with multiple lesions but a low total volume of disease may be amenable to SRS. Additionally, patients with a favorable histology of the primary tumor (such as breast cancer) or controlled primary tumors can often benefit from SRS regardless of the number of brain metastases present.<sup>263,264</sup> Some brain metastases of radio-resistant primary tumors such as melanoma and renal cell carcinoma have also been shown to achieve good local control with SRS.<sup>265</sup> Other predictors of longer survival with SRS include younger age, good PS, and primary tumor control.<sup>259,263,264,266</sup>

In a randomized Japanese study of 132 patients with 1 to 4 metastatic brain tumors smaller than 3 cm, addition of WBRT to SRS did not prolong median survival compared to SRS alone (7.5 months vs. 8.0 months, respectively).<sup>267</sup> However, 1-year brain recurrence rate was lowered in the WBRT plus SRS arm (47% vs. 76%;  $P < .001$ ). Another small randomized trial of 58 patients with 1 to 3 brain metastases was stopped early due to a significant decline in learning and memory function among the group receiving both SRS and WBRT compared to the SRS group (52% vs. 24%).<sup>268</sup> Analysis showed that SRS plus WBRT was associated with better 1-year recurrence-free survival (73%) than SRS alone (27%). A third trial recruited 359 patients with 1 to 3 metastatic brain lesions who underwent surgery or SRS.<sup>269</sup> They were randomized to either adjuvant WBRT or observation. Compared to the observation arm, intracranial relapse rates and neurologic mortality were lower in the WBRT arm, but overall survival and duration of functional independence were similar. A meta-analysis concluded no overall survival improvement with the addition of WBRT to SRS.<sup>270</sup>



Retrospective comparative studies showed that SRS plus WBRT resulted in equivalent if not better survival compared with surgery and WBRT.<sup>271-273</sup> SRS also conferred a significant improvement in local control, especially for patients with radiosensitive tumors or solitary brain lesions. A prospective observational study of 1194 patients reported no difference in overall survival between patients with 2 to 4 metastatic brain lesions and those with 5 to 10 lesions treated with SRS alone (HR, 0.97; 95% CI, 0.81–1.18;  $p$  non-inferiority  $< .0001$ ).<sup>274</sup> SRS alone compared to resection plus WBRT was evaluated in a randomized controlled trial by Muacevic et al.<sup>275</sup> The study was stopped prematurely due to poor accrual. In the final analysis based on 64 patients with solitary brain metastases, radiosurgery alone was less invasive and resulted in equivalent survival and local control, but it was associated with a higher rate of distant relapse.

Several patient series have demonstrated local control rates greater than 70% with SRS in the recurrence setting for patients with good PS and stable disease who have received prior WBRT.<sup>276-281</sup>

### **Whole Brain Radiation Therapy**

Historically, WBRT was the mainstay of treatment for metastatic lesions in the brain. It continues to play multiple roles in the modern era, such as primary intervention where surgery or SRS is not feasible (e.g. polymetastatic brain metastases), as adjunctive therapy to prevent recurrence, and as treatment for recurrent disease.

Three randomized trials investigated the effectiveness of WBRT with or without surgery in patients with single brain metastases. In a study of 48 patients, Patchell et al<sup>282</sup> demonstrated that surgery followed by WBRT lengthened overall survival (40 vs. 15 weeks in WBRT arm;  $P < .01$ ) and functional dependence (38 vs. 8 weeks;  $P < .005$ ), as well as decreased recurrence (20% vs. 52%;  $P < .02$ ) compared to RT alone.

Similarly, combined treatment led to longer survival and functional independence in another randomized study by Vecht and colleagues ( $n=63$ ).<sup>283</sup> The greatest difference was observed in patients with stable disease; median survival was 12 months versus 7 months, and functional independence was 9 months versus 4 months. A third study of 84 patients found no difference in survival between the two strategies; however, patients with extensive systemic disease and lower performance level were included, which likely resulted in poorer outcomes in the surgical arm.<sup>284</sup>

The impact of SRS boost in addition to WBRT was evaluated in two published randomized controlled studies. A multi-institutional trial by RTOG (RTOG 9508) randomly assigned 333 patients with 1 to 3 brain metastases to WBRT plus SRS or WBRT only.<sup>285</sup> Despite the inclusion of larger tumors (3–4 cm) that are not favorable to SRS, the authors found a significant survival benefit in the combined arm (6.5 vs. 4.9 months;  $P = .04$ ) when treating a single metastases; this benefit was not observed in patients with multiple (2 or 3) lesions. A much smaller trial of 27 patients with 2 to 4 lesions found no significant difference in survival, although SRS did extend time to local failure (36 vs. 6 months;  $P = .0005$ ).<sup>286</sup> Overall, no difference in overall survival was reported between the 2 approaches in a meta-analysis of the 2 trials.<sup>287</sup> However, the addition of SRS to WBRT significantly improved local control and performance status. SRS plus WBRT also prolonged overall survival of patients with single brain metastasis compared to WBRT alone (6.5 vs. 4.9 months;  $P = .04$ ).

Taken together, WBRT in conjunction with surgery or SRS leads to better clinical outcomes than WBRT alone for good performance patients with solitary metastatic intracranial lesions. However, many patients are not candidates for resection because of the inaccessibility



# NCCN Guidelines Version 2.2014

## Central Nervous System Cancers

of the tumor, extensive systemic disease, or other factors. WBRT is the main choice of primary therapy for this patient group.

No randomized data are available in the recurrent setting, but case series reported 31% to 70% of symptom-relieving response to irradiation.<sup>288-290</sup>

### **Systemic Therapy**

Systemic therapy is rarely used as primary therapy for brain metastases. In randomized studies, addition of carboplatin or temozolomide to WBRT did not improve overall survival compared to RT alone,<sup>291,292</sup> although there have been reports of increase in progression-free survival or radiologic response with temozolomide.<sup>292,293</sup> Many tumors that metastasize to the brain are not very chemosensitive or have been already heavily pretreated with organ specific effective agents. Poor penetration through the BBB is an additional concern. As such, chemotherapy is usually considered as a last line of therapy for recurrent disease when other options have been exhausted (i.e., surgery, SRS, RT). The choice of agent depends on the histology of the primary tumor. Carmustine wafer implantation is a reasonable option at recurrence when resection is considered.<sup>294</sup>

Among various agents, temozolomide may be useful in some patients with previously untreated brain metastases from metastatic melanoma.<sup>295</sup> Temozolomide given on a prolonged schedule in combination with thalidomide has been tested in a phase II study of patients with brain metastases, but the high toxicity and lack of response rendered the regimen inappropriate.<sup>296</sup>

A study of high-dose methotrexate in patients mostly with breast cancer achieved disease control in 56% of patients.<sup>297</sup> Other agents shown to

have activity in breast cancer include platinum plus etoposide<sup>298,299</sup> and capecitabine with or without lapatinib.<sup>300-302</sup>

A phase I/II study of topotecan plus WBRT has shown a 72% response rate in 75 patients with brain metastases.<sup>303</sup> Unfortunately, a follow-up phase III trial was closed early due to slow accrual.<sup>304</sup>

Rapid advancements in melanoma have produced effective systemic options for metastatic disease. These immunotherapeutic agents (ipilimumab) and BRAF inhibitors (dabrafenib and vemurafenib) have demonstrated activity in melanoma that has metastasized to the brain.<sup>305-307</sup>

### **NCCN Recommendations**

#### **Workup**

Patients who present with a single mass or multiple lesions on MRI or CT imaging suggestive of metastatic cancer to the brain, and who do not have a known primary, require a careful systemic workup with chest x-ray or CT, abdominal or pelvic CT, or other tests as indicated. FDG-PET can be considered if there is more than one brain lesion and no primary has yet been found. If no other readily accessible tumor is available for biopsy, a stereotactic or open biopsy resection is indicated to establish a diagnosis. Among patients with a known history of cancer and if there are concerns regarding the diagnosis of CNS lesions, a stereotactic or open biopsy resection or subtotal resection is also needed. Because brain metastases are often managed by multiple modalities, the NCCN Panel encourages multidisciplinary consultation prior to treatment for optimal planning.

#### **Treatment for Limited (1-3) Metastatic Lesions**

For patients with limited systemic disease or for whom reasonable systemic treatment options exist, aggressive management should be

strongly considered. For surgical candidates, high-level evidence supports category 1 recommendations for surgical resection plus postoperative WBRT and for SRS plus WBRT if only one brain lesion is involved. Other options include SRS alone or SRS following resection (category 2B). Macroscopic total removal is the objective of surgery. The choice between open resection and SRS depends on multiple factors such as tumor size and location. The best outcome for SRS is achieved for small, deep lesions at institutions with experienced staff. If the tumor is unresectable, WBRT and/or radiosurgery can be used.

Patients with progressive extracranial disease whose survival is <3 months should consider best supportive care or be treated with WBRT alone, but surgery may be considered for symptom relief. In patients with systemic cancers and druggable targets e.g. epidermal growth factor receptor mutations in non-small cell lung cancer and BRAF mutations in metastatic melanoma, targeted therapy in neurologically asymptomatic patients with brain metastases is considered reasonable before administration of radiotherapy.

Patients should be followed with MRI every 2 to 3 months for 1 year and then as clinically indicated. Closer follow-up every 2 months is particularly helpful for patients treated with SRS alone.<sup>268</sup> Recurrence on radiograph can be confounded by treatment effects of SRS. Consider tumor tissue sampling if there is a high index of suspicion of recurrence. Upon detection of recurrent disease, prior therapy clearly influences the choice of further therapies. Patients with recurrent CNS disease should be assessed for local versus systemic disease, because therapy will differ. For local recurrences, patients who were previously treated with surgery only can receive the following options: 1) surgery, 2) single-dose or fractionated SRS, 3) WBRT, or 4) chemotherapy. However, patients who previously received WBRT probably should not undergo WBRT at recurrence due to concern regarding neurotoxicity. If the

patient had previous SRS with a durable response for >6 months, reconsider SRS if imaging supports active tumor and not necrosis. Repeat SRS to a prior location is a category 2B recommendation. The algorithm for distant brain recurrences branches depending on whether patients have either 1 to 3 lesions or more than 3 lesions. In both cases, patients may receive WBRT or consider local/systemic chemotherapy, but patients with 1 to 3 recurrent tumors have the additional options of surgery or SRS.

WBRT should be used (30–45 Gy, given in 1.8–3.0 Gy fractions) depending on the patient's PS, if this modality was not used for initial therapy. Local or systemic chemotherapy may be considered for select patients, if the multiple lesions cannot be controlled by a combination of surgery and radiosurgery.<sup>308</sup>

If systemic CNS disease progression occurs in the setting of limited systemic treatment options and poor PS, palliative or best supportive care is the first option. WBRT may be administered if the patients have not been previously irradiated. For patients who have received prior WBRT, re-irradiation is an option only if they had a positive response to the first course of RT treatment.

### ***Treatment for Multiple (>3) Metastatic Lesions***

All patients diagnosed with more than three metastatic lesions should be treated with WBRT or SRS as primary therapy. The standard regimens for WBRT are 30 Gy in 10 fractions or 37.5 Gy in 15 fractions. For patients with poor neurologic performance, a more rapid course of RT can be considered (20 Gy, delivered in 5 fractions). SRS may be considered in patients with good PS and low overall tumor volume. Palliative neurosurgery should be considered if a lesion is causing a life-threatening mass effect, hemorrhage, or hydrocephalus.



After WBRT or SRS, patients should have a repeat contrast-enhanced MRI scan every 3 months for 1 year. If a recurrence is found, the algorithm branches depending on whether patients have 1) systemic disease progression with limited systemic treatment options; or 2) stable systemic disease or reasonable systemic treatment options. For patients with systemic disease progression, options include palliative/best supportive care or reirradiation. For patients with stable systemic disease, options include surgery, reirradiation, or chemotherapy.

### Leptomeningeal Metastases

Leptomeningeal metastasis or neoplastic meningitis refers to the multifocal seeding of the leptomeninges by malignant cells. It is known as leptomeningeal carcinomatosis or carcinomatous meningitis when these cells originate from a solid tumor. When it is related to a systemic lymphoma, it is called lymphomatous meningitis, and when associated with leukemia, it is termed leukemic meningitis. Leptomeningeal metastasis occurs in approximately 5% of patients with cancer.<sup>309</sup> This disorder is being diagnosed with increasing frequency as patients live longer and as neuroimaging studies improve. Most cases arise from breast and lung cancers; melanoma has the highest rate of leptomeningeal spread.<sup>310,311</sup>

Tumor cells gain access to the leptomeninges by hematogenous dissemination, lymphatic spread, or direct extension. Once these cells reach the CSF, they are disseminated throughout the neuraxis by the constant flow of CSF. Infiltration of the leptomeninges by any malignancy is a serious complication that results in substantial morbidity and mortality. Cranial nerve palsies, headaches, cerebral disturbances, mental changes, and motor weakness are among the most common presenting symptoms.<sup>309</sup> The median survival of patients diagnosed with

this disorder is <3 months with death resulting from progressive neurologic dysfunction, but may be extended by early detection and intervention.<sup>310,311</sup>

### Treatment Overview

The goals of treatment in patients with leptomeningeal metastases are to improve or stabilize the neurologic status of the patient and to prolong survival. Unfortunately, there is a lack of standard treatments due to meager evidence in literature. Because treatment is palliative, aggressive chemotherapy should only be given to patients most likely to benefit (see *Patient Stratification*).

### Radiation Therapy

RT is mainly given for symptom alleviation, CSF flow correction, or for debulking to facilitate chemotherapy.<sup>311-313</sup>

### Surgery

The role of neurosurgery for leptomeningeal metastases is mainly to place an intraventricular catheter and subcutaneous reservoir for drug administration.<sup>314</sup> This is preferred over lumbar punctures because of improved drug delivery, safety, superior pharmacokinetics, lower inter-patient variability, and patient comfort.<sup>315</sup>

### Systemic Therapy

Chemotherapy can reach the whole neuraxis and can improve outcome of patients. Intrathecal (intra-CSF) chemotherapy is widely used, although drugs with good CNS penetration, particularly organ-specific targeted therapies, may be administered systemically in high doses. Intrathecal therapy can involve either administration via a lumbar puncture or intraventricular injections via an Ommaya reservoir. However, both intra-CSF therapy and high-dose systemic therapy are



associated with significant toxicity or complications and are therefore restricted to patients with good PS.

Agents used for intra-CSF therapy are often organ-specific with good penetration capacity. The Panel included options deemed appropriate based on moderate benefit: methotrexate for breast cancer, lymphoma, and leukemia<sup>316-318</sup>; cytarabine and liposomal cytarabine for lymphoma and leukemia<sup>317</sup>; thiotepa,<sup>318</sup> rituximab for lymphoma<sup>319</sup>; topotecan<sup>320</sup>; etoposide<sup>321</sup>; trastuzumab for breast cancer<sup>322</sup>; and interferon alfa.<sup>323</sup> Interferon alfa received a category 2B designation due to concerns of its toxicity and limited evidence of efficacy.

Breast cancers<sup>297</sup> and lymphomas<sup>324</sup> are also particularly responsive to high-dose methotrexate. In addition, weekly pulse erlotinib have been used for metastatic non-small cell lung cancer with EGFR exon 19 or exon 21 deletions (category 2B).<sup>325</sup>

## **NCCN Recommendations**

### ***Patient Evaluation***

Patients present with signs and symptoms ranging from injury to nerves that traverse the subarachnoid space, direct tumor invasion of the brain or spinal cord, alter the local blood supply, obstruct normal CSF flow pathways leading to increased intracranial pressure, or interfere with normal brain function. Patients should have a physical examination with a careful neurologic evaluation and neuraxis imaging. MRI of the brain and spine should also be performed if intra-CSF chemotherapy is being considered. A definitive diagnosis is most commonly made by lumbar puncture if it is safe for the patient. The CSF protein is typically increased, and there may be a pleocytosis or decreased glucose levels. The CSF cytology is positive approximately 50% of the time with the first lumbar puncture, and 90% of the time after repeated CSF examinations in affected patients.<sup>313</sup> Clinicians should be aware that

lumbar punctures may be contraindicated in patients with anticoagulation, thrombocytopenia, or bulky intracranial disease. In these cases, suspicious CSF biochemical results combined with suggestive clinical and/or radiologic features should be taken into consideration. Although a positive CSF cytology in patients with solid tumors is virtually always diagnostic, reactive lymphocytes from infections (for example, herpes zoster infection) can often be mistaken for malignant lymphocytes.

### ***Patient Stratification***

Once the diagnosis has been established, the patient's overall status should be carefully assessed to determine how aggressively the carcinomatous or lymphomatous meningitis should be treated. Unfortunately, this disease is most common in patients with advanced, treatment-refractory systemic malignancies for whom treatment options are limited. In general, fixed neurologic deficits (such as cranial nerve palsies or paraplegia) do not resolve with therapy, although encephalopathies may improve dramatically. As a result, patients should be stratified into "poor-risk" and "good-risk" groups. The poor-risk group includes patients with KPS below 60; multiple, serious, major neurologic deficits; extensive systemic disease with few treatment options; bulky CNS disease; and neoplastic meningitis related to encephalopathy. The good-risk group includes patients with KPS over or equal to 60, no major neurologic deficits, minimal systemic disease, and reasonable systemic treatment options. Many patients fall in between these 2 groups, and clinical judgment will dictate how aggressive their treatment should be.

### ***Treatment***

Patients in the poor-risk group are usually offered palliative/supportive care measures. Fractionated EBRT to symptomatic sites (eg, to the

whole brain for increased intracranial pressure or to the lumbosacral spine for a developing cauda equina syndrome) can be considered.

Good-risk patients should receive fractionated EBRT to symptomatic sites and to areas of bulky disease identified on neuroimaging studies. If an intraventricular catheter was placed, a CSF flow scan should be strongly considered to ensure correct flow of chemotherapy.

For patients with a normal CSF flow scan and otherwise stable disease, surgical implantation of a subcutaneous reservoir and ventricular catheter (SRVC) should be considered for intrathecal chemotherapy administration. Induction intrathecal chemotherapy should be given for 4 to 6 weeks.. Alternately, patients with breast cancer or lymphoma may receive high-dose methotrexate or craniospinal RT. Craniospinal RT is also an appropriate option for patients with leukemia. The patient should be reassessed clinically and with a repeat CSF cytology. Because the cytology is much less likely to be positive from the SRVC than from the lumbar subarachnoid space, it is critical that it be sampled from the lumbar spine. Neuraxis imaging can also be considered for sites that were previously positive on a radiograph.

If negative cytology is achieved after induction, continue the induction chemotherapy for another month before switching to maintenance intrathecal chemotherapy. The CSF cytology status should be followed every month. If the patient is clinically stable or improving after induction and there is no clinical or radiologic evidence of progressive leptomeningeal disease, the patient should receive another 4 weeks of “induction” intrathecal chemotherapy or should consider switching intrathecal drugs for 4 weeks. This regimen should be followed by maintenance therapy and monthly cytology if the cytology has converted to negative or is improving (still positive) while the patient is clinically stable.

CSF flow abnormalities are common in patients with neoplastic meningitis and often lead to increased intracranial pressure. Administering chemotherapy into the ventricle of a patient with a ventricular outlet obstruction increases the patient’s risk for leukoencephalopathy. In addition, the agent administered will not reach the lumbar subarachnoid space where the original CSF cytology was positive. CSF flow scans are easily performed in most nuclear medicine departments. Indium-111-DTPA is administered into the SRVC, imaging of the brain and spine is performed immediately after injection, and then imaging is done again at 4 and 24 hours. If significant flow abnormalities are seen, fractionated EBRT can be administered to the sites of obstruction before repeating a CSF flow scan. High-dose methotrexate remains an option for patients with breast cancer or lymphoma, as normal CSF flow is not required to reach cytotoxic concentrations. Patients with breast cancer, leukemia, or lymphoma may receive craniospinal RT as an alternative. If CSF flow normalizes after RT, which occurs most commonly in radiosensitive neoplasms, intrathecal chemotherapy commences. If significant flow abnormalities remain, then the patient should be treated as a poor-risk patient (ie, with supportive measures or RT).

### ***Progressive Disease***

If the patient’s clinical status is deteriorating from progressive leptomeningeal disease or if the cytology is persistently positive, the clinician has several options: 1) RT to symptom sites, 2) systemic chemotherapy, or 3) palliative or best supportive care.

### **Metastatic Spinal Tumors**

Bone metastases are a growing problem among cancer patients due to increasing life expectancy, with the spine being the most frequently affected site. In a report of 832 patients who died of malignancies,

vertebral involvement was found in 36% upon autopsy.<sup>326</sup> Spinal metastases primarily arise from breast, lung, prostate, and renal cancers.<sup>327,328</sup> Extradural lesions account for about 95% of spinal tumors, mostly in the thoracic region.

Some patients are found to have vertebral involvement as an asymptomatic, incidental finding. However, for most affected patients, pain is the primary presenting symptom preceding neurologic dysfunction. Three types of pain have been classically defined. Local pain due to tumor growth is often described as a constant, deep aching that improves with steroid medications. Mechanical back pain varies with movement and position and is attributed to structural spinal instability. While seldom responsive to steroids, mechanical pain can be alleviated by surgical stabilization. Radicular pain is a sharp or stabbing sensation that occurs when nerve roots are compressed by the tumor. Patients may experience any one or a combination of these types of pain.

Spinal cord compression is the most debilitating complication of spine metastases. It affects 5% to 10% of all patients with cancer, with over 20,000 cases diagnosed each year in the United States.<sup>329</sup> The majority of patients initially complain of progressive radicular pain.<sup>330</sup> This is followed by neurologic symptoms such as motor weakness and sensory loss, and may even include autonomic bladder dysfunction. If left untreated, neurologic deficits rapidly progress to paralysis. Unfortunately, a study of 319 patients with cord compression revealed significant delay in the report of initial pain (3 months) as well as diagnosis (2 months) that can lead to irreversible spinal cord damage.<sup>331</sup> Therefore, it is paramount that the clinician watches for early suspicious signs and establish prompt diagnosis by spine MRI. Once diagnosed, spinal cord compression is considered a medical emergency;

intervention should be implemented immediately to prevent further neurological decline.

### Treatment Overview

Dissemination to the spinal column is largely incurable. Therefore, the goals of treatment are palliation and improvement of quality of life through preservation of neurologic function, pain relief, and stabilization of mechanical structure. One exception is slow-growing cancers (mainly renal cell carcinoma) with solitary spinal metastasis, for which surgery may achieve possible cure.<sup>332</sup>

The type and aggressiveness of the primary tumor often dictates the choice of treatment, as different cancers have varying sensitivities to systemic therapy and RT. In addition, patient characteristics including PS and comorbidities will determine whether they can tolerate surgery and, if so, which surgical technique should be used.

### Surgery

There is general consensus that a patient should have a life expectancy of at least three months to be a surgical candidate. Paraplegia for over 24 hours is an exclusion criterion due to low chances of improvement when prolonged neurologic deficits exist before surgery.<sup>333</sup> Patients with hematologic malignancies should also be excluded, as they are best managed by RT or chemotherapy. Because estimation of life expectancy can be difficult, several groups have developed prognostic scoring systems to help predict surgical outcomes.<sup>334-337</sup>

Posterior laminectomy has been widely used in the past but is now obsolete due to frequent complications and lack of benefit. Modern surgical techniques enable surgeons to achieve 360° decompression of the spinal cord, and stabilization can be performed concomitantly, if required. The development of a plethora of spinal implants composed of



high-quality materials such as titanium greatly improve reconstruction outcome. The surgical approach—anterior, posterior, or combined/circumferential—is primarily determined by disease anatomy.<sup>338,339</sup>

Sundaresan and colleagues<sup>332</sup> reported favorable results using a variety of surgical approaches on 80 patients with solitary spine metastases. Both pain and mobility were improved in the majority of patients. Overall survival reached 30 months, with 18% of patients surviving 5 years or more. The best outcome was observed in patients with kidney and breast cancers.

Surgery followed by adjuvant EBRT has emerged as a highly effective approach in relieving spinal cord compression and restoring function, especially for solid tumors. A meta-analysis including 24 surgery cohort studies and 4 RT studies found that patients are twice as likely to regain ambulatory function after surgery than RT alone.<sup>340</sup> However, data also revealed significant surgery-related mortality (6.3%) and morbidity (23%). In another review of literature from 1964 to 2005, anterior decompression with stabilization plus RT was associated with superior outcome over RT alone or laminectomy, achieving 75% mean improvement in neurologic function, but high surgical mortality rate (mean 10%) was also reported.<sup>341</sup>

To date, only one relevant randomized trial has been reported.<sup>342</sup> Approximately 100 patients with metastatic spinal compression were randomized to surgery plus postoperative RT or RT alone. Compared to the RT group, significantly more patients in the surgery group regained walking ability (84% vs. 57%;  $P = .001$ ) and for a longer period of time (median 122 days vs. 13 days;  $P = .003$ ). The impressive results were obtained with strict eligibility criteria. The study excluded patients with radiosensitive tumors, neurologic deficits for 24 hours, multiple spinal

tumors, lesions only compressing spinal roots, and prior RT to the vertebrae. Although studies demonstrated high efficacy of surgery, the formidable complications related to surgery cannot be overlooked. Using the Nationwide Inpatient Sample all-payor database, Patil et al<sup>343</sup> reviewed data of over 26,000 patients who had undergone surgery for spinal metastases. The in-hospital mortality and complication rates were 5.6% and 22%, respectively. The most common complications were pulmonary (6.7%) and hemorrhages or hematomas (5.9%). Clearly, careful individual patient selection based on life expectancy and overall health is warranted.

### ***Radiation Therapy***

Traditionally, EBRT has been the main form of treatment for spinal metastases. In the modern surgery era, RT alone is often not sufficient in achieving decompression or stabilization (see above), but it is routinely used as adjuvant therapy following surgery as it is difficult to obtain wide negative margins. Given the potential impact of RT on wound healing, most studies posed an interval of one to three weeks between resection and subsequent RT.<sup>344</sup>

An excellent response to RT alone for spinal compression was reported by Marazano and colleagues.<sup>345</sup> Three hundred patients were randomized to a short-course (8 Gy x 2 days) or split-course (5 Gy x 3 days; 3 Gy x 5 days) schedule. After RT, 35% of nonambulatory patients regained walking ability, and pain relief was recorded in 57% of patients with a median survival of 4 months. Efficacy of RT was highly dependent on the histology: 70% of nonambulatory breast cancer patients recovered mobility compared to only 20% of hepatocellular carcinoma patients. In general, solid tumors are considered either moderately radiosensitive (eg, breast and prostate cancers) or radioresistant (eg, melanoma; osteosarcomas; cancers of the thyroid, colon, and kidney).<sup>346</sup> On the other hand, hematologic malignancies

such as lymphomas and multiple myelomas are highly responsive to RT. Hence, RT alone is routinely utilized as therapy for these cancers, even in the presence of cord compression.

Where there is no compression, fracture, or instability, EBRT is effective in achieving local control as primary treatment. A mean 77% local control rate from seven retrospective studies including 885 patients was found in a systematic review by Gerszten and colleagues.<sup>346</sup> RT is also a mainstay of palliative treatment for patients with poor PS, significant comorbidities, and/or limited life expectancy (<3–4 months). Klimo's meta-analysis, including 543 patients treated by RT, revealed pain control rates of 54% to 83%.<sup>340</sup> Unlike surgery, RT has no immediate significant treatment-related complications and very few local recurrences. However, it increases surgical complications as it impairs wound healing.

The advent of SRS allowed precise high-dose targeting in one or two fractions while minimizing exposure of the surrounding cord. This is especially important in pre-irradiated patients. The largest prospective study involved a cohort of nearly 400 patients with 500 spinal metastases, 70% of which had previous conventional irradiation.<sup>347</sup> At a median follow-up of 21 months, radiosurgery resulted in long-term pain improvement and tumor control in 85% and 90% of cases, respectively. Other single-institution reports also suggest that SRS is safe and offers more durable response than conventional therapy.<sup>346</sup> An ongoing phase II/III trial (RTOG 0631) is comparing single-dose stereotactic RT of 16 Gy to single-dose EBRT of 8 Gy in patients with 1 to 3 spinal metastases.

### **Vertebral Augmentation**

Percutaneous vertebroplasty and kyphoplasty involve injection of cement (polymethyl methacrylate) into the vertebral body.

Vertebroplasty is a direct injection, while kyphoplasty involves inserting a balloon that provides a cavity for the injection. These vertebral augmentation procedures immediately reinforce and stabilize the column, thereby relieving pain and preventing further fractures.<sup>348</sup> They are suitable in poor surgical candidates with painful fractures, but are relatively contraindicated in the case of spinal cord compression because they do not achieve decompression. Symptomatic complications occur in up to 8% of patients (mostly with vertebroplasty), including embolization of the cement and local metastasis along the needle tract.

### **Systemic Therapy**

Corticosteroids remain a routine initial prescription for patients presenting with cord compression, with a number of theoretical benefits including anti-inflammation, reduction in edema, short-term neurologic function improvement, and enhanced blood flow. However, the preference between high-dose (96 mg daily) and low-dose (10–16 mg daily) is still unclear.<sup>349-351</sup>

Chemotherapy has a limited role in metastatic spinal tumors except for chemosensitive tumors such as lymphoma, myeloma, and germ cell tumor. Agents efficacious for the primary tumor are used.

## **NCCN Recommendations**

### **Workup**

Initial workup depends on the presence or absence of symptoms. Patients with an incidental, asymptomatic, metastatic lesion confirmed by systemic imaging can be observed with MRI. However, biopsy and further treatment of an incidental lesion are indicated if treatment of the patient is altered as a result of treatment of the incidental lesion. In the absence of symptoms, it is not mandatory to obtain a spinal MRI for every incidental metastatic lesion seen on surveillance bone scans. The

alternate category involves severe or new back pain. Increasing intensity, duration, and changes in the character of pain should trigger an evaluation with an MRI study, even in patients with pre-existing degenerative spine conditions. Immediate spinal MRI is warranted in the occurrence of neurologic symptoms including weakness, paresthesias, and bladder or bowel incontinence. Contrast can be used to highlight and further evaluate any focal abnormality. The MRI can be used to image the entire spine or a focal area of interest. If the patient is unable to have an MRI, then a CT myelogram is recommended.

A normal neurologic examination implies that there is no spinal radiculopathy or myelopathy correlating with the patient's symptoms. In this case, other causes should be considered (eg, leptomeningeal disease). An abnormal neurologic examination includes motor abnormalities, sphincter abnormalities, and/or sensory deficits attributable to a dysfunction of nerve root(s) and/or the spinal cord. Therefore, detection of radiculopathy, myelopathy, or cauda equina syndrome is indicative of an abnormal examination. However, reflex asymmetry and/or presence of pathologic reflexes, as well as sensory deficits of a stocking/glove distribution are excluded.

### **Treatment**

Once metastatic vertebral involvement is diagnosed, treatment is based on whether the patient is suffering from spinal cord compression, fracture, or spinal instability. In the presence of multiple metastatic spinal tumors, the one causing the patient's main symptoms is addressed first. Additional tumors can be treated at a later point according to the algorithm.

Radiographic spinal cord compression implies deformation of the spinal cord because of epidural tumor, retropulsed bone fragment, or both. It should be noted that epidural tumor may occupy part of the spinal canal

with or without partial obliteration of CSF around the spinal cord. Those cases are excluded because there is no cord deformation. For tumors occurring below L1, any canal compression of 50% or more should be considered of equal importance as spinal cord compression. Patients with radiographic cord compression should start on dexamethasone (10–100 mg) to alleviate symptoms. Decompressive surgery (concomitant stabilization if indicated) and adjuvant RT is the preferred treatment (category 1) where there is spinal instability and no surgical contraindication. Primary EBRT alone is appropriate for patients with radiosensitive cancers (hematologic malignancies) and without evidence of spinal instability. Many fractionation schemes are available (15–40 Gy in 1–15 fractions over 1 day–3 weeks); the most common is a total of 30 Gy in 3-Gy daily fractions for 10 days.<sup>352,353</sup> Tolerance at the spine and/or nerve route must be considered in determining dose. Primary chemotherapy is also an option for chemo-responsive tumors in the absence of clinical myelopathy. In general, a treatment interval of at least 6 months is recommended.

Metastases to the spine without cord compression include the presence of tumor in the vertebral body, pedicle(s), lamina, transverse, or spinous process. It can also include epidural disease without cord deformation. Patients in this category should be assessed for fractures and spinal instability. Because the criteria for spinal destabilization secondary to tumor remain unclear, consultation by a surgeon is recommended. *Spinal instability* is grossly defined as the presence of significant kyphosis or spondylolisthesis (deformity) or of significantly retropulsed bone fragment. Not every pathologic fracture implies unstable structure. The degree of kyphosis or spondylolisthesis compatible with instability depends on the location of the tumor in the spine. The cross-sectional area of the vertebral body unaffected by the tumor and the patient's bone mineral density are additional factors affecting stability. In addition, vertebral



body involvement is more important than dorsal element involvement with regard to stability. Circumferential disease as well as junctional and contiguous tumor location should be taken into account when assessing spinal stability. If fracture or instability is detected, the patient should undergo surgical stabilization or minimally invasive vertebral augmentation to relieve pain. These procedures should be followed by adjuvant RT to obtain local control.

If no fracture or instability is found, EBRT is the treatment of choice. Stereotactic RT may be appropriate in select cases of limited disease. Other alternatives are chemotherapy for responsive tumors, or surgery plus adjuvant RT in select cases. Patients experiencing intractable pain or rapid neurologic decline during RT should consider surgery or SRS. Neurologic deterioration is apparent when the patient's neurologic examination is becoming worse on a daily basis and the patient's ambulatory status is threatened. Intractable pain means either that pain is not controlled with oral analgesics or that the patient cannot tolerate the medication due to side effects.

### ***Progression and Recurrence***

Follow-up involves MRI or CT imaging within one to three months post-treatment, then every three to six months as indicated. Upon detection of progression or recurrence on imaging scans, management strategy is based on previous treatment. Patients who underwent prior RT or surgery plus adjuvant RT may consider surgery or re-irradiation to the recurred area. Stereotactic RT may be appropriate for select patients. Clinicians should plan 6 months or more between treatments in consideration of tolerance of the spine and its nerve roots. Retreatment dose should be limited to no more than 10 Gy to the surface of the spinal cord. Patients previously treated by chemotherapy can consider salvage RT.

### References

1. Siegel R, Ma J, Zou Z, Jemal A. Cancer statistics, 2014. *CA Cancer J Clin* 2014;64:9-29. Available at: <http://www.ncbi.nlm.nih.gov/pubmed/24399786>.
2. Maher EA, McKee AC. Neoplasms of the central nervous system. In: Skarin AT, Canellos GP, eds. *Atlas of diagnostic oncology* (ed 3rd). London, United Kingdom: Elsevier Science Ltd; 2003.
3. Patchell RA. The management of brain metastases. *Cancer Treat Rev* 2003;29:533-540. Available at: <http://www.ncbi.nlm.nih.gov/pubmed/14585263>.
4. Sawaya R, Hammoud M, Schoppa D, et al. Neurosurgical outcomes in a modern series of 400 craniotomies for treatment of parenchymal tumors. *Neurosurgery* 1998;42:1044-1055; discussion 1055-1046. Available at: <http://www.ncbi.nlm.nih.gov/pubmed/9588549>.
5. Louis DN, Ohgaki H, Wiestler OD, et al. The 2007 WHO classification of tumours of the central nervous system. *Acta Neuropathol* 2007;114:97-109. Available at: <http://www.ncbi.nlm.nih.gov/pubmed/17618441>.
6. Pignatti F, van den Bent M, Curran D, et al. Prognostic factors for survival in adult patients with cerebral low-grade glioma. *J Clin Oncol* 2002;20:2076-2084. Available at: <http://www.ncbi.nlm.nih.gov/pubmed/11956268>.
7. Daniels TB, Brown PD, Felten SJ, et al. Validation of EORTC prognostic factors for adults with low-grade glioma: a report using intergroup 86-72-51. *Int J Radiat Oncol Biol Phys* 2011;81:218-224. Available at: <http://www.ncbi.nlm.nih.gov/pubmed/21549518>.
8. Chang EF, Potts MB, Keles GE, et al. Seizure characteristics and control following resection in 332 patients with low-grade gliomas. *J Neurosurg* 2008;108:227-235. Available at: <http://www.ncbi.nlm.nih.gov/pubmed/18240916>.
9. Piepmeier J, Christopher S, Spencer D, et al. Variations in the natural history and survival of patients with supratentorial low-grade astrocytomas. *Neurosurgery* 1996;38:872-878; discussion 878-879. Available at: <http://www.ncbi.nlm.nih.gov/pubmed/8727811>.
10. Afra D, Osztie E, Sipos L, Vitanovics D. Preoperative history and postoperative survival of supratentorial low-grade astrocytomas. *Br J Neurosurg* 1999;13:299-305. Available at: <http://www.ncbi.nlm.nih.gov/pubmed/10562842>.
11. Cairncross JG, Ueki K, Zlatescu MC, et al. Specific genetic predictors of chemotherapeutic response and survival in patients with anaplastic oligodendrogliomas. *J Natl Cancer Inst* 1998;90:1473-1479. Available at: <http://www.ncbi.nlm.nih.gov/pubmed/9776413>.
12. CBTRUS: Statistical report: Primary Brain Tumors in the United States, 1995-1999. Chicago: Central Brain Tumor Registry of the United States; 2002.
13. Lang FF, Gilbert MR. Diffusely Infiltrative Low-Grade Gliomas in Adults. *J Clin Oncol* 2006;24:1236-1245. Available at: <http://jco.ascopubs.org/cgi/content/abstract/24/8/1236>.
14. Lo SS, Cho KH, Hall WA, et al. Does the extent of surgery have an impact on the survival of patients who receive postoperative radiation therapy for supratentorial low-grade gliomas? *Int J Cancer* 2001;96 Suppl:71-78. Available at: <http://www.ncbi.nlm.nih.gov/pubmed/11992388>.
15. Philippon JH, Clemenceau SH, Fauchon FH, Foncin JF. Supratentorial low-grade astrocytomas in adults. *Neurosurgery* 1993;32:554-559. Available at: <http://www.ncbi.nlm.nih.gov/pubmed/8474646>.
16. Soffietti R, Chio A, Giordana MT, et al. Prognostic factors in well-differentiated cerebral astrocytomas in the adult. *Neurosurgery* 1989;24:686-692. Available at: <http://www.ncbi.nlm.nih.gov/pubmed/2716976>.

17. Smith JS, Chang EF, Lamborn KR, et al. Role of Extent of Resection in the Long-Term Outcome of Low-Grade Hemispheric Gliomas. *J Clin Oncol* 2008;26:1338-1345. Available at: <http://jco.ascopubs.org/cgi/content/abstract/26/8/1338>.
18. Shaw EG, Daumas-Duport C, Scheithauer BW, et al. Radiation therapy in the management of low-grade supratentorial astrocytomas. *J Neurosurg* 1989;70:853-861. Available at: <http://www.ncbi.nlm.nih.gov/pubmed/2715812>.
19. Kilic T, Ozduman K, Elmaci I, et al. Effect of surgery on tumor progression and malignant degeneration in hemispheric diffuse low-grade astrocytomas. *J Clin Neurosci* 2002;9:549-552. Available at: <http://www.ncbi.nlm.nih.gov/pubmed/12383413>.
20. McGirt MJ, Chaichana KL, Attenello FJ, et al. Extent of surgical resection is independently associated with survival in patients with hemispheric infiltrating low-grade gliomas. *Neurosurgery* 2008;63:700-707; author reply 707-708. Available at: <http://www.ncbi.nlm.nih.gov/pubmed/18981880>.
21. Chaichana KL, McGirt MJ, Lattera J, et al. Recurrence and malignant degeneration after resection of adult hemispheric low-grade gliomas. *J Neurosurg* 2010;112:10-17. Available at: <http://www.ncbi.nlm.nih.gov/pubmed/19361270>.
22. Berger MS, Deliganis AV, Dobbins J, Keles GE. The effect of extent of resection on recurrence in patients with low grade cerebral hemisphere gliomas. *Cancer* 1994;74:1784-1791. Available at: <http://www.ncbi.nlm.nih.gov/pubmed/8082081>.
23. Karim AB, Afra D, Cornu P, et al. Randomized trial on the efficacy of radiotherapy for cerebral low-grade glioma in the adult: European Organization for Research and Treatment of Cancer Study 22845 with the Medical Research Council study BRO4: an interim analysis. *Int J Radiat Oncol Biol Phys* 2002;52:316-324. Available at: <http://www.ncbi.nlm.nih.gov/pubmed/11872276>.
24. van den Bent MJ, Afra D, de Witte O, et al. Long-term efficacy of early versus delayed radiotherapy for low-grade astrocytoma and oligodendroglioma in adults: the EORTC 22845 randomised trial. *Lancet* 2005;366:985-990. Available at: <http://www.ncbi.nlm.nih.gov/pubmed/16168780>.
25. Shaw EG, Tatter SB, Lesser GJ, et al. Current controversies in the radiotherapeutic management of adult low-grade glioma. *Semin Oncol* 2004;31:653-658. Available at: <http://www.ncbi.nlm.nih.gov/pubmed/15497118>.
26. Shaw EG, Wisoff JH. Prospective clinical trials of intracranial low-grade glioma in adults and children. *Neuro Oncol* 2003;5:153-160. Available at: <http://www.ncbi.nlm.nih.gov/pubmed/12816721>.
27. Karim AB, Maat B, Hatlevoll R, et al. A randomized trial on dose-response in radiation therapy of low-grade cerebral glioma: European Organization for Research and Treatment of Cancer (EORTC) Study 22844. *Int J Radiat Oncol Biol Phys* 1996;36:549-556. Available at: <http://www.ncbi.nlm.nih.gov/pubmed/8948338>.
28. Shaw E, Arusell R, Scheithauer B, et al. Prospective randomized trial of low- versus high-dose radiation therapy in adults with supratentorial low-grade glioma: initial report of a North Central Cancer Treatment Group/Radiation Therapy Oncology Group/Eastern Cooperative Oncology Group study. *J Clin Oncol* 2002;20:2267-2276. Available at: <http://www.ncbi.nlm.nih.gov/pubmed/11980997>.
29. Roberge D, Souhami L, Olivier A, et al. Hypofractionated stereotactic radiotherapy for low grade glioma at McGill University: long-term follow-up. *Technol Cancer Res Treat* 2006;5:1-8. Available at: <http://www.ncbi.nlm.nih.gov/pubmed/16417396>.
30. Quinn JA, Reardon DA, Friedman AH, et al. Phase II trial of temozolomide in patients with progressive low-grade glioma. *J Clin Oncol* 2003;21:646-651. Available at: <http://www.ncbi.nlm.nih.gov/pubmed/12586801>.



## NCCN Guidelines Version 2.2014 Central Nervous System Cancers

31. Kesari S, Schiff D, Drappatz J, et al. Phase II study of protracted daily temozolomide for low-grade gliomas in adults. *Clin Cancer Res* 2009;15:330-337. Available at:

<http://www.ncbi.nlm.nih.gov/pubmed/19118062>.

32. Pouratian N, Gasco J, Sherman JH, et al. Toxicity and efficacy of protracted low dose temozolomide for the treatment of low grade gliomas. *J Neurooncol* 2007;82:281-288. Available at:

<http://www.ncbi.nlm.nih.gov/pubmed/17082887>.

33. Shaw EG, Wang M, Coons SW, et al. Randomized trial of radiation therapy plus procarbazine, lomustine, and vincristine chemotherapy for supratentorial adult low-grade glioma: initial results of RTOG 9802. *J Clin Oncol* 2012;30:3065-3070. Available at:

<http://www.ncbi.nlm.nih.gov/pubmed/22851558>.

34. Chamberlain MC. Does RTOG 9802 change practice with respect to newly diagnosed low-grade glioma? *J Clin Oncol* 2013;31:652-653.

Available at: <http://www.ncbi.nlm.nih.gov/pubmed/23295807>.

35. van den Bent MJ, Jaeckle K, Baumert B, Wick W. RTOG 9802: good wines need aging. *J Clin Oncol* 2013;31:653-654. Available at:

<http://www.ncbi.nlm.nih.gov/pubmed/23295798>.

36. Perry JR, Rizek P, Cashman R, et al. Temozolomide rechallenge in recurrent malignant glioma by using a continuous temozolomide schedule: the "rescue" approach. *Cancer* 2008;113:2152-2157.

Available at: <http://www.ncbi.nlm.nih.gov/pubmed/18756530>.

37. Massimino M, Spreafico F, Riva D, et al. A lower-dose, lower-toxicity cisplatin-etoposide regimen for childhood progressive low-grade glioma. *J Neurooncol* 2010. Available at:

<http://www.ncbi.nlm.nih.gov/pubmed/20151174>.

38. Moghrabi A, Friedman HS, Ashley DM, et al. Phase II study of carboplatin (CBDCA) in progressive low-grade gliomas. *Neurosurg Focus* 1998;4:e3. Available at:

<http://www.ncbi.nlm.nih.gov/pubmed/17168503>.

39. Brandes AA, Basso U, Vastola F, et al. Carboplatin and teniposide as third-line chemotherapy in patients with recurrent oligodendroglioma or oligoastrocytoma: a phase II study. *Ann Oncol* 2003;14:1727-1731.

Available at: <http://www.ncbi.nlm.nih.gov/pubmed/14630676>.

40. Hoang-Xuan K, Capelle L, Kujas M, et al. Temozolomide as initial treatment for adults with low-grade oligodendrogliomas or oligoastrocytomas and correlation with chromosome 1p deletions. *J Clin Oncol* 2004;22:3133-3138. Available at:

<http://www.ncbi.nlm.nih.gov/pubmed/15284265>.

41. Kaloshi G, Benouaich-Amiel A, Diakite F, et al. Temozolomide for low-grade gliomas: predictive impact of 1p/19q loss on response and outcome. *Neurology* 2007;68:1831-1836. Available at:

<http://www.ncbi.nlm.nih.gov/pubmed/17515545>.

42. Buckner JC, Gesme D, Jr., O'Fallon JR, et al. Phase II trial of procarbazine, lomustine, and vincristine as initial therapy for patients with low-grade oligodendroglioma or oligoastrocytoma: efficacy and associations with chromosomal abnormalities. *J Clin Oncol* 2003;21:251-255. Available at:

<http://www.ncbi.nlm.nih.gov/pubmed/12525516>.

43. Cairncross G, Macdonald D, Ludwin S, et al. Chemotherapy for anaplastic oligodendroglioma. National Cancer Institute of Canada Clinical Trials Group. *J Clin Oncol* 1994;12:2013-2021. Available at:

<http://www.ncbi.nlm.nih.gov/pubmed/7931469>.

44. Ino Y, Betensky RA, Zlatescu MC, et al. Molecular subtypes of anaplastic oligodendroglioma: implications for patient management at diagnosis. *Clin Cancer Res* 2001;7:839-845. Available at:

<http://www.ncbi.nlm.nih.gov/pubmed/11309331>.

45. van den Bent M, Chinot OL, Cairncross JG. Recent developments in the molecular characterization and treatment of oligodendroglial tumors. *Neuro Oncol* 2003;5:128-138. Available at:

<http://www.ncbi.nlm.nih.gov/pubmed/12672285>.



## NCCN Guidelines Version 2.2014 Central Nervous System Cancers

46. Houillier C, Wang X, Kaloshi G, et al. IDH1 or IDH2 mutations predict longer survival and response to temozolomide in low-grade gliomas. *Neurology* 2010;75:1560-1566. Available at: <http://www.ncbi.nlm.nih.gov/pubmed/20975057>.

47. Shaw EG, Berkey B, Coons SW, et al. Recurrence following neurosurgeon-determined gross-total resection of adult supratentorial low-grade glioma: results of a prospective clinical trial. *J Neurosurg* 2008;109:835-841. Available at: <http://www.ncbi.nlm.nih.gov/pubmed/18976072>.

48. Lo SS, Hall WA, Cho KH, et al. Radiation dose response for supratentorial low-grade glioma--institutional experience and literature review. *J Neurol Sci* 2003;214:43-48. Available at: <http://www.ncbi.nlm.nih.gov/pubmed/12972387>.

49. Ostrom QT, Gittleman H, Farah P, et al. CBTRUS Statistical Report: Primary Brain and Central Nervous System Tumors Diagnosed in the United States in 2006-2010. *Neuro-Oncology* 2013;15:ii1-ii56. Available at: [http://neuro-oncology.oxfordjournals.org/content/15/suppl\\_2/ii1.short](http://neuro-oncology.oxfordjournals.org/content/15/suppl_2/ii1.short).

50. Curran WJ, Jr., Scott CB, Horton J, et al. Recursive partitioning analysis of prognostic factors in three Radiation Therapy Oncology Group malignant glioma trials. *J Natl Cancer Inst* 1993;85:704-710. Available at: <http://www.ncbi.nlm.nih.gov/pubmed/8478956>.

51. Cairncross G, Berkey B, Shaw E, et al. Phase III trial of chemotherapy plus radiotherapy compared with radiotherapy alone for pure and mixed anaplastic oligodendroglioma: Intergroup Radiation Therapy Oncology Group Trial 9402. *J Clin Oncol* 2006;24:2707-2714. Available at: <http://www.ncbi.nlm.nih.gov/pubmed/16782910>.

52. Central Brain Tumor Registry of the United States. CBTRUS statistical report: Primary brain and central nervous system tumors diagnosed in the United States in 2004-1006. 2010. Available at: <http://www.cbtrus.org/reports/reports.html>. Accessed August 11, 2014.

53. Laws ER, Parney IF, Huang W, et al. Survival following surgery and prognostic factors for recently diagnosed malignant glioma: data from the Glioma Outcomes Project. *J Neurosurg* 2003;99:467-473. Available at: <http://www.ncbi.nlm.nih.gov/pubmed/12959431>.

54. Simpson JR, Horton J, Scott C, et al. Influence of location and extent of surgical resection on survival of patients with glioblastoma multiforme: results of three consecutive Radiation Therapy Oncology Group (RTOG) clinical trials. *Int J Radiat Oncol Biol Phys* 1993;26:239-244. Available at: <http://www.ncbi.nlm.nih.gov/pubmed/8387988>.

55. Wood JR, Green SB, Shapiro WR. The prognostic importance of tumor size in malignant gliomas: a computed tomographic scan study by the Brain Tumor Cooperative Group. *J Clin Oncol* 1988;6:338-343. Available at: <http://www.ncbi.nlm.nih.gov/pubmed/3339397>.

56. Lacroix M, Abi-Said D, Fourny DR, et al. A multivariate analysis of 416 patients with glioblastoma multiforme: prognosis, extent of resection, and survival. *J Neurosurg* 2001;95:190-198. Available at: <http://www.ncbi.nlm.nih.gov/pubmed/11780887>.

57. Barker FG, 2nd, Chang SM, Gutin PH, et al. Survival and functional status after resection of recurrent glioblastoma multiforme. *Neurosurgery* 1998;42:709-720; discussion 720-703. Available at: <http://www.ncbi.nlm.nih.gov/pubmed/9574634>.

58. Park JK, Hodges T, Arko L, et al. Scale to predict survival after surgery for recurrent glioblastoma multiforme. *J Clin Oncol* 2010;28:3838-3843. Available at: <http://www.ncbi.nlm.nih.gov/pubmed/20644085>.

59. Walker MD, Alexander E, Jr., Hunt WE, et al. Evaluation of BCNU and/or radiotherapy in the treatment of anaplastic gliomas. A cooperative clinical trial. *J Neurosurg* 1978;49:333-343. Available at: <http://www.ncbi.nlm.nih.gov/pubmed/355604>.

60. Kristiansen K, Hagen S, Kollevold T, et al. Combined modality therapy of operated astrocytomas grade III and IV. Confirmation of the



# NCCN Guidelines Version 2.2014

## Central Nervous System Cancers

value of postoperative irradiation and lack of potentiation of bleomycin on survival time: a prospective multicenter trial of the Scandinavian Glioblastoma Study Group. *Cancer* 1981;47:649-652. Available at: <http://www.ncbi.nlm.nih.gov/pubmed/6164465>.

61. Keime-Guibert F, Chinot O, Taillandier L, et al. Radiotherapy for glioblastoma in the elderly. *N Engl J Med* 2007;356:1527-1535. Available at: <http://www.ncbi.nlm.nih.gov/pubmed/17429084>.

62. Roa W, Brasher PM, Bauman G, et al. Abbreviated course of radiation therapy in older patients with glioblastoma multiforme: a prospective randomized clinical trial. *J Clin Oncol* 2004;22:1583-1588. Available at: <http://www.ncbi.nlm.nih.gov/pubmed/15051755>.

63. Malmstrom A, Gronberg BH, Marosi C, et al. Temozolomide versus standard 6-week radiotherapy versus hypofractionated radiotherapy in patients older than 60 years with glioblastoma: the Nordic randomised, phase 3 trial. *Lancet Oncol* 2012. Available at: <http://www.ncbi.nlm.nih.gov/pubmed/22877848>.

64. Laperriere NJ, Leung PM, McKenzie S, et al. Randomized study of brachytherapy in the initial management of patients with malignant astrocytoma. *Int J Radiat Oncol Biol Phys* 1998;41:1005-1011. Available at: <http://www.ncbi.nlm.nih.gov/pubmed/9719109>.

65. Souhami L, Seiferheld W, Brachman D, et al. Randomized comparison of stereotactic radiosurgery followed by conventional radiotherapy with carmustine to conventional radiotherapy with carmustine for patients with glioblastoma multiforme: report of Radiation Therapy Oncology Group 93-05 protocol. *Int J Radiat Oncol Biol Phys* 2004;60:853-860. Available at: <http://www.ncbi.nlm.nih.gov/pubmed/15465203>.

66. Nieder C, Astner ST, Mehta MP, et al. Improvement, clinical course, and quality of life after palliative radiotherapy for recurrent glioblastoma. *Am J Clin Oncol* 2008;31:300-305. Available at: <http://www.ncbi.nlm.nih.gov/pubmed/18525311>.

67. Combs SE, Debus J, Schulz-Ertner D. Radiotherapeutic alternatives for previously irradiated recurrent gliomas. *BMC Cancer* 2007;7:167. Available at: <http://www.ncbi.nlm.nih.gov/pubmed/17760992>.

68. Medical Research Council Brain Tumor Working Party. Randomized trial of procarbazine, lomustine, and vincristine in the adjuvant treatment of high-grade astrocytoma: a Medical Research Council trial. *J Clin Oncol* 2001;19:509-518. Available at: <http://www.ncbi.nlm.nih.gov/pubmed/11208845>.

69. Stewart LA. Chemotherapy in adult high-grade glioma: a systematic review and meta-analysis of individual patient data from 12 randomised trials. *Lancet* 2002;359:1011-1018. Available at: <http://www.ncbi.nlm.nih.gov/pubmed/11937180>.

70. Fine HA, Dear KB, Loeffler JS, et al. Meta-analysis of radiation therapy with and without adjuvant chemotherapy for malignant gliomas in adults. *Cancer* 1993;71:2585-2597. Available at: <http://www.ncbi.nlm.nih.gov/pubmed/8453582>.

71. Brem H, Piantadosi S, Burger PC, et al. Placebo-controlled trial of safety and efficacy of intraoperative controlled delivery by biodegradable polymers of chemotherapy for recurrent gliomas. The Polymer-brain Tumor Treatment Group. *Lancet* 1995;345:1008-1012. Available at: <http://www.ncbi.nlm.nih.gov/pubmed/7723496>.

72. Valtonen S, Timonen U, Toivanen P, et al. Interstitial chemotherapy with carmustine-loaded polymers for high-grade gliomas: a randomized double-blind study. *Neurosurgery* 1997;41:44-48; discussion 48-49. Available at: <http://www.ncbi.nlm.nih.gov/pubmed/9218294>.

73. Westphal M, Hilt DC, Bortey E, et al. A phase 3 trial of local chemotherapy with biodegradable carmustine (BCNU) wafers (Gliadel wafers) in patients with primary malignant glioma. *Neuro Oncol* 2003;5:79-88. Available at: <http://www.ncbi.nlm.nih.gov/pubmed/12672279>.

74. Westphal M, Ram Z, Riddle V, et al. Gliadel wafer in initial surgery for malignant glioma: long-term follow-up of a multicenter controlled trial. *Acta Neurochir (Wien)* 2006;148:269-275; discussion 275.

Available at: <http://www.ncbi.nlm.nih.gov/pubmed/16482400>.

75. Stupp R, Mason WP, van den Bent MJ, et al. Radiotherapy plus concomitant and adjuvant temozolomide for glioblastoma. *N Engl J Med* 2005;352:987-996. Available at:

<http://www.ncbi.nlm.nih.gov/pubmed/15758009>.

76. Stupp R, Hegi ME, Mason WP, et al. Effects of radiotherapy with concomitant and adjuvant temozolomide versus radiotherapy alone on survival in glioblastoma in a randomised phase III study: 5-year analysis of the EORTC-NCIC trial. *Lancet Oncol* 2009;10:459-466. Available at:

<http://www.ncbi.nlm.nih.gov/pubmed/19269895>.

77. Clarke JL, Iwamoto FM, Sul J, et al. Randomized phase II trial of chemoradiotherapy followed by either dose-dense or metronomic temozolomide for newly diagnosed glioblastoma. *J Clin Oncol* 2009;27:3861-3867. Available at:

<http://www.ncbi.nlm.nih.gov/pubmed/19506159>.

78. Gilbert MR, Wang M, Aldape KD, et al. RTOG 0525: A randomized phase III trial comparing standard adjuvant temozolomide (TMZ) with a dose-dense (dd) schedule in newly diagnosed glioblastoma (GBM) [abstract]. *J Clin Oncol* 2011;29(Suppl 15):Abstract 2006. Available at:

[http://meeting.ascopubs.org/cgi/content/abstract/29/15\\_suppl/2006](http://meeting.ascopubs.org/cgi/content/abstract/29/15_suppl/2006).

79. Wick W, Hartmann C, Engel C, et al. NOA-04 randomized phase III trial of sequential radiochemotherapy of anaplastic glioma with procarbazine, lomustine, and vincristine or temozolomide. *J Clin Oncol* 2009;27:5874-5880. Available at:

<http://www.ncbi.nlm.nih.gov/pubmed/19901110>.

80. Wick W, Platten M, Meisner C, et al. Temozolomide chemotherapy alone versus radiotherapy alone for malignant astrocytoma in the elderly: the NOA-08 randomised, phase 3 trial. *Lancet Oncol*

2012;13:707-715. Available at:

<http://www.ncbi.nlm.nih.gov/pubmed/22578793>.

81. Mollemann M, Wolter M, Felsberg J, et al. Frequent promoter hypermethylation and low expression of the MGMT gene in oligodendroglial tumors. *Int J Cancer* 2005;113:379-385. Available at:

<http://www.ncbi.nlm.nih.gov/pubmed/15455350>.

82. Dixit S, Hingorani M, Achawal S, Scott I. The sequential use of carmustine wafers (Gliadel(R)) and post-operative radiotherapy with concomitant temozolomide followed by adjuvant temozolomide: a clinical review. *Br J Neurosurg* 2011;25:459-469. Available at:

<http://www.ncbi.nlm.nih.gov/pubmed/21344976>.

83. McGirt MJ, Than KD, Weingart JD, et al. Gliadel (BCNU) wafer plus concomitant temozolomide therapy after primary resection of glioblastoma multiforme. *J Neurosurg* 2009;110:583-588. Available at:

<http://www.ncbi.nlm.nih.gov/pubmed/19046047>.

84. Salvati M, D'Elia A, Frati A, et al. Safety and feasibility of the adjunct of local chemotherapy with biodegradable carmustine (BCNU) wafers to the standard multimodal approach to high grade gliomas at first diagnosis. *J Neurosurg Sci* 2011;55:1-6. Available at:

<http://www.ncbi.nlm.nih.gov/pubmed/21464805>.

85. Brandes AA, Vastola F, Basso U, et al. A prospective study on glioblastoma in the elderly. *Cancer* 2003;97:657-662. Available at:

<http://www.ncbi.nlm.nih.gov/pubmed/12548608>.

86. Minniti G, De Sanctis V, Muni R, et al. Radiotherapy plus concomitant and adjuvant temozolomide for glioblastoma in elderly patients. *J Neurooncol* 2008;88:97-103. Available at:

<http://www.ncbi.nlm.nih.gov/pubmed/18250965>.

87. Glantz M, Chamberlain M, Liu Q, et al. Temozolomide as an alternative to irradiation for elderly patients with newly diagnosed malignant gliomas. *Cancer* 2003;97:2262-2266. Available at:

<http://www.ncbi.nlm.nih.gov/pubmed/12712481>.



## NCCN Guidelines Version 2.2014 Central Nervous System Cancers

88. Cairncross G, Wang M, Shaw E, et al. Phase III Trial of Chemoradiotherapy for Anaplastic Oligodendroglioma: Long-Term Results of RTOG 9402. *J Clin Oncol* 2013;31:337-343. Available at: <http://www.ncbi.nlm.nih.gov/pubmed/23071247>.

89. van den Bent MJ, Brandes AA, Taphoorn MJ, et al. Adjuvant procarbazine, lomustine, and vincristine chemotherapy in newly diagnosed anaplastic oligodendroglioma: long-term follow-up of EORTC brain tumor group study 26951. *J Clin Oncol* 2013;31:344-350. Available at: <http://www.ncbi.nlm.nih.gov/pubmed/23071237>.

90. Perry JR, Belanger K, Mason WP, et al. Phase II trial of continuous dose-intense temozolomide in recurrent malignant glioma: RESCUE study. *J Clin Oncol* 2010;28:2051-2057. Available at: <http://www.ncbi.nlm.nih.gov/pubmed/20308655>.

91. Yung WK, Prados MD, Yaya-Tur R, et al. Multicenter phase II trial of temozolomide in patients with anaplastic astrocytoma or anaplastic oligoastrocytoma at first relapse. Temodal Brain Tumor Group. *J Clin Oncol* 1999;17:2762-2771. Available at: <http://www.ncbi.nlm.nih.gov/pubmed/10561351>.

92. Wick W, Puduvalli VK, Chamberlain MC, et al. Phase III study of enzastaurin compared with lomustine in the treatment of recurrent intracranial glioblastoma. *J Clin Oncol* 2010;28:1168-1174. Available at: <http://www.ncbi.nlm.nih.gov/pubmed/20124186>.

93. Triebels VH, Taphoorn MJ, Brandes AA, et al. Salvage PCV chemotherapy for temozolomide-resistant oligodendrogliomas. *Neurology* 2004;63:904-906. Available at: <http://www.ncbi.nlm.nih.gov/pubmed/15365146>.

94. Chamberlain MC, Tsao-Wei DD. Salvage chemotherapy with cyclophosphamide for recurrent, temozolomide-refractory glioblastoma multiforme. *Cancer* 2004;100:1213-1220. Available at: <http://www.ncbi.nlm.nih.gov/pubmed/15022289>.

95. Chamberlain MC, Tsao-Wei DD, Groshen S. Salvage chemotherapy with cyclophosphamide for recurrent temozolomide-refractory anaplastic astrocytoma. *Cancer* 2006;106:172-179. Available at: <http://www.ncbi.nlm.nih.gov/pubmed/16323194>.

96. Chamberlain MC, Wei-Tsao DD, Blumenthal DT, Glantz MJ. Salvage chemotherapy with CPT-11 for recurrent temozolomide-refractory anaplastic astrocytoma. *Cancer* 2008;112:2038-2045. Available at: <http://www.ncbi.nlm.nih.gov/pubmed/18361434>.

97. Fulton D, Urtasun R, Forsyth P. Phase II study of prolonged oral therapy with etoposide (VP16) for patients with recurrent malignant glioma. *J Neurooncol* 1996;27:149-155. Available at: <http://www.ncbi.nlm.nih.gov/pubmed/8699237>.

98. Friedman HS, Prados MD, Wen PY, et al. Bevacizumab alone and in combination with irinotecan in recurrent glioblastoma. *J Clin Oncol* 2009;27:4733-4740. Available at: <http://www.ncbi.nlm.nih.gov/pubmed/19720927>.

99. Vredenburgh JJ, Desjardins A, Herndon JE, 2nd, et al. Bevacizumab plus irinotecan in recurrent glioblastoma multiforme. *J Clin Oncol* 2007;25:4722-4729. Available at: <http://www.ncbi.nlm.nih.gov/pubmed/17947719>.

100. Kreisl TN, Kim L, Moore K, et al. Phase II trial of single-agent bevacizumab followed by bevacizumab plus irinotecan at tumor progression in recurrent glioblastoma. *J Clin Oncol* 2009;27:740-745. Available at: <http://www.ncbi.nlm.nih.gov/pubmed/19114704>.

101. Chamberlain MC, Johnston S. Bevacizumab for recurrent alkylator-refractory anaplastic oligodendroglioma. *Cancer* 2009;115:1734-1743. Available at: <http://www.ncbi.nlm.nih.gov/pubmed/19197992>.

102. Chamberlain MC, Johnston S. Salvage chemotherapy with bevacizumab for recurrent alkylator-refractory anaplastic astrocytoma. *J Neurooncol* 2009;91:359-367. Available at: <http://www.ncbi.nlm.nih.gov/pubmed/18953491>.



## NCCN Guidelines Version 2.2014 Central Nervous System Cancers

103. Norden AD, Young GS, Setayesh K, et al. Bevacizumab for recurrent malignant gliomas: efficacy, toxicity, and patterns of recurrence. *Neurology* 2008;70:779-787. Available at: <http://www.ncbi.nlm.nih.gov/pubmed/18316689>.

104. Soffietti R, Ruda R, Trevisan E, et al. Phase II study of bevacizumab and nitrosourea in patients with recurrent malignant glioma: A multicenter Italian study [abstract]. *J Clin Oncol* 2009;27(Suppl 15S):2012. Available at: <http://meeting.ascopubs.org/cgi/content/abstract/27/15S/2012>.

105. Taillibert S, Vincent LA, Granger B, et al. Bevacizumab and irinotecan for recurrent oligodendroglial tumors. *Neurology* 2009;72:1601-1606. Available at: <http://www.ncbi.nlm.nih.gov/pubmed/19414728>.

106. Vredenburgh JJ, Desjardins A, Herndon JE, 2nd, et al. Phase II trial of bevacizumab and irinotecan in recurrent malignant glioma. *Clin Cancer Res* 2007;13:1253-1259. Available at: <http://www.ncbi.nlm.nih.gov/pubmed/17317837>.

107. Mrugala MM, Crew LK, Fink JR, Spence AM. Carboplatin and bevacizumab for recurrent malignant glioma. *Oncol Lett* 2012;4:1082-1086. Available at: <http://www.ncbi.nlm.nih.gov/pubmed/23162656>.

108. Thompson EM, Dosa E, Kraemer DF, Neuwelt EA. Treatment with bevacizumab plus carboplatin for recurrent malignant glioma. *Neurosurgery* 2010;67:87-93. Available at: <http://www.ncbi.nlm.nih.gov/pubmed/20559095>.

109. Stupp R, Wong ET, Kanner AA, et al. NovoTTF-100A versus physician's choice chemotherapy in recurrent glioblastoma: A randomised phase III trial of a novel treatment modality. *Eur J Cancer* 2012. Available at: <http://www.ncbi.nlm.nih.gov/pubmed/22608262>.

110. Yovino S, Grossman SA. Treatment of glioblastoma in "elderly" patients. *Curr Treat Options Oncol* 2011;12:253-262. Available at: <http://www.ncbi.nlm.nih.gov/pubmed/21655911>.

111. Tsien C, Galban CJ, Chenevert TL, et al. Parametric response map as an imaging biomarker to distinguish progression from pseudoprogression in high-grade glioma. *J Clin Oncol* 2010;28:2293-2299. Available at: <http://www.ncbi.nlm.nih.gov/pubmed/20368564>.

112. Fink J, Born D, Chamberlain MC. Pseudoprogression: relevance with respect to treatment of high-grade gliomas. *Curr Treat Options Oncol* 2011;12:240-252. Available at: <http://www.ncbi.nlm.nih.gov/pubmed/21594589>.

113. Chamberlain MC. Ependymomas. *Curr Neurol Neurosci Rep* 2003;3:193-199. Available at: <http://www.ncbi.nlm.nih.gov/pubmed/12691623>.

114. DeVita VT, Lawrence TS, Rosenberg SA. DeVita, Hellman, and Rosenberg's Cancer: Principles and Practice of Oncology (ed 8). Philadelphia: Lippincott Williams & Wilkins; 2008.

115. Packer RJ, Hoffman HJ, Friedman HS. Tumors of the fourth ventricle. In: Levin VA, ed. *Cancer in the Nervous System*. New York: Churchill Livingstone; 1996:153-156.

116. Kawabata Y, Takahashi JA, Arakawa Y, Hashimoto N. Long-term outcome in patients harboring intracranial ependymoma. *J Neurosurg* 2005;103:31-37. Available at: <http://www.ncbi.nlm.nih.gov/pubmed/16121970>.

117. Metellus P, Figarella-Branger D, Guyotat J, et al. Supratentorial ependymomas: prognostic factors and outcome analysis in a retrospective series of 46 adult patients. *Cancer* 2008;113:175-185. Available at: <http://www.ncbi.nlm.nih.gov/pubmed/18470910>.

118. Metellus P, Barrie M, Figarella-Branger D, et al. Multicentric French study on adult intracranial ependymomas: prognostic factors analysis and therapeutic considerations from a cohort of 152 patients. *Brain* 2007;130:1338-1349. Available at: <http://www.ncbi.nlm.nih.gov/pubmed/17449478>.

119. Paulino AC, Wen BC, Buatti JM, et al. Intracranial ependymomas: an analysis of prognostic factors and patterns of failure. *Am J Clin Oncol* 2002;25:117-122. Available at:

<http://www.ncbi.nlm.nih.gov/pubmed/11943886>.

120. Schwartz TH, Kim S, Glick RS, et al. Supratentorial ependymomas in adult patients. *Neurosurgery* 1999;44:721-731. Available at:

<http://www.ncbi.nlm.nih.gov/pubmed/10201296>.

121. Rodriguez D, Cheung MC, Housri N, et al. Outcomes of malignant CNS ependymomas: an examination of 2408 cases through the Surveillance, Epidemiology, and End Results (SEER) database (1973-2005). *J Surg Res* 2009;156:340-351. Available at:

<http://www.ncbi.nlm.nih.gov/pubmed/19577759>.

122. Mansur DB, Perry A, Rajaram V, et al. Postoperative radiation therapy for grade II and III intracranial ependymoma. *Int J Radiat Oncol Biol Phys* 2005;61:387-391. Available at:

<http://www.ncbi.nlm.nih.gov/pubmed/15667957>.

123. Merchant TE, Fouladi M. Ependymoma: new therapeutic approaches including radiation and chemotherapy. *J Neurooncol* 2005;75:287-299. Available at:

<http://www.ncbi.nlm.nih.gov/pubmed/16195801>.

124. Taylor RE. Review of radiotherapy dose and volume for intracranial ependymoma. *Pediatr Blood Cancer* 2004;42:457-460.

Available at: <http://www.ncbi.nlm.nih.gov/pubmed/15049020>.

125. Reni M, Brandes AA, Vavassori V, et al. A multicenter study of the prognosis and treatment of adult brain ependymal tumors. *Cancer* 2004;100:1221-1229. Available at:

<http://www.ncbi.nlm.nih.gov/pubmed/15022290>.

126. Goldwein JW, Corn BW, Finlay JL, et al. Is craniospinal irradiation required to cure children with malignant (anaplastic) intracranial ependymomas? *Cancer* 1991;67:2766-2771. Available at:

<http://www.ncbi.nlm.nih.gov/pubmed/2025840>.

127. Vanuytsel L, Brada M. The role of prophylactic spinal irradiation in localized intracranial ependymoma. *Int J Radiat Oncol Biol Phys* 1991;21:825-830. Available at:

<http://www.ncbi.nlm.nih.gov/pubmed/1831193>.

128. Vanuytsel LJ, Bessell EM, Ashley SE, et al. Intracranial ependymoma: long-term results of a policy of surgery and radiotherapy. *Int J Radiat Oncol Biol Phys* 1992;23:313-319. Available at:

<http://www.ncbi.nlm.nih.gov/pubmed/1587752>.

129. Merchant TE, Li C, Xiong X, et al. Conformal radiotherapy after surgery for paediatric ependymoma: a prospective study. *Lancet Oncol* 2009;10:258-266. Available at:

<http://www.ncbi.nlm.nih.gov/pubmed/19274783>.

130. Kano H, Niranjana A, Kondziolka D, et al. Outcome predictors for intracranial ependymoma radiosurgery. *Neurosurgery* 2009;64:279-287; discussion 287-278. Available at:

<http://www.ncbi.nlm.nih.gov/pubmed/19190457>.

131. Lo SS, Abdulrahman R, Desrosiers PM, et al. The role of Gamma Knife Radiosurgery in the management of unresectable gross disease or gross residual disease after surgery in ependymoma. *J Neurooncol* 2006;79:51-56. Available at:

<http://www.ncbi.nlm.nih.gov/pubmed/16557349>.

132. Mansur DB, Drzymala RE, Rich KM, et al. The efficacy of stereotactic radiosurgery in the management of intracranial ependymoma. *J Neurooncol* 2004;66:187-190. Available at:

<http://www.ncbi.nlm.nih.gov/pubmed/15015785>.

133. Brandes AA, Cavallo G, Reni M, et al. A multicenter retrospective study of chemotherapy for recurrent intracranial ependymal tumors in adults by the Gruppo Italiano Cooperativo di Neuro-Oncologia. *Cancer* 2005;104:143-148. Available at:

<http://www.ncbi.nlm.nih.gov/pubmed/15912507>.

134. Gornet MK, Buckner JC, Marks RS, et al. Chemotherapy for advanced CNS ependymoma. *J Neurooncol* 1999;45:61-67. Available at: <http://www.ncbi.nlm.nih.gov/pubmed/10728911>.

135. Chamberlain MC. Recurrent intracranial ependymoma in children: salvage therapy with oral etoposide. *Pediatr Neurol* 2001;24:117-121. Available at: <http://www.ncbi.nlm.nih.gov/pubmed/11275460>.

136. Green RM, Cloughesy TF, Stupp R, et al. Bevacizumab for recurrent ependymoma. *Neurology* 2009;73:1677-1680. Available at: <http://www.ncbi.nlm.nih.gov/pubmed/19917990>.

137. Surawicz TS, McCarthy BJ, Kupelian V, et al. Descriptive epidemiology of primary brain and CNS tumors: results from the Central Brain Tumor Registry of the United States, 1990-1994. *Neuro Oncol* 1999;1:14-25. Available at: <http://www.ncbi.nlm.nih.gov/pubmed/11554386>.

138. Kunschner LJ, Kuttesch J, Hess K, Yung WK. Survival and recurrence factors in adult medulloblastoma: the M.D. Anderson Cancer Center experience from 1978 to 1998. *Neuro Oncol* 2001;3:167-173. Available at: <http://www.ncbi.nlm.nih.gov/pubmed/11465397>.

139. Padovani L, Sunyach MP, Perol D, et al. Common strategy for adult and pediatric medulloblastoma: a multicenter series of 253 adults. *Int J Radiat Oncol Biol Phys* 2007;68:433-440. Available at: <http://www.ncbi.nlm.nih.gov/pubmed/17498567>.

140. Carrie C, Lasset C, Alapetite C, et al. Multivariate analysis of prognostic factors in adult patients with medulloblastoma. Retrospective study of 156 patients. *Cancer* 1994;74:2352-2360. Available at: <http://www.ncbi.nlm.nih.gov/pubmed/7922986>.

141. Chan AW, Tarbell NJ, Black PM, et al. Adult medulloblastoma: prognostic factors and patterns of relapse. *Neurosurgery* 2000;47:623-631; discussion 631-622. Available at: <http://www.ncbi.nlm.nih.gov/pubmed/10981749>.

142. Frost PJ, Laperriere NJ, Wong CS, et al. Medulloblastoma in adults. *Int J Radiat Oncol Biol Phys* 1995;32:951-957. Available at: <http://www.ncbi.nlm.nih.gov/pubmed/7607969>.

143. Chargari C, Feuvret L, Levy A, et al. Reappraisal of clinical outcome in adult medulloblastomas with emphasis on patterns of relapse. *Br J Neurosurg* 2010;24:460-467. Available at: <http://www.ncbi.nlm.nih.gov/pubmed/20726753>.

144. Douglas JG, Barker JL, Ellenbogen RG, Geyer JR. Concurrent chemotherapy and reduced-dose cranial spinal irradiation followed by conformal posterior fossa tumor bed boost for average-risk medulloblastoma: efficacy and patterns of failure. *Int J Radiat Oncol Biol Phys* 2004;58:1161-1164. Available at: <http://www.ncbi.nlm.nih.gov/pubmed/15001259>.

145. Merchant TE, Kun LE, Krasin MJ, et al. Multi-institution prospective trial of reduced-dose craniospinal irradiation (23.4 Gy) followed by conformal posterior fossa (36 Gy) and primary site irradiation (55.8 Gy) and dose-intensive chemotherapy for average-risk medulloblastoma. *Int J Radiat Oncol Biol Phys* 2008;70:782-787. Available at: <http://www.ncbi.nlm.nih.gov/pubmed/17892918>.

146. Deutsch M, Thomas PR, Krischer J, et al. Results of a prospective randomized trial comparing standard dose neuraxis irradiation (3,600 cGy/20) with reduced neuraxis irradiation (2,340 cGy/13) in patients with low-stage medulloblastoma. A Combined Children's Cancer Group-Pediatric Oncology Group Study. *Pediatr Neurosurg* 1996;24:167-176; discussion 176-167. Available at: <http://www.ncbi.nlm.nih.gov/pubmed/8873158>.

147. Brown AP, Barney CL, Grosshans DR, et al. Proton beam craniospinal irradiation reduces acute toxicity for adults with medulloblastoma. *Int J Radiat Oncol Biol Phys* 2013;86:277-284. Available at: <http://www.ncbi.nlm.nih.gov/pubmed/23433794>.

148. Germanwala AV, Mai JC, Tomycz ND, et al. Boost Gamma Knife surgery during multimodality management of adult medulloblastoma. *J*



## NCCN Guidelines Version 2.2014 Central Nervous System Cancers

Neurosurg 2008;108:204-209. Available at:  
<http://www.ncbi.nlm.nih.gov/pubmed/18240913>.

149. Riffaud L, Saikali S, Leray E, et al. Survival and prognostic factors in a series of adults with medulloblastomas. J Neurosurg 2009;111:478-487. Available at: <http://www.ncbi.nlm.nih.gov/pubmed/19231932>.

150. Herrlinger U, Steinbrecher A, Rieger J, et al. Adult medulloblastoma: prognostic factors and response to therapy at diagnosis and at relapse. J Neurol 2005;252:291-299. Available at: <http://www.ncbi.nlm.nih.gov/pubmed/16189725>.

151. Packer RJ, Gajjar A, Vezina G, et al. Phase III study of craniospinal radiation therapy followed by adjuvant chemotherapy for newly diagnosed average-risk medulloblastoma. J Clin Oncol 2006;24:4202-4208. Available at: <http://www.ncbi.nlm.nih.gov/pubmed/16943538>.

152. Ashley DM, Meier L, Kerby T, et al. Response of recurrent medulloblastoma to low-dose oral etoposide. J Clin Oncol 1996;14:1922-1927. Available at: <http://www.ncbi.nlm.nih.gov/pubmed/8656261>.

153. Chamberlain MC, Kormanik PA. Chronic oral VP-16 for recurrent medulloblastoma. Pediatr Neurol 1997;17:230-234. Available at: <http://www.ncbi.nlm.nih.gov/pubmed/9390699>.

154. Dunkel IJ, Gardner SL, Garvin JH, Jr., et al. High-dose carboplatin, thiotepa, and etoposide with autologous stem cell rescue for patients with previously irradiated recurrent medulloblastoma. Neuro Oncol 2010;12:297-303. Available at: <http://www.ncbi.nlm.nih.gov/pubmed/20167818>.

155. Nicholson HS, Kretschmar CS, Krailo M, et al. Phase 2 study of temozolomide in children and adolescents with recurrent central nervous system tumors: a report from the Children's Oncology Group. Cancer 2007;110:1542-1550. Available at: <http://www.ncbi.nlm.nih.gov/pubmed/17705175>.

156. Gill P, Litzow M, Buckner J, et al. High-dose chemotherapy with autologous stem cell transplantation in adults with recurrent embryonal tumors of the central nervous system. Cancer 2008;112:1805-1811. Available at: <http://www.ncbi.nlm.nih.gov/pubmed/18300237>.

157. Cohen ME, Duffner P, eds. Brain tumors in children (ed 2). New York: McGraw-Hill; 1994.

158. Chang CH, Housepian EM, Herbert C, Jr. An operative staging system and a megavoltage radiotherapeutic technic for cerebellar medulloblastomas. Radiology 1969;93:1351-1359. Available at: <http://www.ncbi.nlm.nih.gov/pubmed/4983156>.

159. Brandes AA, Franceschi E, Tosoni A, et al. Adult neuroectodermal tumors of posterior fossa (medulloblastoma) and of supratentorial sites (stPNET). Crit Rev Oncol Hematol 2009;71:165-179. Available at: <http://www.ncbi.nlm.nih.gov/pubmed/19303318>.

160. Olson JE, Janney CA, Rao RD, et al. The continuing increase in the incidence of primary central nervous system non-Hodgkin lymphoma: a surveillance, epidemiology, and end results analysis. Cancer 2002;95:1504-1510. Available at: <http://www.ncbi.nlm.nih.gov/pubmed/12237919>.

161. Fine HA, Mayer RJ. Primary central nervous system lymphoma. Ann Intern Med 1993;119:1093-1104. Available at: <http://www.ncbi.nlm.nih.gov/pubmed/8239229>.

162. Norden AD, Drappatz J, Wen PY, Claus EB. Survival among patients with primary central nervous system lymphoma, 1973-2004. J Neurooncol 2010. Available at: <http://www.ncbi.nlm.nih.gov/pubmed/20556477>.

163. Gerstner ER, Batchelor TT. Primary central nervous system lymphoma. Arch Neurol 2010;67:291-297. Available at: <http://www.ncbi.nlm.nih.gov/pubmed/20212226>.



164. Bataille B, Delwail V, Menet E, et al. Primary intracerebral malignant lymphoma: report of 248 cases. *J Neurosurg* 2000;92:261-266. Available at: <http://www.ncbi.nlm.nih.gov/pubmed/10659013>.

165. Abrey LE, Batchelor TT, Ferreri AJM, et al. Report of an international workshop to standardize baseline evaluation and response criteria for primary CNS lymphoma. *J Clin Oncol* 2005;23:5034-5043. Available at: <http://www.ncbi.nlm.nih.gov/pubmed/15955902>.

166. Batchelor T, Carson K, O'Neill A, et al. Treatment of primary CNS lymphoma with methotrexate and deferred radiotherapy: a report of NABTT 96-07. *J Clin Oncol* 2003;21:1044-1049. Available at: <http://www.ncbi.nlm.nih.gov/pubmed/12637469>.

167. Chamberlain MC, Johnston SK. High-dose methotrexate and rituximab with deferred radiotherapy for newly diagnosed primary B-cell CNS lymphoma. *Neuro Oncol* 2010;12:736-744. Available at: <http://www.ncbi.nlm.nih.gov/pubmed/20511181>.

168. DeAngelis LM, Seiferheld W, Schold SC, et al. Combination chemotherapy and radiotherapy for primary central nervous system lymphoma: Radiation Therapy Oncology Group Study 93-10. *J Clin Oncol* 2002;20:4643-4648. Available at: <http://www.ncbi.nlm.nih.gov/pubmed/12488408>.

169. Ferreri AJ, Reni M, Foppoli M, et al. High-dose cytarabine plus high-dose methotrexate versus high-dose methotrexate alone in patients with primary CNS lymphoma: a randomised phase 2 trial. *Lancet* 2009;374:1512-1520. Available at: <http://www.ncbi.nlm.nih.gov/pubmed/19767089>.

170. Gavrilovic IT, Hormigo A, Yahalom J, et al. Long-term follow-up of high-dose methotrexate-based therapy with and without whole brain irradiation for newly diagnosed primary CNS lymphoma. *J Clin Oncol* 2006;24:4570-4574. Available at: <http://www.ncbi.nlm.nih.gov/pubmed/17008697>.

171. Shah GD, Yahalom J, Correa DD, et al. Combined immunochemotherapy with reduced whole-brain radiotherapy for newly diagnosed primary CNS lymphoma. *J Clin Oncol* 2007;25:4730-4735. Available at: <http://www.ncbi.nlm.nih.gov/pubmed/17947720>.

172. Thiel E, Korfel A, Martus P, et al. High-dose methotrexate with or without whole brain radiotherapy for primary CNS lymphoma (G-PCNSL-SG-1): a phase 3, randomised, non-inferiority trial. *Lancet Oncol* 2010;11:1036-1047. Available at: <http://www.ncbi.nlm.nih.gov/pubmed/20970380>.

173. Wieduwilt MJ, Valles F, Issa S, et al. Immunochemotherapy with Intensive Consolidation for Primary Central Nervous System Lymphoma: A Pilot Study and Prognostic Assessment by Diffusion-Weighted MRI. *Clin Cancer Res* 2012. Available at: <http://www.ncbi.nlm.nih.gov/pubmed/22228634>.

174. Gregory G, Arumugaswamy A, Leung T, et al. Rituximab is associated with improved survival for aggressive B cell CNS lymphoma. *Neuro Oncol* 2013;15:1068-1073. Available at: <http://www.ncbi.nlm.nih.gov/pubmed/23502429>.

175. Khan RB, Shi W, Thaler HT, et al. Is intrathecal methotrexate necessary in the treatment of primary CNS lymphoma? *J Neurooncol* 2002;58:175-178. Available at: <http://www.ncbi.nlm.nih.gov/pubmed/12164690>.

176. Widemann BC, Balis FM, Kim A, et al. Glucarpidase, leucovorin, and thymidine for high-dose methotrexate-induced renal dysfunction: clinical and pharmacologic factors affecting outcome. *J Clin Oncol* 2010;28:3979-3986. Available at: <http://www.ncbi.nlm.nih.gov/pubmed/20679598>.

177. Widemann BC, Balis FM, Kempf-Bielack B, et al. High-dose methotrexate-induced nephrotoxicity in patients with osteosarcoma. *Cancer* 2004;100:2222-2232. Available at: <http://www.ncbi.nlm.nih.gov/pubmed/15139068>.

178. Abrey LE, Yahalom J, DeAngelis LM. Treatment for primary CNS lymphoma: the next step. *J Clin Oncol* 2000;18:3144-3150. Available at: <http://www.ncbi.nlm.nih.gov/pubmed/10963643>.

179. Bessell EM, Lopez-Guillermo A, Villa S, et al. Importance of radiotherapy in the outcome of patients with primary CNS lymphoma: an analysis of the CHOD/BVAM regimen followed by two different radiotherapy treatments. *J Clin Oncol* 2002;20:231-236. Available at: <http://www.ncbi.nlm.nih.gov/pubmed/11773174>.

180. Gerstner ER, Carson KA, Grossman SA, Batchelor TT. Long-term outcome in PCNSL patients treated with high-dose methotrexate and deferred radiation. *Neurology* 2008;70:401-402. Available at: <http://www.ncbi.nlm.nih.gov/pubmed/18227422>.

181. Hoang-Xuan K, Taillandier L, Chinot O, et al. Chemotherapy alone as initial treatment for primary CNS lymphoma in patients older than 60 years: a multicenter phase II study (26952) of the European Organization for Research and Treatment of Cancer Brain Tumor Group. *J Clin Oncol* 2003;21:2726-2731. Available at: <http://www.ncbi.nlm.nih.gov/pubmed/12860951>.

182. Pels H, Schmidt-Wolf IG, Glasmacher A, et al. Primary central nervous system lymphoma: results of a pilot and phase II study of systemic and intraventricular chemotherapy with deferred radiotherapy. *J Clin Oncol* 2003;21:4489-4495. Available at: <http://www.ncbi.nlm.nih.gov/pubmed/14597744>.

183. Illerhaus G, Marks R, Muller F, et al. High-dose methotrexate combined with procarbazine and CCNU for primary CNS lymphoma in the elderly: results of a prospective pilot and phase II study. *Ann Oncol* 2009;20:319-325. Available at: <http://www.ncbi.nlm.nih.gov/pubmed/18953065>.

184. Juergens A, Pels H, Rogowski S, et al. Long-term survival with favorable cognitive outcome after chemotherapy in primary central nervous system lymphoma. *Ann Neurol* 2010;67:182-189. Available at: <http://www.ncbi.nlm.nih.gov/pubmed/20225195>.

185. Plotkin SR, Betensky RA, Hochberg FH, et al. Treatment of relapsed central nervous system lymphoma with high-dose methotrexate. *Clin Cancer Res* 2004;10:5643-5646. Available at: <http://www.ncbi.nlm.nih.gov/pubmed/15355887>.

186. Reni M, Mason W, Zaja F, et al. Salvage chemotherapy with temozolomide in primary CNS lymphomas: preliminary results of a phase II trial. *Eur J Cancer* 2004;40:1682-1688. Available at: <http://www.ncbi.nlm.nih.gov/pubmed/15251157>.

187. Reni M, Zaja F, Mason W, et al. Temozolomide as salvage treatment in primary brain lymphomas. *Br J Cancer* 2007;96:864-867. Available at: <http://www.ncbi.nlm.nih.gov/pubmed/17325700>.

188. Schulz H, Pels H, Schmidt-Wolf I, et al. Intraventricular treatment of relapsed central nervous system lymphoma with the anti-CD20 antibody rituximab. *Haematologica* 2004;89:753-754. Available at: <http://www.ncbi.nlm.nih.gov/pubmed/15194546>.

189. Enting RH, Demopoulos A, DeAngelis LM, Abrey LE. Salvage therapy for primary CNS lymphoma with a combination of rituximab and temozolomide. *Neurology* 2004;63:901-903. Available at: <http://www.ncbi.nlm.nih.gov/pubmed/15365145>.

190. Voloschin AD, Betensky R, Wen PY, et al. Topotecan as salvage therapy for relapsed or refractory primary central nervous system lymphoma. *J Neurooncol* 2008;86:211-215. Available at: <http://www.ncbi.nlm.nih.gov/pubmed/17896078>.

191. DeAngelis LM, Kreis W, Chan K, et al. Pharmacokinetics of ara-C and ara-U in plasma and CSF after high-dose administration of cytosine arabinoside. *Cancer Chemother Pharmacol* 1992;29:173-177. Available at: <http://www.ncbi.nlm.nih.gov/pubmed/1733548>.

192. McLaughlin P, Velasquez WS, Redman JR, et al. Chemotherapy with dexamethasone, high-dose cytarabine, and cisplatin for parenchymal brain lymphoma. *J Natl Cancer Inst* 1988;80:1408-1412. Available at: <http://www.ncbi.nlm.nih.gov/pubmed/3172268>.

193. Raizer JJ, Rademaker A, Evens AM, et al. Pemetrexed in the treatment of relapsed/refractory primary central nervous system lymphoma. *Cancer* 2012;118:3743-3748. Available at: <http://www.ncbi.nlm.nih.gov/pubmed/22179954>.

194. Colombat P, Lemevel A, Bertrand P, et al. High-dose chemotherapy with autologous stem cell transplantation as first-line therapy for primary CNS lymphoma in patients younger than 60 years: a multicenter phase II study of the GOELAMS group. *Bone Marrow Transplant* 2006;38:417-420. Available at: <http://www.ncbi.nlm.nih.gov/pubmed/16951691>.

195. Montemurro M, Kiefer T, Schuler F, et al. Primary central nervous system lymphoma treated with high-dose methotrexate, high-dose busulfan/thiotepa, autologous stem-cell transplantation and response-adapted whole-brain radiotherapy: results of the multicenter Ostdeutsche Studiengruppe Hamato-Onkologie OSHO-53 phase II study. *Ann Oncol* 2007;18:665-671. Available at: <http://www.ncbi.nlm.nih.gov/pubmed/17185743>.

196. Soussain C, Suzan F, Hoang-Xuan K, et al. Results of intensive chemotherapy followed by hematopoietic stem-cell rescue in 22 patients with refractory or recurrent primary CNS lymphoma or intraocular lymphoma. *J Clin Oncol* 2001;19:742-749. Available at: <http://www.ncbi.nlm.nih.gov/pubmed/11157026>.

197. Angelov L, Doolittle ND, Kraemer DF, et al. Blood-brain barrier disruption and intra-arterial methotrexate-based therapy for newly diagnosed primary CNS lymphoma: a multi-institutional experience. *J Clin Oncol* 2009;27:3503-3509. Available at: <http://www.ncbi.nlm.nih.gov/pubmed/19451444>.

198. Neuwelt EA, Goldman DL, Dahlborg SA, et al. Primary CNS lymphoma treated with osmotic blood-brain barrier disruption: prolonged survival and preservation of cognitive function. *J Clin Oncol* 1991;9:1580-1590. Available at: <http://www.ncbi.nlm.nih.gov/pubmed/1875220>.

199. DeAngelis LM, Yahalom J, Thaler HT, Kher U. Combined modality therapy for primary CNS lymphoma. *J Clin Oncol* 1992;10:635-643. Available at: <http://www.ncbi.nlm.nih.gov/pubmed/1548527>.

200. Fisher B, Seiferheld W, Schultz C, et al. Secondary analysis of Radiation Therapy Oncology Group study (RTOG) 9310: an intergroup phase II combined modality treatment of primary central nervous system lymphoma. *J Neurooncol* 2005;74:201-205. Available at: <http://www.ncbi.nlm.nih.gov/pubmed/16193393>.

201. Nelson DF, Martz KL, Bonner H, et al. Non-Hodgkin's lymphoma of the brain: can high dose, large volume radiation therapy improve survival? Report on a prospective trial by the Radiation Therapy Oncology Group (RTOG): RTOG 8315. *Int J Radiat Oncol Biol Phys* 1992;23:9-17. Available at: <http://www.ncbi.nlm.nih.gov/pubmed/1572835>.

202. Schultz C, Scott C, Sherman W, et al. Preirradiation chemotherapy with cyclophosphamide, doxorubicin, vincristine, and dexamethasone for primary CNS lymphomas: initial report of radiation therapy oncology group protocol 88-06. *J Clin Oncol* 1996;14:556-564. Available at: <http://www.ncbi.nlm.nih.gov/pubmed/8636771>.

203. Poortmans PM, Kluijn-Nelemans HC, Haaxma-Reiche H, et al. High-dose methotrexate-based chemotherapy followed by consolidating radiotherapy in non-AIDS-related primary central nervous system lymphoma: European Organization for Research and Treatment of Cancer Lymphoma Group Phase II Trial 20962. *J Clin Oncol* 2003;21:4483-4488. Available at: <http://www.ncbi.nlm.nih.gov/pubmed/14597741>.

204. Ghesquieres H, Ferlay C, Sebban C, et al. Long-term follow-up of an age-adapted C5R protocol followed by radiotherapy in 99 newly diagnosed primary CNS lymphomas: a prospective multicentric phase II study of the Groupe d'Etude des Lymphomes de l'Adulte (GELA). *Ann Oncol* 2010;21:842-850. Available at: <http://www.ncbi.nlm.nih.gov/pubmed/19914958>.

205. Nguyen PL, Chakravarti A, Finkelstein DM, et al. Results of whole-brain radiation as salvage of methotrexate failure for immunocompetent patients with primary CNS lymphoma. *J Clin Oncol* 2005;23:1507-1513. Available at: <http://www.ncbi.nlm.nih.gov/pubmed/15735126>.

206. Coulon A, Lafitte F, Hoang-Xuan K, et al. Radiographic findings in 37 cases of primary CNS lymphoma in immunocompetent patients. *Eur Radiol* 2002;12:329-340. Available at: <http://www.ncbi.nlm.nih.gov/pubmed/11870430>.

207. Mohile NA, Deangelis LM, Abrey LE. The utility of body FDG PET in staging primary central nervous system lymphoma. *Neuro Oncol* 2008;10:223-228. Available at: <http://www.ncbi.nlm.nih.gov/pubmed/18287338>.

208. Schellinger KA, Propp JM, Villano JL, McCarthy BJ. Descriptive epidemiology of primary spinal cord tumors. *J Neurooncol* 2008;87:173-179. Available at: <http://www.ncbi.nlm.nih.gov/pubmed/18084720>.

209. Grimm S, Chamberlain MC. Adult primary spinal cord tumors. *Expert Rev Neurother* 2009;9:1487-1495. Available at: <http://www.ncbi.nlm.nih.gov/pubmed/19831838>.

210. Gezen F, Kahraman S, Canakci Z, Beduk A. Review of 36 cases of spinal cord meningioma. *Spine (Phila Pa 1976)* 2000;25:727-731. Available at: <http://www.ncbi.nlm.nih.gov/pubmed/10752106>.

211. Solero CL, Fornari M, Giombini S, et al. Spinal meningiomas: review of 174 operated cases. *Neurosurgery* 1989;25:153-160. Available at: <http://www.ncbi.nlm.nih.gov/pubmed/2671779>.

212. Volpp PB, Han K, Kagan AR, Tome M. Outcomes in treatment for intradural spinal cord ependymomas. *Int J Radiat Oncol Biol Phys* 2007;69:1199-1204. Available at: <http://www.ncbi.nlm.nih.gov/pubmed/17689025>.

213. Yang S, Yang X, Hong G. Surgical treatment of one hundred seventy-four intramedullary spinal cord tumors. *Spine (Phila Pa 1976)*

2009;34:2705-2710. Available at: <http://www.ncbi.nlm.nih.gov/pubmed/19910775>.

214. Raco A, Esposito V, Lenzi J, et al. Long-term follow-up of intramedullary spinal cord tumors: a series of 202 cases. *Neurosurgery* 2005;56:972-981; discussion 972-981. Available at: <http://www.ncbi.nlm.nih.gov/pubmed/15854245>.

215. Benes V, 3rd, Barsa P, Benes V, Jr., Suchomel P. Prognostic factors in intramedullary astrocytomas: a literature review. *Eur Spine J* 2009;18:1397-1422. Available at: <http://www.ncbi.nlm.nih.gov/pubmed/19562388>.

216. Milano MT, Johnson MD, Sul J, et al. Primary spinal cord glioma: a Surveillance, Epidemiology, and End Results database study. *J Neurooncol* 2010;98:83-92. Available at: <http://www.ncbi.nlm.nih.gov/pubmed/19898743>.

217. Sgouros S, Malluci CL, Jackowski A. Spinal ependymomas--the value of postoperative radiotherapy for residual disease control. *Br J Neurosurg* 1996;10:559-566. Available at: <http://www.ncbi.nlm.nih.gov/pubmed/9115651>.

218. Lee TT, Gromelski EB, Green BA. Surgical treatment of spinal ependymoma and post-operative radiotherapy. *Acta Neurochir (Wien)* 1998;140:309-313. Available at: <http://www.ncbi.nlm.nih.gov/pubmed/9689321>.

219. Akyurek S, Chang EL, Yu TK, et al. Spinal myxopapillary ependymoma outcomes in patients treated with surgery and radiotherapy at M.D. Anderson Cancer Center. *J Neurooncol* 2006;80:177-183. Available at: <http://www.ncbi.nlm.nih.gov/pubmed/16648988>.

220. Pica A, Miller R, Villa S, et al. The results of surgery, with or without radiotherapy, for primary spinal myxopapillary ependymoma: a retrospective study from the rare cancer network. *Int J Radiat Oncol Biol*

Phys 2009;74:1114-1120. Available at:  
<http://www.ncbi.nlm.nih.gov/pubmed/19250760>.

221. Ryu SI, Kim DH, Chang SD. Stereotactic radiosurgery for hemangiomas and ependymomas of the spinal cord. *Neurosurg Focus* 2003;15:E10. Available at:  
<http://www.ncbi.nlm.nih.gov/pubmed/15323467>.

222. Gerszten PC, Burton SA, Ozhasoglu C, et al. Radiosurgery for benign intradural spinal tumors. *Neurosurgery* 2008;62:887-895; discussion 895-886. Available at:  
<http://www.ncbi.nlm.nih.gov/pubmed/18496194>.

223. Dodd RL, Ryu MR, Kamnerdsupaphon P, et al. CyberKnife radiosurgery for benign intradural extramedullary spinal tumors. *Neurosurgery* 2006;58:674-685; discussion 674-685. Available at:  
<http://www.ncbi.nlm.nih.gov/pubmed/16575331>.

224. Garces-Ambrossi GL, McGirt MJ, Mehta VA, et al. Factors associated with progression-free survival and long-term neurological outcome after resection of intramedullary spinal cord tumors: analysis of 101 consecutive cases. *J Neurosurg Spine* 2009;11:591-599. Available at:  
<http://www.ncbi.nlm.nih.gov/pubmed/19929363>.

225. Mahmood A, Caccamo DV, Tomecek FJ, Malik GM. Atypical and malignant meningiomas: a clinicopathological review. *Neurosurgery* 1993;33:955-963. Available at:  
<http://www.ncbi.nlm.nih.gov/pubmed/8134008>.

226. Vernooij MW, Ikram MA, Tanghe HL, et al. Incidental findings on brain MRI in the general population. *N Engl J Med* 2007;357:1821-1828. Available at: <http://www.ncbi.nlm.nih.gov/pubmed/17978290>.

227. Lieu AS, Howng SL. Intracranial meningiomas and epilepsy: incidence, prognosis and influencing factors. *Epilepsy Res* 2000;38:45-52. Available at: <http://www.ncbi.nlm.nih.gov/pubmed/10604605>.

228. Campbell BA, Jhamb A, Maguire JA, et al. Meningiomas in 2009: controversies and future challenges. *Am J Clin Oncol* 2009;32:73-85. Available at: <http://www.ncbi.nlm.nih.gov/pubmed/19194129>.

229. Nathoo N, Ugokwe K, Chang AS, et al. The role of 111indium-octreotide brain scintigraphy in the diagnosis of cranial, dural-based meningiomas. *J Neurooncol* 2007;81:167-174. Available at:  
<http://www.ncbi.nlm.nih.gov/pubmed/16850106>.

230. Nyuyki F, Plotkin M, Graf R, et al. Potential impact of (68)Ga-DOTATOC PET/CT on stereotactic radiotherapy planning of meningiomas. *Eur J Nucl Med Mol Imaging* 2010;37:310-318. Available at: <http://www.ncbi.nlm.nih.gov/pubmed/19763565>.

231. Gehler B, Paulsen F, Oksuz MO, et al. [68Ga]-DOTATOC-PET/CT for meningioma IMRT treatment planning. *Radiat Oncol* 2009;4:56. Available at: <http://www.ncbi.nlm.nih.gov/pubmed/19922642>.

232. Nakamura M, Roser F, Michel J, et al. The natural history of incidental meningiomas. *Neurosurgery* 2003;53:62-70; discussion 70-61. Available at: <http://www.ncbi.nlm.nih.gov/pubmed/12823874>.

233. Olivero WC, Lister JR, Elwood PW. The natural history and growth rate of asymptomatic meningiomas: a review of 60 patients. *J Neurosurg* 1995;83:222-224. Available at:  
<http://www.ncbi.nlm.nih.gov/pubmed/7616265>.

234. Stafford SL, Perry A, Suman VJ, et al. Primarily resected meningiomas: outcome and prognostic factors in 581 Mayo Clinic patients, 1978 through 1988. *Mayo Clin Proc* 1998;73:936-942. Available at: <http://www.ncbi.nlm.nih.gov/pubmed/9787740>.

235. Mahmood A, Qureshi NH, Malik GM. Intracranial meningiomas: analysis of recurrence after surgical treatment. *Acta Neurochir (Wien)* 1994;126:53-58. Available at:  
<http://www.ncbi.nlm.nih.gov/pubmed/8042555>.

236. Mathiesen T, Lindquist C, Kihlstrom L, Karlsson B. Recurrence of cranial base meningiomas. *Neurosurgery* 1996;39:2-7; discussion 8-9. Available at: <http://www.ncbi.nlm.nih.gov/pubmed/8805134>.

237. Perry A, Stafford SL, Scheithauer BW, et al. Meningioma grading: an analysis of histologic parameters. *Am J Surg Pathol* 1997;21:1455-1465. Available at: <http://www.ncbi.nlm.nih.gov/pubmed/9414189>.

238. Simpson D. The recurrence of intracranial meningiomas after surgical treatment. *J Neurol Neurosurg Psychiatry* 1957;20:22-39. Available at: <http://www.ncbi.nlm.nih.gov/pubmed/13406590>.

239. Condra KS, Buatti JM, Mendenhall WM, et al. Benign meningiomas: primary treatment selection affects survival. *Int J Radiat Oncol Biol Phys* 1997;39:427-436. Available at: <http://www.ncbi.nlm.nih.gov/pubmed/9308947>.

240. Soyuer S, Chang EL, Selek U, et al. Radiotherapy after surgery for benign cerebral meningioma. *Radiother Oncol* 2004;71:85-90. Available at: <http://www.ncbi.nlm.nih.gov/pubmed/15066300>.

241. Aghi MK, Carter BS, Cosgrove GR, et al. Long-term recurrence rates of atypical meningiomas after gross total resection with or without postoperative adjuvant radiation. *Neurosurgery* 2009;64:56-60; discussion 60. Available at: <http://www.ncbi.nlm.nih.gov/pubmed/19145156>.

242. Hug EB, Devries A, Thornton AF, et al. Management of atypical and malignant meningiomas: role of high-dose, 3D-conformal radiation therapy. *J Neurooncol* 2000;48:151-160. Available at: <http://www.ncbi.nlm.nih.gov/pubmed/11083080>.

243. Yang SY, Park CK, Park SH, et al. Atypical and anaplastic meningiomas: prognostic implications of clinicopathological features. *J Neurol Neurosurg Psychiatry* 2008;79:574-580. Available at: <http://www.ncbi.nlm.nih.gov/pubmed/17766430>.

244. Pollock BE, Stafford SL, Utter A, et al. Stereotactic radiosurgery provides equivalent tumor control to Simpson Grade 1 resection for patients with small- to medium-size meningiomas. *Int J Radiat Oncol Biol Phys* 2003;55:1000-1005. Available at: <http://www.ncbi.nlm.nih.gov/pubmed/12605979>.

245. Kondziolka D, Mathieu D, Lunsford LD, et al. Radiosurgery as definitive management of intracranial meningiomas. *Neurosurgery* 2008;62:53-58; discussion 58-60. Available at: <http://www.ncbi.nlm.nih.gov/pubmed/18300891>.

246. Compter I, Zaugg K, Houben RM, et al. High symptom improvement and local tumor control using stereotactic radiotherapy when given early after diagnosis of meningioma. A multicentre study. *Strahlenther Onkol* 2012;188:887-893. Available at: <http://www.ncbi.nlm.nih.gov/pubmed/22961046>.

247. Chamberlain MC, Glantz MJ, Fadul CE. Recurrent meningioma: salvage therapy with long-acting somatostatin analogue. *Neurology* 2007;69:969-973. Available at: <http://www.ncbi.nlm.nih.gov/pubmed/17785665>.

248. Johnson DR, Kimmel DW, Burch PA, et al. Phase II study of subcutaneous octreotide in adults with recurrent or progressive meningioma and meningeal hemangiopericytoma. *Neuro Oncol* 2011;13:530-535. Available at: <http://www.ncbi.nlm.nih.gov/pubmed/21558077>.

249. Chamberlain MC, Glantz MJ. Interferon-alpha for recurrent World Health Organization grade 1 intracranial meningiomas. *Cancer* 2008;113:2146-2151. Available at: <http://www.ncbi.nlm.nih.gov/pubmed/18756531>.

250. Barnholtz-Sloan JS, Sloan AE, Davis FG, et al. Incidence proportions of brain metastases in patients diagnosed (1973 to 2001) in the Metropolitan Detroit Cancer Surveillance System. *J Clin Oncol* 2004;22:2865-2872. Available at: <http://www.ncbi.nlm.nih.gov/pubmed/15254054>.

251. Schouten LJ, Rutten J, Huveneers HA, Twijnstra A. Incidence of brain metastases in a cohort of patients with carcinoma of the breast, colon, kidney, and lung and melanoma. *Cancer* 2002;94:2698-2705. Available at: <http://www.ncbi.nlm.nih.gov/pubmed/12173339>.

252. Lin NU, Bellon JR, Winer EP. CNS metastases in breast cancer. *J Clin Oncol* 2004;22:3608-3617. Available at: <http://www.ncbi.nlm.nih.gov/pubmed/15337811>.

253. Eichler AF, Loeffler JS. Multidisciplinary management of brain metastases. *Oncologist* 2007;12:884-898. Available at: <http://www.ncbi.nlm.nih.gov/pubmed/17673619>.

254. Barker FG, 2nd. Craniotomy for the resection of metastatic brain tumors in the U.S., 1988-2000: decreasing mortality and the effect of provider caseload. *Cancer* 2004;100:999-1007. Available at: <http://www.ncbi.nlm.nih.gov/pubmed/14983496>.

255. Patchell RA, Tibbs PA, Regine WF, et al. Postoperative radiotherapy in the treatment of single metastases to the brain: a randomized trial. *JAMA* 1998;280:1485-1489. Available at: <http://www.ncbi.nlm.nih.gov/pubmed/9809728>.

256. Paek SH, Audu PB, Sperling MR, et al. Reevaluation of surgery for the treatment of brain metastases: review of 208 patients with single or multiple brain metastases treated at one institution with modern neurosurgical techniques. *Neurosurgery* 2005;56:1021-1034; discussion 1021-1034. Available at: <http://www.ncbi.nlm.nih.gov/pubmed/15854250>.

257. Stark AM, Tscheslog H, Buhl R, et al. Surgical treatment for brain metastases: prognostic factors and survival in 177 patients. *Neurosurg Rev* 2005;28:115-119. Available at: <http://www.ncbi.nlm.nih.gov/pubmed/15609059>.

258. Suh JH. Stereotactic radiosurgery for the management of brain metastases. *N Engl J Med* 2010;362:1119-1127. Available at: <http://www.ncbi.nlm.nih.gov/pubmed/20335588>.

259. Bhatnagar AK, Flickinger JC, Kondziolka D, Lunsford LD. Stereotactic radiosurgery for four or more intracranial metastases. *Int J Radiat Oncol Biol Phys* 2006;64:898-903. Available at: <http://www.ncbi.nlm.nih.gov/pubmed/16338097>.

260. Bhatnagar AK, Kondziolka D, Lunsford LD, Flickinger JC. Recursive partitioning analysis of prognostic factors for patients with four or more intracranial metastases treated with radiosurgery. *Technol Cancer Res Treat* 2007;6:153-160. Available at: <http://www.ncbi.nlm.nih.gov/pubmed/17535022>.

261. Banfill KE, Bownes PJ, St Clair SE, et al. Stereotactic radiosurgery for the treatment of brain metastases: impact of cerebral disease burden on survival. *Br J Neurosurg* 2012;26:674-678. Available at: <http://www.ncbi.nlm.nih.gov/pubmed/22747250>.

262. Chang WS, Kim HY, Chang JW, et al. Analysis of radiosurgical results in patients with brain metastases according to the number of brain lesions: is stereotactic radiosurgery effective for multiple brain metastases? *J Neurosurg* 2010;113 Suppl:73-78. Available at: <http://www.ncbi.nlm.nih.gov/pubmed/21121789>.

263. Karlsson B, Hanssens P, Wolff R, et al. Thirty years' experience with Gamma Knife surgery for metastases to the brain. *J Neurosurg* 2009;111:449-457. Available at: <http://www.ncbi.nlm.nih.gov/pubmed/19199505>.

264. Kased N, Binder DK, McDermott MW, et al. Gamma Knife radiosurgery for brain metastases from primary breast cancer. *Int J Radiat Oncol Biol Phys* 2009;75:1132-1140. Available at: <http://www.ncbi.nlm.nih.gov/pubmed/19345514>.

265. Hanson PW, Elaimy AL, Lamoreaux WT, et al. A concise review of the efficacy of stereotactic radiosurgery in the management of melanoma and renal cell carcinoma brain metastases. *World J Surg Oncol* 2012;10:176. Available at: <http://www.ncbi.nlm.nih.gov/pubmed/22931379>.



266. Hunter GK, Suh JH, Reuther AM, et al. Treatment of five or more brain metastases with stereotactic radiosurgery. *Int J Radiat Oncol Biol Phys* 2012;83:1394-1398. Available at:

<http://www.ncbi.nlm.nih.gov/pubmed/22209150>.

267. Aoyama H, Shirato H, Tago M, et al. Stereotactic radiosurgery plus whole-brain radiation therapy vs stereotactic radiosurgery alone for treatment of brain metastases: a randomized controlled trial. *JAMA* 2006;295:2483-2491. Available at:

<http://www.ncbi.nlm.nih.gov/pubmed/16757720>.

268. Chang EL, Wefel JS, Hess KR, et al. Neurocognition in patients with brain metastases treated with radiosurgery or radiosurgery plus whole-brain irradiation: a randomised controlled trial. *Lancet Oncol* 2009;10:1037-1044. Available at:

<http://www.ncbi.nlm.nih.gov/pubmed/19801201>.

269. Kocher M, Soffietti R, Abacioglu U, et al. Adjuvant whole-brain radiotherapy versus observation after radiosurgery or surgical resection of one to three cerebral metastases: results of the EORTC 22952-26001 study. *J Clin Oncol* 2011;29:134-141. Available at:

<http://www.ncbi.nlm.nih.gov/pubmed/21041710>.

270. Tsao M, Xu W, Sahgal A. A meta-analysis evaluating stereotactic radiosurgery, whole-brain radiotherapy, or both for patients presenting with a limited number of brain metastases. *Cancer* 2012;118:2486-2493. Available at: <http://www.ncbi.nlm.nih.gov/pubmed/21887683>.

271. O'Neill BP, Iturria NJ, Link MJ, et al. A comparison of surgical resection and stereotactic radiosurgery in the treatment of solitary brain metastases. *Int J Radiat Oncol Biol Phys* 2003;55:1169-1176. Available at: <http://www.ncbi.nlm.nih.gov/pubmed/12654423>.

272. Rades D, Kueter JD, Veninga T, et al. Whole brain radiotherapy plus stereotactic radiosurgery (WBRT+SRS) versus surgery plus whole brain radiotherapy (OP+WBRT) for 1-3 brain metastases: results of a matched pair analysis. *Eur J Cancer* 2009;45:400-404. Available at:

<http://www.ncbi.nlm.nih.gov/pubmed/19062269>.

273. Schoggl A, Kitz K, Reddy M, et al. Defining the role of stereotactic radiosurgery versus microsurgery in the treatment of single brain metastases. *Acta Neurochir (Wien)* 2000;142:621-626. Available at:

<http://www.ncbi.nlm.nih.gov/pubmed/10949435>.

274. Yamamoto M, Serizawa T, Shuto T, et al. Stereotactic radiosurgery for patients with multiple brain metastases (JLGK0901): a multi-institutional prospective observational study. *Lancet Oncol* 2014;15:387-395. Available at: <http://www.ncbi.nlm.nih.gov/pubmed/24621620>.

275. Muacevic A, Wowra B, Siefert A, et al. Microsurgery plus whole brain irradiation versus Gamma Knife surgery alone for treatment of single metastases to the brain: a randomized controlled multicentre phase III trial. *J Neurooncol* 2008;87:299-307. Available at:

<http://www.ncbi.nlm.nih.gov/pubmed/18157648>.

276. Akyurek S, Chang EL, Mahajan A, et al. Stereotactic radiosurgical treatment of cerebral metastases arising from breast cancer. *Am J Clin Oncol* 2007;30:310-314. Available at:

<http://www.ncbi.nlm.nih.gov/pubmed/17551311>.

277. Loeffler JS, Kooy HM, Wen PY, et al. The treatment of recurrent brain metastases with stereotactic radiosurgery. *J Clin Oncol* 1990;8:576-582. Available at:

<http://www.ncbi.nlm.nih.gov/pubmed/2179476>.

278. Noel G, Medioni J, Valery CA, et al. Three irradiation treatment options including radiosurgery for brain metastases from primary lung cancer. *Lung Cancer* 2003;41:333-343. Available at:

<http://www.ncbi.nlm.nih.gov/pubmed/12928124>.

279. Noel G, Proudhom MA, Valery CA, et al. Radiosurgery for re-irradiation of brain metastasis: results in 54 patients. *Radiother Oncol* 2001;60:61-67. Available at:

<http://www.ncbi.nlm.nih.gov/pubmed/11410305>.

280. Sheehan J, Kondziolka D, Flickinger J, Lunsford LD. Radiosurgery for patients with recurrent small cell lung carcinoma metastatic to the



## NCCN Guidelines Version 2.2014 Central Nervous System Cancers

brain: outcomes and prognostic factors. *J Neurosurg* 2005;102 Suppl:247-254. Available at:  
<http://www.ncbi.nlm.nih.gov/pubmed/15662819>.

281. Caballero JA, Sneed PK, Lamborn KR, et al. Prognostic factors for survival in patients treated with stereotactic radiosurgery for recurrent brain metastases after prior whole brain radiotherapy. *Int J Radiat Oncol Biol Phys* 2012;83:303-309. Available at:  
<http://www.ncbi.nlm.nih.gov/pubmed/22079723>.

282. Patchell RA, Tibbs PA, Walsh JW, et al. A randomized trial of surgery in the treatment of single metastases to the brain. *N Engl J Med* 1990;322:494-500. Available at:  
<http://www.ncbi.nlm.nih.gov/pubmed/2405271>.

283. Vecht CJ, Haaxma-Reiche H, Noordijk EM, et al. Treatment of single brain metastasis: radiotherapy alone or combined with neurosurgery? *Ann Neurol* 1993;33:583-590. Available at:  
<http://www.ncbi.nlm.nih.gov/pubmed/8498838>.

284. Mintz AH, Kestle J, Rathbone MP, et al. A randomized trial to assess the efficacy of surgery in addition to radiotherapy in patients with a single cerebral metastasis. *Cancer* 1996;78:1470-1476. Available at:  
<http://www.ncbi.nlm.nih.gov/pubmed/8839553>.

285. Andrews DW, Scott CB, Sperduto PW, et al. Whole brain radiation therapy with or without stereotactic radiosurgery boost for patients with one to three brain metastases: phase III results of the RTOG 9508 randomised trial. *Lancet* 2004;363:1665-1672. Available at:  
<http://www.ncbi.nlm.nih.gov/pubmed/15158627>.

286. Kondziolka D, Patel A, Lunsford LD, et al. Stereotactic radiosurgery plus whole brain radiotherapy versus radiotherapy alone for patients with multiple brain metastases. *Int J Radiat Oncol Biol Phys* 1999;45:427-434. Available at:  
<http://www.ncbi.nlm.nih.gov/pubmed/10487566>.

287. Patil CG, Pricola K, Sarmiento JM, et al. Whole brain radiation therapy (WBRT) alone versus WBRT and radiosurgery for the treatment of brain metastases. *Cochrane Database Syst Rev* 2012;9:CD006121. Available at: <http://www.ncbi.nlm.nih.gov/pubmed/22972090>.

288. Cooper JS, Steinfield AD, Lerch IA. Cerebral metastases: value of reirradiation in selected patients. *Radiology* 1990;174:883-885. Available at: <http://www.ncbi.nlm.nih.gov/pubmed/2305074>.

289. Sadikov E, Bezjak A, Yi QL, et al. Value of whole brain re-irradiation for brain metastases--single centre experience. *Clin Oncol (R Coll Radiol)* 2007;19:532-538. Available at:  
<http://www.ncbi.nlm.nih.gov/pubmed/17662582>.

290. Wong WW, Schild SE, Sawyer TE, Shaw EG. Analysis of outcome in patients reirradiated for brain metastases. *Int J Radiat Oncol Biol Phys* 1996;34:585-590. Available at:  
<http://www.ncbi.nlm.nih.gov/pubmed/8621282>.

291. Guerrieri M, Wong K, Ryan G, et al. A randomised phase III study of palliative radiation with concomitant carboplatin for brain metastases from non-small cell carcinoma of the lung. *Lung Cancer* 2004;46:107-111. Available at: <http://www.ncbi.nlm.nih.gov/pubmed/15364138>.

292. Verger E, Gil M, Yaya R, et al. Temozolomide and concomitant whole brain radiotherapy in patients with brain metastases: a phase II randomized trial. *Int J Radiat Oncol Biol Phys* 2005;61:185-191. Available at: <http://www.ncbi.nlm.nih.gov/pubmed/15629610>.

293. Antonadou D, Paraskevidis M, Sarris G, et al. Phase II randomized trial of temozolomide and concurrent radiotherapy in patients with brain metastases. *J Clin Oncol* 2002;20:3644-3650. Available at: <http://www.ncbi.nlm.nih.gov/pubmed/12202665>.

294. Ewend MG, Brem S, Gilbert M, et al. Treatment of single brain metastasis with resection, intracavity carmustine polymer wafers, and radiation therapy is safe and provides excellent local control. *Clin*



Cancer Res 2007;13:3637-3641. Available at:  
<http://www.ncbi.nlm.nih.gov/pubmed/17575228>.

295. Agarwala SS, Kirkwood JM, Gore M, et al. Temozolomide for the treatment of brain metastases associated with metastatic melanoma: a phase II study. J Clin Oncol 2004;22:2101-2107. Available at:  
<http://www.ncbi.nlm.nih.gov/pubmed/15169796>.

296. Krown SE, Niedzwiecki D, Hwu WJ, et al. Phase II study of temozolomide and thalidomide in patients with metastatic melanoma in the brain: high rate of thromboembolic events (CALGB 500102). Cancer 2006;107:1883-1890. Available at:  
<http://www.ncbi.nlm.nih.gov/pubmed/16986123>.

297. Lassman AB, Abrey LE, Shah GD, et al. Systemic high-dose intravenous methotrexate for central nervous system metastases. J Neurooncol 2006;78:255-260. Available at:  
<http://www.ncbi.nlm.nih.gov/pubmed/16344918>.

298. Cocconi G, Lottici R, Bisagni G, et al. Combination therapy with platinum and etoposide of brain metastases from breast carcinoma. Cancer Invest 1990;8:327-334. Available at:  
<http://www.ncbi.nlm.nih.gov/pubmed/2207757>.

299. Franciosi V, Cocconi G, Michiara M, et al. Front-line chemotherapy with cisplatin and etoposide for patients with brain metastases from breast carcinoma, nonsmall cell lung carcinoma, or malignant melanoma: a prospective study. Cancer 1999;85:1599-1605. Available at:  
<http://www.ncbi.nlm.nih.gov/pubmed/10193952>.

300. Rivera E, Meyers C, Groves M, et al. Phase I study of capecitabine in combination with temozolomide in the treatment of patients with brain metastases from breast carcinoma. Cancer 2006;107:1348-1354. Available at:  
<http://www.ncbi.nlm.nih.gov/pubmed/16909414>.

301. Metro G, Foglietta J, Russillo M, et al. Clinical outcome of patients with brain metastases from HER2-positive breast cancer treated with

lapatinib and capecitabine. Ann Oncol 2011;22:625-630. Available at:  
<http://www.ncbi.nlm.nih.gov/pubmed/20724575>.

302. Sutherland S, Ashley S, Miles D, et al. Treatment of HER2-positive metastatic breast cancer with lapatinib and capecitabine in the lapatinib expanded access programme, including efficacy in brain metastases--the UK experience. Br J Cancer 2010;102:995-1002. Available at:  
<http://www.ncbi.nlm.nih.gov/pubmed/20179708>.

303. Hedde JP, Neuhaus T, Schuller H, et al. A phase I/II trial of topotecan and radiation therapy for brain metastases in patients with solid tumors. Int J Radiat Oncol Biol Phys 2007;68:839-844. Available at:  
<http://www.ncbi.nlm.nih.gov/pubmed/17379446>.

304. Neuhaus T, Ko Y, Muller RP, et al. A phase III trial of topotecan and whole brain radiation therapy for patients with CNS-metastases due to lung cancer. Br J Cancer 2009;100:291-297. Available at:  
<http://www.ncbi.nlm.nih.gov/pubmed/19127261>.

305. Margolin K, Ernstoff MS, Hamid O, et al. Ipilimumab in patients with melanoma and brain metastases: an open-label, phase 2 trial. Lancet Oncol 2012;13:459-465. Available at:  
<http://www.ncbi.nlm.nih.gov/pubmed/22456429>.

306. Long GV, Trefzer U, Davies MA, et al. Dabrafenib in patients with Val600Glu or Val600Lys BRAF-mutant melanoma metastatic to the brain (BREAK-MB): a multicentre, open-label, phase 2 trial. Lancet Oncol 2012;13:1087-1095. Available at:  
<http://www.ncbi.nlm.nih.gov/pubmed/23051966>.

307. Dummer R, Goldinger SM, Turttschi CP, et al. Vemurafenib in patients with BRAF(V600) mutation-positive melanoma with symptomatic brain metastases: final results of an open-label pilot study. Eur J Cancer 2014;50:611-621. Available at:  
<http://www.ncbi.nlm.nih.gov/pubmed/24295639>.

308. Lang FF, Chang EL, Abi-Said D. Metastatic brain tumors. In: Winn H, ed. Youman's Neurological Surgery (ed 5th). Philadelphia: Saunders; 2004:1077-1097.
309. Pavlidis N. The diagnostic and therapeutic management of leptomeningeal carcinomatosis. *Ann Oncol* 2004;15 Suppl 4:iv285-291. Available at: <http://www.ncbi.nlm.nih.gov/pubmed/15477323>.
310. Waki F, Ando M, Takashima A, et al. Prognostic factors and clinical outcomes in patients with leptomeningeal metastasis from solid tumors. *J Neurooncol* 2009;93:205-212. Available at: <http://www.ncbi.nlm.nih.gov/pubmed/19043775>.
311. Clarke JL, Perez HR, Jacks LM, et al. Leptomeningeal metastases in the MRI era. *Neurology* 2010;74:1449-1454. Available at: <http://www.ncbi.nlm.nih.gov/pubmed/20439847>.
312. Liaw CC, Ng KT, Huang JS, et al. Meningeal carcinomatosis from solid tumors: clinical analysis of 42 cases. *J Formos Med Assoc* 1992;91:299-303. Available at: <http://www.ncbi.nlm.nih.gov/pubmed/1354692>.
313. Wasserstrom WR, Glass JP, Posner JB. Diagnosis and treatment of leptomeningeal metastases from solid tumors: experience with 90 patients. *Cancer* 1982;49:759-772. Available at: <http://www.ncbi.nlm.nih.gov/pubmed/6895713>.
314. Sandberg DI, Bilsky MH, Souweidane MM, et al. Ommaya reservoirs for the treatment of leptomeningeal metastases. *Neurosurgery* 2000;47:49-54; discussion 54-45. Available at: <http://www.ncbi.nlm.nih.gov/pubmed/10917346>.
315. Fleischhack G, Jaehde U, Bode U. Pharmacokinetics following intraventricular administration of chemotherapy in patients with neoplastic meningitis. *Clin Pharmacokinet* 2005;44:1-31. Available at: <http://www.ncbi.nlm.nih.gov/pubmed/15634030>.
316. Boogerd W, van den Bent MJ, Koehler PJ, et al. The relevance of intraventricular chemotherapy for leptomeningeal metastasis in breast cancer: a randomised study. *Eur J Cancer* 2004;40:2726-2733. Available at: <http://www.ncbi.nlm.nih.gov/pubmed/15571954>.
317. Glantz MJ, Jaeckle KA, Chamberlain MC, et al. A randomized controlled trial comparing intrathecal sustained-release cytarabine (DepoCyt) to intrathecal methotrexate in patients with neoplastic meningitis from solid tumors. *Clin Cancer Res* 1999;5:3394-3402. Available at: <http://www.ncbi.nlm.nih.gov/pubmed/10589750>.
318. Grossman SA, Finkelstein DM, Ruckdeschel JC, et al. Randomized prospective comparison of intraventricular methotrexate and thiotepa in patients with previously untreated neoplastic meningitis. Eastern Cooperative Oncology Group. *J Clin Oncol* 1993;11:561-569. Available at: <http://www.ncbi.nlm.nih.gov/pubmed/8445432>.
319. Chamberlain MC, Johnston SK, Van Horn A, Glantz MJ. Recurrent lymphomatous meningitis treated with intra-CSF rituximab and liposomal ara-C. *J Neurooncol* 2009;91:271-277. Available at: <http://www.ncbi.nlm.nih.gov/pubmed/18820836>.
320. Groves MD, Glantz MJ, Chamberlain MC, et al. A multicenter phase II trial of intrathecal topotecan in patients with meningeal malignancies. *Neuro Oncol* 2008;10:208-215. Available at: <http://www.ncbi.nlm.nih.gov/pubmed/18316473>.
321. Chamberlain MC, Tsao-Wei DD, Groshen S. Phase II trial of intracerebrospinal fluid etoposide in the treatment of neoplastic meningitis. *Cancer* 2006;106:2021-2027. Available at: <http://www.ncbi.nlm.nih.gov/pubmed/16583432>.
322. Zagouri F, Sergentanis TN, Bartsch R, et al. Intrathecal administration of trastuzumab for the treatment of meningeal carcinomatosis in HER2-positive metastatic breast cancer: a systematic review and pooled analysis. *Breast Cancer Res Treat* 2013;139:13-22. Available at: <http://www.ncbi.nlm.nih.gov/pubmed/23588955>.



323. Chamberlain MC. A phase II trial of intra-cerebrospinal fluid alpha interferon in the treatment of neoplastic meningitis. *Cancer* 2002;94:2675-2680. Available at: <http://www.ncbi.nlm.nih.gov/pubmed/12173336>.

324. Glantz MJ, LaFollette S, Jaeckle KA, et al. Randomized trial of a slow-release versus a standard formulation of cytarabine for the intrathecal treatment of lymphomatous meningitis. *J Clin Oncol* 1999;17:3110-3116. Available at: <http://www.ncbi.nlm.nih.gov/pubmed/10506606>.

325. Grommes C, Oxnard GR, Kris MG, et al. "Pulsatile" high-dose weekly erlotinib for CNS metastases from EGFR mutant non-small cell lung cancer. *Neuro Oncol* 2011;13:1364-1369. Available at: <http://www.ncbi.nlm.nih.gov/pubmed/21865399>.

326. Wong DA, Fornasier VL, MacNab I. Spinal metastases: the obvious, the occult, and the impostors. *Spine (Phila Pa 1976)* 1990;15:1-4. Available at: <http://www.ncbi.nlm.nih.gov/pubmed/2326692>.

327. Ibrahim A, Crockard A, Antonietti P, et al. Does spinal surgery improve the quality of life for those with extradural (spinal) osseous metastases? An international multicenter prospective observational study of 223 patients. Invited submission from the Joint Section Meeting on Disorders of the Spine and Peripheral Nerves, March 2007. *J Neurosurg Spine* 2008;8:271-278. Available at: <http://www.ncbi.nlm.nih.gov/pubmed/18312079>.

328. Byrne TN. Spinal cord compression from epidural metastases. *N Engl J Med* 1992;327:614-619. Available at: <http://www.ncbi.nlm.nih.gov/pubmed/1296600>.

329. Schmidt MH, Klimo P, Jr., Vrionis FD. Metastatic spinal cord compression. *J Natl Compr Canc Netw* 2005;3:711-719. Available at: <http://www.ncbi.nlm.nih.gov/pubmed/16194459>.

330. Helweg-Larsen S, Sorensen PS. Symptoms and signs in metastatic spinal cord compression: a study of progression from first symptom until diagnosis in 153 patients. *Eur J Cancer* 1994;30A:396-398. Available at: <http://www.ncbi.nlm.nih.gov/pubmed/8204366>.

331. Levack P, Graham J, Collie D, et al. Don't wait for a sensory level--listen to the symptoms: a prospective audit of the delays in diagnosis of malignant cord compression. *Clin Oncol (R Coll Radiol)* 2002;14:472-480. Available at: <http://www.ncbi.nlm.nih.gov/pubmed/12512970>.

332. Sundaresan N, Rothman A, Manhart K, Kelliher K. Surgery for solitary metastases of the spine: rationale and results of treatment. *Spine (Phila Pa 1976)* 2002;27:1802-1806. Available at: <http://www.ncbi.nlm.nih.gov/pubmed/12195075>.

333. North RB, LaRocca VR, Schwartz J, et al. Surgical management of spinal metastases: analysis of prognostic factors during a 10-year experience. *J Neurosurg Spine* 2005;2:564-573. Available at: <http://www.ncbi.nlm.nih.gov/pubmed/15945430>.

334. Tomita K, Kawahara N, Kobayashi T, et al. Surgical strategy for spinal metastases. *Spine (Phila Pa 1976)* 2001;26:298-306. Available at: <http://www.ncbi.nlm.nih.gov/pubmed/11224867>.

335. Tokuhashi Y, Matsuzaki H, Oda H, et al. A revised scoring system for preoperative evaluation of metastatic spine tumor prognosis. *Spine (Phila Pa 1976)* 2005;30:2186-2191. Available at: <http://www.ncbi.nlm.nih.gov/pubmed/16205345>.

336. van der Linden YM, Dijkstra SP, Vonk EJ, et al. Prediction of survival in patients with metastases in the spinal column: results based on a randomized trial of radiotherapy. *Cancer* 2005;103:320-328. Available at: <http://www.ncbi.nlm.nih.gov/pubmed/15593360>.

337. Bartels RH, Feuth T, van der Maazen R, et al. Development of a model with which to predict the life expectancy of patients with spinal epidural metastasis. *Cancer* 2007;110:2042-2049. Available at: <http://www.ncbi.nlm.nih.gov/pubmed/17853394>.



338. Choi D, Crockard A, Bungler C, et al. Review of metastatic spine tumour classification and indications for surgery: the consensus statement of the Global Spine Tumour Study Group. *Eur Spine J* 2010;19:215-222. Available at: <http://www.ncbi.nlm.nih.gov/pubmed/20039084>.

339. Eleraky M, Papanastassiou I, Vrionis FD. Management of metastatic spine disease. *Curr Opin Support Palliat Care* 2010;4:182-188. Available at: <http://www.ncbi.nlm.nih.gov/pubmed/20671554>.

340. Klimo P, Jr., Thompson CJ, Kestle JR, Schmidt MH. A meta-analysis of surgery versus conventional radiotherapy for the treatment of metastatic spinal epidural disease. *Neuro Oncol* 2005;7:64-76. Available at: <http://www.ncbi.nlm.nih.gov/pubmed/15701283>.

341. Witham TF, Khavkin YA, Gallia GL, et al. Surgery insight: current management of epidural spinal cord compression from metastatic spine disease. *Nat Clin Pract Neurol* 2006;2:87-94; quiz 116. Available at: <http://www.ncbi.nlm.nih.gov/pubmed/16932530>.

342. Patchell RA, Tibbs PA, Regine WF, et al. Direct decompressive surgical resection in the treatment of spinal cord compression caused by metastatic cancer: a randomised trial. *Lancet* 2005;366:643-648. Available at: <http://www.ncbi.nlm.nih.gov/pubmed/16112300>.

343. Patil CG, Lad SP, Santarelli J, Boakye M. National inpatient complications and outcomes after surgery for spinal metastasis from 1993-2002. *Cancer* 2007;110:625-630. Available at: <http://www.ncbi.nlm.nih.gov/pubmed/17577227>.

344. Itshayek E, Yamada J, Bilsky M, et al. Timing of surgery and radiotherapy in the management of metastatic spine disease: a systematic review. *Int J Oncol* 2010;36:533-544. Available at: <http://www.ncbi.nlm.nih.gov/pubmed/20126972>.

345. Maranzano E, Bellavita R, Rossi R, et al. Short-course versus split-course radiotherapy in metastatic spinal cord compression: results of a

phase III, randomized, multicenter trial. *J Clin Oncol* 2005;23:3358-3365. Available at: <http://www.ncbi.nlm.nih.gov/pubmed/15738534>.

346. Gerszten PC, Mendel E, Yamada Y. Radiotherapy and radiosurgery for metastatic spine disease: what are the options, indications, and outcomes? *Spine (Phila Pa 1976)* 2009;34:S78-92. Available at: <http://www.ncbi.nlm.nih.gov/pubmed/19829280>.

347. Gerszten PC, Burton SA, Ozhasoglu C, Welch WC. Radiosurgery for spinal metastases: clinical experience in 500 cases from a single institution. *Spine (Phila Pa 1976)* 2007;32:193-199. Available at: <http://www.ncbi.nlm.nih.gov/pubmed/17224814>.

348. Mendel E, Bourekas E, Gerszten P, Golan JD. Percutaneous techniques in the treatment of spine tumors: what are the diagnostic and therapeutic indications and outcomes? *Spine (Phila Pa 1976)* 2009;34:S93-100. Available at: <http://www.ncbi.nlm.nih.gov/pubmed/19829281>.

349. Sorensen S, Helweg-Larsen S, Mouridsen H, Hansen HH. Effect of high-dose dexamethasone in carcinomatous metastatic spinal cord compression treated with radiotherapy: a randomised trial. *Eur J Cancer* 1994;30A:22-27. Available at: <http://www.ncbi.nlm.nih.gov/pubmed/8142159>.

350. Vecht CJ, Haaxma-Reiche H, van Putten WL, et al. Initial bolus of conventional versus high-dose dexamethasone in metastatic spinal cord compression. *Neurology* 1989;39:1255-1257. Available at: <http://www.ncbi.nlm.nih.gov/pubmed/2771077>.

351. Heimdal K, Hirschberg H, Slettebo H, et al. High incidence of serious side effects of high-dose dexamethasone treatment in patients with epidural spinal cord compression. *J Neurooncol* 1992;12:141-144. Available at: <http://www.ncbi.nlm.nih.gov/pubmed/1560260>.

352. Kwok Y, Regine WF, Patchell RA. Radiation therapy alone for spinal cord compression: time to improve upon a relatively ineffective



National  
Comprehensive  
Cancer  
Network®

## NCCN Guidelines Version 2.2014 Central Nervous System Cancers

[NCCN Guidelines Index](#)  
[CNS Table of Contents](#)  
[Discussion](#)

status quo. J Clin Oncol 2005;23:3308-3310. Available at:  
<http://www.ncbi.nlm.nih.gov/pubmed/15738546>.

353. Rades D, Stalpers LJA, Veninga T, et al. Evaluation of five radiation schedules and prognostic factors for metastatic spinal cord compression. J Clin Oncol 2005;23:3366-3375. Available at:  
<http://www.ncbi.nlm.nih.gov/pubmed/15908648>.